



Original Article



The effects of laparoscopic and laparotomy extensive hysterectomy on the safety of ureterovaginal fistula infection in patients with cervical cancer

Hongge Xu, Hongyan Ding*, Qianqian Ge, Can Shi

Department of Gynaecology, The Affiliated Huaian No.1 People's Hospital of Nanjing Medical University, Huaian, Jiangsu, China

Article Info

Abstract



Article history:

Received: January 03, 2024

Accepted: February 25, 2024

Published: February 29, 2024

Use your device to scan and read the article online



This study aimed to investigate the effect of laparoscopic and laparotomy extensive hysterectomy on the safety of ureterovaginal fistula infection in patients with cervical cancer. For this purpose, a total of 90 patients with early cervical cancer admitted to Affiliated Huaian No.1 People's Hospital of Nanjing Medical University from February 2021 to May 2022 were randomly divided into laparoscopy group and laparotomy group, with 45 cases in each group. The laparoscopy group was treated with laparoscopic extensive hysterectomy, while the laparotomy group was treated with laparotomy extensive hysterectomy. The KPS score, adverse reactions, as well as serum creatinine and urea nitrogen were compared between the two groups. Results showed that after surgery, the KPS score in both groups was higher than before treatment, and the KPS score in laparoscopy group was higher than that in laparotomy group, the difference was statistically significant ($P < 0.05$). After operation, the incidence of adverse reactions in laparotomy group was higher than that in the laparoscopy group, the difference was statistically significant ($P < 0.05$). Moreover, after operation, the levels of creatinine and urea nitrogen in laparoscopy group were significantly lower than those in laparotomy group, the differences were statistically significant ($P < 0.05$). In conclusion, both laparoscopic and laparotomy extensive hysterectomy may lead to ureterovaginal fistula infection in patients with cervical cancer. However, compared with laparotomy extensive hysterectomy, laparoscopic extensive hysterectomy had higher safety and significantly improved the quality of life of patients, which was worthy of popularization and application in clinical practice.

Keywords: Cervical cancer, Laparoscopic extensive hysterectomy, Laparotomy extensive hysterectomy, Ureterovaginal fistula

1. Introduction

Cervical cancer is the third most common gynecological cancer and is usually secondary to human papillomavirus infection, with more than half a million women diagnosed each year [1]. With the continuous improvement of medical level and the gradual improvement of tumor diagnosis technology in recent years, more and more patients with early cervical cancer have been detected clinically. Timely and effective treatment for patients with this type of cervical cancer can significantly improve the survival of patients [2]. So far, surgery is still recognized worldwide as the most effective treatment for early cervical cancer [3]. Due to the great impact on the physical and mental health and quality of life in patients with cervical cancer, traditional laparotomy extensive hysterectomy has been mainly used in clinical treatment of early cervical cancer in the past, but this treatment method will cause great trauma to patients, may increase the incidence of postoperative complications, which is not conducive to postoperative recovery of patients [4]. Postoperative ureteral injuries, especially ureterovaginal fistula, is one of the more serious complications, the incidence of the fistula is about

1% ~ 2%, often requiring second surgical repair [5]. Ureterovaginal fistula usually occurs several days to weeks after gynecological surgery. Before the formation of a fistula, symptoms such as waist or lower abdomen pain and fever may occur due to urinary extravasation. Once the fistula is formed, it manifests as persistent vaginal urine leakage accompanied by normal urination, followed by vulvar eczema, urinary tract infection, and in severe cases may lead to renal impairment [6]. Therefore, it is particularly important to protect the ureter effectively, which is also an important way to ensure the surgical effect and improve the prognosis. Laparoscopic extensive hysterectomy is a new type of minimally invasive surgery, which has been gradually popularized in clinical application in recent years [7]. In this paper, the effect of laparoscopic extensive hysterectomy and laparotomy extensive hysterectomy on the safety of ureterovaginal fistula infection in patients with cervical cancer was compared.

2. Materials and methods

2.1. General clinical data

A total of 90 patients with early cervical cancer admit-

* Corresponding author.

E-mail address: hongyandingdd@outlook.com (H. Ding).

Doi: <http://dx.doi.org/10.14715/cmb/2024.70.2.39>

ted to Affiliated Huaian No.1 People's Hospital of Nanjing Medical University from February 2021 to May 2022 were chosen. All patients were female, aged 18-65 years, with an average age of (46.5 ± 5.2) years, and were randomly divided into 45 patients in each group. There was no significant difference between the two groups ($P > 0.05$), indicating comparability.

2.1.1. Inclusion criteria

(1) After examination, all of patients were consistent with early cervical cancer and met the diagnostic criteria; (2) None of them received any relevant anti-tumor therapy before surgery; (3) No symptoms such as frequent urination, painful urination and difficulty in passing urine before operation; (4) Complete clinical medical records.

2.1.2. Exclusion criteria

(1) Patients with other malignant tumors; (2) Patients with severe internal and surgical diseases; (3) People with communication disorders or mental diseases; (4) Patients with poor treatment compliance; (5) Patients with previous surgical history. This study was approved by the Ethics Committee of our school, and the informed consent was signed before treatment.

2.2. Methods

In the laparotomy group, laparotomy extensive hysterectomy was performed. The patients were placed in a supine position and applied with conventional disinfection cloth, and then inserted with a double-cavity ureteral catheter. A longitudinal incision of about 20 cm was made around the umbilical on the left side of the midline of the lower abdomen. Each layer of tissue was cut into the abdominal cavity successively, and the abdominal cavity and pelvic cavity were explored. The round ligament was separated first, and then the inherent ovarian ligament was forceps, and the broad ligament was opened to dissociate the ureter. The common iliac, inguinal, internal iliac and external iliac lymph node groups were cleared successively. The vesicoperitoneum was refolded and separated for bladder dissociation. The uterine rectum reflexed peritoneum was cut and the vagino-rectal space was separated. The left and right uterine arteries were dissociated and cut off, the lateral rectal fossa was clamped and the sacral ligament was separated. The vesicular-lateral space was separated, the vesicular-vaginal ligament and the main ligament were cut off. The vagina was cut and sutured, the peritoneum was sutured, and the abdomen was closed after flushing and hemostasis. In the laparoscopy group, laparoscopic extensive hysterectomy was performed. Patients were placed into the position of bladder lithotomy with head low hip high, treated with disinfection cloth, and then placed with the double-cavity ureteral catheter. Next, about 1 cm transverse incision was made on the 4 cm above the umbilical cord, and 10 mm trocar was placed into the abdominal cavity for CO₂ injection to form pneumoperitoneum, and the intra-abdominal pressure was maintained at about 12 mm Hg. Afterwards, the laparoscopy was placed, and the lift device was placed into the uterine cavity. The operating forceps were placed into the puncture hole, and the peritoneum was cut open to expose the ovarian arteries and veins, iliac vessels and fallopian tubes. The deep inguinal lymph node group and the anterior lymph nodes outside the iliac were electrocoagulated successively.

Then the middle lymph nodes were dissected, and finally, the posterior lymph nodes were electrocoagulated. The left and right sides of the rectal space and the uterine and rectal space were separated successively. The vaginal ligament and the sacral ligament were forceps, the vagina was cut circumferentially, and the uterus, upper vaginal segment, lymph nodes and adipose tissue were removed from the vagina. The stump of the vagina was sutured and placed in a pelvic drainage tube. The pelvic cavity was rinsed and stopped bleeding. After no bleeding, the laparoscope was evacuated, the trocar was pulled out, and the puncture holes were sutured successively.

2.3. Observation indicators

(1) KPS score was used to evaluate the quality of life of patients, and the higher THE KPS score, the better the quality of life of patients.

(2) The occurrence of adverse reactions. The incidence of fever, abdominal pain, lumbago, vomiting and vaginal urine leakage in 2 groups were observed.

(3) Comparison of serum creatinine and urea nitrogen. One week after the operation, the serum was extracted and centrifuged at 5000 g. A serum creatinine detection kit and urea nitrogen detection kit were used to detect serum creatinine and urea nitrogen levels, respectively.

2.4. Statistical analysis

SPSS 20.0 software was used to analyze and process the data. χ^2 test and T test were used to analyze the similar count data and measurement data, respectively. $P < 0.05$ indicated significant difference.

3. Results

3.1. Comparison of KPS score between the two groups before and after treatment

As shown in Figure 1, there was no significant difference in KPS score between the two groups before surgery ($P > 0.05$), but the KPS score of the two groups after surgery was higher than those before treatment, and the KPS score of the laparoscopy group was higher than that of the laparotomy group, the difference was statistically significant ($P < 0.05$).

3.2. Comparison of adverse reactions between the two groups

As indicated in Table 1, the incidence of adverse reactions in the laparoscopic group was lower than that in the laparotomy group one week after surgery, the difference was statistically significant ($P < 0.05$).

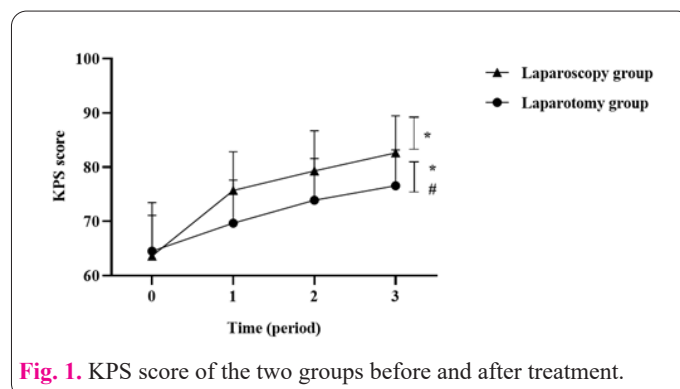
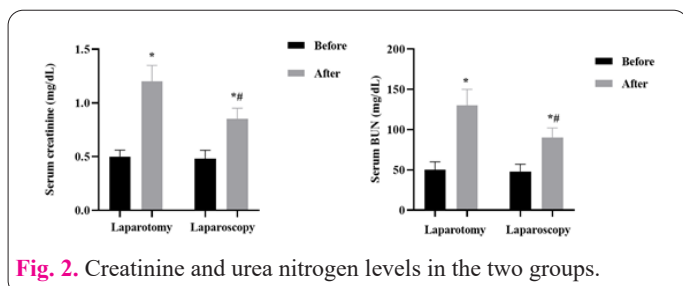


Fig. 1. KPS score of the two groups before and after treatment.

Table 1. Comparison of adverse reactions between the two groups.

Groups	Fever	Abdominal pain	Lumbago	Vomiting	Vaginal urine leakage	Incidence of adverse reactions
Laparoscopy group	1(2.50)	2(5.00)	2(5.00)	1(2.50)	1(2.50)	17.50
Laparotomy group	3(7.50)	2(5.00)	4(10.00)	0(0.00)	2(5.00)	27.50
X ²				11.325		
P				<0.05		

**Fig. 2.** Creatinine and urea nitrogen levels in the two groups.

3.3. Comparison of creatinine and urea nitrogen in the serum between the two groups

As demonstrated in Figure 2, before surgery, creatinine and urea nitrogen levels were compared between the two groups, and there was no statistical significance ($P>0.05$). One week after the operation, the levels of creatinine and urea nitrogen in laparoscopy group were significantly lower than those in laparotomy group, the differences were statistically significant ($P<0.05$).

4. Discussion

With the development of medical technology and the improvement of people's awareness of health, great attention has been paid to early diagnosis and treatment of cervical cancer. At present, the incidence of cervical cancer is still high in China; however, early cases treated with surgery can obtain good results. Through surgery, lymph node involvement can be determined. Compared with radiotherapy, it has less damage to the genitourinary tract function, reduces the impact on the quality of life, and also leaves opportunities for follow-up radiotherapy and chemotherapy when necessary [8]. In the past, laparotomy was mainly used, but it would cause great trauma to patients, and the risk of postoperative complications is high, which is not conducive to the prognosis of patients [9]. Traditional laparotomy extensive hysterectomy will damage the pelvic autonomic nerve of patients, further lead to postoperative complications such as bladder, rectum and sexual dysfunction, and seriously affect the postoperative quality of life of patients [10].

With the continuous popularization of minimally invasive concepts and the gradual development of minimally invasive technology, laparoscopic extensive hysterectomy has gradually become the standard treatment for early cervical cancer [11]. Up to now, more and more literature has reported that laparoscopic radical hysterectomy for uterine cancer can achieve or even better radical effect than laparotomy hysterectomy and has obvious advantages of minimally invasive surgery. Laparoscopic radical hysterectomy for uterine cancer mainly includes extensive hysterectomy and lymphatic dissection. As reported previously, laparoscopic hysterectomy has been proven to be reliable and safe compared with laparotomy surgery, which provides a good prospect for minimally invasive surgery in the treat-

ment of cervical cancer [12]. However, in recent years, the risk of ureterovaginal fistula infection in cervical cancer patients with laparoscopic and laparotomy extensive hysterectomy has been controversial, and has been highly regarded by the industry [13, 14]. In this study, we compared the effects of laparoscopic and laparotomy extensive hysterectomy on the safety of ureterovaginal fistula infection in patients with cervical cancer. The results showed that the KPS score of patients in the laparoscopy group was significantly higher than that in the laparotomy group, suggesting that laparoscopic extensive hysterectomy for the treatment of patients with early cervical cancer is of great significance in alleviating the pain caused by adverse reactions and improving the quality of life of patients. Moreover, Creatinine and urea nitrogen are the main indicators of renal function [15]. Changes in creatinine and urea nitrogen levels are associated with ureteral injuries, including ureterovaginal fistula [16, 17]. Therefore, the present study further examined the effects of laparoscopic and laparotomy extensive hysterectomy on creatinine and urea nitrogen levels in patients. The results showed that after one week of operation, the levels of creatinine and urea nitrogen in the laparoscopy group were significantly lower than those in the laparotomy group, indicating that laparoscopic extensive hysterectomy may be safer than laparotomy extensive hysterectomy for patients with early cervical cancer infected with ureteral vaginal fistula.

In conclusion, both laparoscopic and laparotomy extensive hysterectomy have the risk for patients with cervical cancer to infect with ureterovaginal fistula, but all indicators of laparoscopic extensive hysterectomy are better than laparotomy extensive hysterectomy, which is worthy of clinical application and promotion. Therefore, whether laparotomy or laparoscopic cervical cancer surgery, it is very important to emphasize that membrane-based protective operation, which means the protection of ureteral outer membrane integrity. The safeguard procedures are presented in the following aspects: avoiding injury, protecting the blood vessels of the ureter and nutrition, prevention of ureteral tumor cell invasion and preventing the spread of infection involving the ureter.

Conflicts of interest

None.

Data availability statement

Original data included in this article can be obtained from the corresponding author under reasonable requests.

Funding statement

This work was supported by the Science and Technology Development Fund project of Nanjing Medical University (NMUB20210138).

References

1. Buskwofie A, David-West G, Clare CA (2020) A review of cervical cancer: incidence and disparities. *J Natl Med Assoc* 112(2):229–232. doi: 10.1016/j.jnma.2020.03.002
2. Sharma S, Deep A, Sharma AK (2020) Current treatment for cervical cancer: an update. *Anticancer Agents Med Chem* 20(15):1768–1779. doi: 10.2174/1871520620666200224093301
3. Poddar P, Maheshwari A (2021) Surgery for cervical cancer: consensus & controversies. *Indian J Med Res* 154(2):284–292. doi: 10.4103/ijmr.IJMR_4240_20
4. Matsuo K, Chen L, Mandelbaum RS, Melamed A, Roman LD, Wright JD (2019) Trachelectomy for reproductive-aged women with early-stage cervical cancer: minimally invasive surgery versus laparotomy. *Am J Obstet Gynecol* 220(5):469.e1-469.e13. doi: 10.1016/j.ajog.2019.02.038
5. Chen YB, Wolff BJ, Kenton KS, Mueller ER (2019) Approach to ureterovaginal fistula: examining 13 years of experience. *Female Pelvic Med Reconstr Surg* 25(2):e7–e11. doi: 10.1097/SPV.0000000000000690
6. Lo TS, Jaili SB, Ibrahim R, Kao CC, Uy-Patrimonio MC (2018) Ureterovaginal fistula: a complication of a vaginal foreign body. *Taiwan J Obstet Gynecol* 57(1):150–152. doi: 10.1016/j.tjog.2017.12.026
7. Bogani G, Leone Roberti Maggiore U, Rossetti D, Ditto A, Martinelli F, Chiappa V, et al (2019) Advances in laparoscopic surgery for cervical cancer. *Crit Rev Oncol Hematol* 143:76–80. doi: 10.1016/j.critrevonc.2019.07.021
8. Uwins C, Patel H, Prakash Bhandoria G, Butler-Manuel S, Tailor A, Ellis P, Chatterjee J (2021) Laparoscopic and robotic surgery for endometrial and cervical cancer. *Clin Oncol (R Coll Radiol)* 33(9):e372–e382. doi: 10.1016/j.clon.2021.05.001
9. Basaran D, Leitao MM Jr (2021) The landmark series: minimally invasive surgery for cervical cancer. *Ann Surg Oncol* 28(1):204–211. doi: 10.1245/s10434-020-09265-0
10. Undurraga M, Loubeyre P, Dubuisson JB, Schneider D, Petignat P (2010) Early-stage cervical cancer: is surgery better than radiotherapy? *Expert Rev Anticancer Ther* 10(3):451–460. doi: 10.1586/era.09.192
11. Carter J (2019) Safety of laparoscopy in cervical cancer. *Aust N Z J Obstet Gynaecol* 59(3):E9. doi: 10.1111/ajo.12934
12. Tjalma WAA (2019) Surgical management of cervical cancer by laparoscopy or laparotomy? *Gynecol Oncol Rep* 27:5. doi: 10.1016/j.gore.2018.11.002
13. Liang C, Liu P, Cui Z, Liang Z, Bin X, Lang J, Chen C (2020) Effect of laparoscopic versus abdominal radical hysterectomy on major surgical complications in women with stage IA-IIIB cervical cancer in China, 2004-2015. *Gynecol Oncol* 156(1):115–123. doi: 10.1016/j.ygyno.2019.10.032
14. Uccella S, Laterza R, Ciravolo G, Volpi E, Franchi M, Zefiro F, et al (2007) A comparison of urinary complications following total laparoscopic radical hysterectomy and laparoscopic pelvic lymphadenectomy to open abdominal surgery. *Gynecol Oncol* 107(1 Suppl 1):S147–S149. doi: 10.1016/j.ygyno.2007.07.027
15. Narváez A, Guiteras R, Sola A, Manonelles A, Morote J, Torras J, et al (2019) siRNA-silencing of CD40 attenuates unilateral ureteral obstruction-induced kidney injury in mice. *PLoS One* 14(4):e0215232. doi: 10.1371/journal.pone.0215232
16. von Eye Corleta H, Moretto M, D'Avila AM, Berger M (2008) Immediate ureterovaginal fistula secondary to oocyte retrieval—a case report. *Fertil Steril* 90(5):2006.e1-3. doi: 10.1016/j.fertnstert.2008.03.005
17. Chang OH, Stokes MJ, Chalamanda C, Wilkinson J, Pope RJ (2020) Baseline renal function and renal ultrasound findings in patients with obstetric fistulas (RENFRU): a prospective cohort study. *BJOG* 127(7):897–904. doi: 10.1111/1471-0528.16106