

The effect of *Cornus mas* extract on nicotine-induced oxidative stress and intratesticular damage in male rats

Ünal Öztekin^{1*}, Mehmet Caniklioğlu², Şükrü Ateş³, Züleyha Doğanıyıt⁴, Emin Kaymak⁴, Fatih Fırat⁵,
Ayşe Yeşim Göçmen⁶, Fatih Ataç⁷, Rukset Attar⁸, Seher Yılmaz³

¹Kayseri System Hospital, Department of Urology, Kayseri, Turkey

²Yozgat Bozok University, Faculty of Medicine, Department of Urology, Yozgat, Turkey

³Yozgat Bozok University, Faculty of Medicine, Department of Anatomy, Yozgat, Turkey

⁴Yozgat Bozok University, Faculty of Medicine, Department of Histology and Embryology, Yozgat, Turkey

⁵Tokat State Hospital, Department of Urology, Tokat, Turkey

⁶Yozgat Bozok University, Faculty of Medicine, Department of Biochemistry, Yozgat, Turkey.

⁷Batman Zilan Private Hospital, Department of Urology, Batman, Turkey

⁸Department of Obstetrics and Gynecology, Yeditepe University, Turkey

ARTICLE INFO

Original paper

Article history:

Received: September 23, 2023

Accepted: November 12, 2023

Published: November 15, 2023

Keywords:

Apoptosis, *Cornus mas*, factor VIII, nicotine, oxidative stress

ABSTRACT

The role of oxidative stress in disease pathogenesis has been extensively investigated. Researchers have gathered sufficient evidence related to oxidative stress-mediated intratesticular damage. The aim of this was study to evaluate the effects of *Cornus Mas* (CM) extract on intratesticular changes in rats exposed to nicotine. Thirty Wistar albino rats were divided into four groups. The groups and the administered agents for 35 days were as follows; Control group (n=6): 0.9% saline, intraperitoneally; Nicotine group (n=7): 4 mg/kg nicotine, subcutaneous; CM group (n=7): 1000 mg/kg CM extract in 0.5 ml saline, via gavage; Nicotine + CM Group (n=8): 4 mg/kg Nicotine, subcutaneous + 1000 mg/kg CM extract via gavage. One rat each from the groups Nicotine and CM died. In spermatogenetic and histopathological examination, significant positive changes were detected in nicotine + CM group regarding seminal parameters, apoptotic cells, Factor VIII and Johnsen score as compared to nicotine group. Oxidative stress markers were higher in nicotine group as compared to the control group. OSI and MDA levels were found to be reduced in nicotine + CM group than nicotine group. Nicotine induced a significant increase in TNF- α and IL-6 levels compared to the control group; however, CM effectively counteracted this increase. We have shown that nicotine increases testicular damage, causes apoptosis of testicular cells and adversely affects spermatogenesis by increasing inflammation. We concluded that CM extract exerted beneficial effects on spermatogenesis and minimized testicular parenchymal damage, apoptosis and angiogenesis. Rapidly increasing understanding of the complexity of oxidative stress in intratesticular is the key to unlocking the potential of ROS-targeting therapies.

Doi: <http://dx.doi.org/10.14715/cmb/2023.69.11.37>

Copyright: © 2023 by the C.M.B. Association. All rights reserved. 

Introduction

In recent years, nutrition has been emphasized for its preventative role in many diseases. Many of the natural bioactive compounds and dietary compounds are therapeutically effective agents with having unique ability to modulate the expression of pro-inflammatory factors and inflammasomes. One of these products is an extract of *Cornus Mas* (CM) fruit, which is a part of the Cornaceae family and is commonly known as cornelian cherry. It has high nutritional value and therapeutic properties and grows in Europe and Asia (1). This plant contains anthocyanin, ascorbic acid, flavonoids, and polyphenol antioxidant components that have been reported to have anti-inflammatory and antioxidative properties (2). Moreover, it has been reported to have antidiabetic, anticarcinogenic, antimicrobial, and hypolipidemic effects (3).

Nicotine is an oxidative agent that can cause damage to tissues. It is a primary component of cigarettes and causes addiction as well as serious health problems. The mucosa

of the respiratory tract rapidly absorbs nicotine causing a swift increase in the bloodstream and subsequently in the brain (4). Nicotine has the ability to trigger oxidative stress by increasing the levels of ROS. Therefore, nicotine-mediated oxidative stress potently enhanced pathogenesis (5). To evaluate oxidative stress status, Total anti-oxidative status (TAS), total oxidative status (TOS) and malondialdehyde (MDA) levels are checked. In addition, Superoxide dismutase (SOD), catalase (CAT), glutathione peroxidase (GSH-PX) activities, glutathione (GSH) and glutathione disulfide (GSSG) levels also provide information about the oxidative stress situation. In addition to its oxidative effects, nicotine triggers the activation of inflammatory mediators (6,7). It can damage the blood testis barrier at the testicular level causing intratesticular tissue damage, increased apoptosis, and infertility with negative effects on spermatogenesis (8-11).

Infertility is the failure to become pregnant despite regular unprotected sexual intercourse for 12 months or longer. This disease originates from the male or female

* Corresponding author. Email: dr_unal@hotmail.com

reproductive system (12). Infertility is a common health problem that can affect couples both socially and psychologically and is seen in 15% of the population. Approximately 50% of infertility causes are due to male partners and in 10% of these cases, the main reason for infertility is the low sperm count and bad sperm quality (13). Lifestyle, diet, environmental factors, drugs, and chronic toxicity exposure can adversely affect spermatogenesis and cause infertility (14). Nicotine is a toxic substance and its toxic effects have been extensively documented (15). It is known that the toxic effects of widely consumed Nicotine cause infertility and research in this field is increasing. Among these studies, animal experiments targeting nicotine-induced testicular damage are of great importance (16-18).

In this study, our goal was to evaluate the effects of CM extract on intratesticular histological, apoptotic, biochemical, and spermatogenic changes that may occur in rats exposed to nicotine.

Materials and Methods

Experimental design and laboratory animals groups

The study was conducted by following “the Guide for Care and Use of Laboratory Animals of the National Research Council” and “1986 Strasbourg Universal Declaration on Animal Welfare”. Permission (2019 HADYEK-30) from the local ethics committee was taken for the study. Thirty Wistar albino rats which weighed 220-250 g were included in the study and they were divided into four groups randomly. The rats were left for the adaption to the laboratory one week before the beginning of the study.

It is provided for them to easily consume commercial rat chow and fresh water. The cages were exposed to fresh air. They left in a room which has an adjustable room temperature system and in which the temperature levels were adjusted to 20-23 °C (68-73 °F). According to the life cycle of rats, the sleep/awareness periods were adjusted to 12 hours each. The administration lasted for 35 days. During the study, one rat each from groups Nicotine and *Cornus mas*, died. Thus, blood and tissue samples of 28 rats were evaluated.

Experimental groups

The control group (n=6) received 0.9% saline subcutaneously once a day. The Nicotine group (n=7) received 4 mg/kg subcutaneous nicotine injections once a day (19). *Cornus Mas* group (n=7) was administered 1000 mg/kg *Cornus mas* extract in 0.5 ml saline was given via gavage (20). Nicotine + *Cornus Mas* group (n=8) was treated with subcutaneous 4 mg/kg Nicotine + 1000 mg/kg *Cornus mas* extract via gavage.

Nicotine and *Cornus mas* extract preparation

Nicotine hydrogen tartrate (95% nicotine) diluted with saline was used in the study (Sigma, USA). After coring, *Cornus mas* was left for sun drying and it was waited to obtain dust. Dust form preserved in a box at 8 °C. The extraction process started with dispersing *Cornus Mas* dust in ethanol: saline (7:3) solution at 25 ± 2 °C. The solvent evaporated by using a rotary vacuum evaporator at 50 °C. The extract was dried and frozen. Then, it was preserved in a Vacuum Desiccator (21-23).

Collection of samples

On the 35th day of the study, the rats were anesthetized again with Xylazine/Ketamine (75 mg/kg)/(10 mg/kg). All rats were sacrificed by decapitation in accordance with the procedure described by the Institutional Animal Ethics Committee. After that blood samples of 8-10 ml were taken with intracardiac puncture. All tests were resected and put into separate boxes filled with 10% formaldehyde. The specimens were delivered to a histologic research laboratory.

Sperm collection and analysis

Cauda epididymis samples were taken from each rat for sperm analysis. Samples were used for the dispersal of spermatozoa into this solution by rinsing the tissues in a saline solution of 2 ml and at 37 °C. They were counted by Makler counting chamber with magnifications of 10X. The sperm count was recorded as 10⁶ cells/mL. Motile and non-motile sperm percentages were recorded. On a slide, a 5% eosin Y staining protocol was performed in 10 µl of sperm solution mixed with saline in order to get the rate of sperm viability. Approximately 200 spermatozoas from 10 areas of each slide were inspected with magnifications of 400X. White spermatozoas were recorded and sperm viability was calculated.

Biochemical evaluation

Blood samples were centrifuged (3,000 × g, 10 min) at 4°C. Serum samples were left at -80°C until biochemical parameters were analyzed. Tissue samples were collected and rinsed with ice-cold buffer (0.1 M KH₂PO₄, 0.1 M KCl) to remove as much blood as possible. The whole tissues were homogenized in cold potassium phosphate buffer (50 mM, pH 7.4). Tissue protein levels were measured after adequate dilutions had been obtained in the supernatants. The protein content of the samples was measured by the method of Lowry et al. using bovine serum albumin as standard (24).

Antioxidant indices and cytokines measurements

Superoxide dismutase (SOD), catalase (CAT) and glutathione peroxidase (GSH-PX) activities, glutathione (GSH) and glutathione disulfide (GSSG) levels were measured in blood and tissue samples by the modified methods of Ozturk et al. (25). Colorimetric kits were used to measure the levels of total anti-oxidative status (TAS), total oxidative status (TOS) (Relassay, Gaziantep, Turkey), and malondialdehyde (MDA) (Cayman Chemical, MI, USA). Each sample was analyzed in duplicate. GSH content was calculated using the formula $GSH = T-GSH - (2 \times GSSG)$. The levels of GSH were calculated by the formula: $GSH = GSht - 2 \times GSSG$. The results of GSht, GSH, and GSSG were normalized to the total protein content and were mentioned as nmol of GSH or GSSG per mg of protein (nmol GSH/mg protein or nmol GSSG/mg protein). The oxidative stress index (OSI) value was calculated using the formula: $OSI = (TOS (\mu\text{mol H}_2\text{O}_2 \text{ equiv./l}) / TAS (\mu\text{mol Trolox equiv./l}) \times 100)$.

Commercial enzyme-linked immunosorbent assay (ELISA) kits were used to measure the serum levels of cytokines (TNF-α, IL-6 (Elabscience, MD, USA)) on a microplate reader (Spectrostar Nano, BMG, Labtech, Allmendgrün, Ortenberg, Germany).

Histological procedure

Fixation of the testis tissues was done with 10% formaldehyde solution. Then the tissues were immersed in a series of alcohol solutions of increasing concentrations (50%, 70%, 80%, 96%, 100%) until they became dehydrated. The clearing process was performed by using xylene. The tissues were embedded into paraffin wax. After the wax infiltrated into the tissues 5-6 μ m sections were sliced from paraffin blocks. These sections were stained with Hematoxylin-Eosin and mounted with Entellan® (Entellan new, Merck®). When the slides were ready, they were inspected under the Olympus BX53 microscope (26). Histopathological findings were evaluated according to Johnsen testicular biopsy score (JTBS) (27).

Immunohistochemical analyses

Factor VIII (Bioss, BS10048R, USA) immunoreactivity in groups 1 and 2 rats was measured by using an avidin-biotin-peroxidase complex. In this method, citrate buffer was used in order to retrieve epitopes after deparaffinization of 5 μ m sections (pH: 6.0). Then, the slides were incubated in 3% hydrogen peroxide solution which was diluted with methanol, in order to block endogenous peroxidase reaction. The slides were dipped into Ultra V Block® (Thermo Fischer Scientific, TA-125-UB, UK) for the reduction of nonspecific background staining. Then, the slides were incubated with primary antibodies at 4 °C for a night. The next day, they were incubated with biotinylated secondary antibodies, combined with streptavidin-HRP, and DAB chromogens (Thermo Fischer Scientific, TA-125-HD, UK). Then, Gill's hematoxylin method was used for counterstaining. The sections were immersed in an alcohol solution series in increasing concentrations for tissue dehydration and were mounted with Entellan® (Entellan New, Merck®). The slides were inspected with an Olympus BX53 microscope (26). Ten different areas were inspected for each slide. The immunoreactivity levels were evaluated with ImageJ software.

TUNEL method

Apoptotic cells were determined in the sections using the In Situ Cell Detection Apoptosis Fluorescein Kit (Roche®). The staining process was performed in accordance with the kit's manual. Five micrometers of testicular tissue sections were rinsed in PBS (2 x 5 minutes) after deparaffinization followed by rehydration. Then, for antibody retrieval protocol, the slides were placed into vessels that contained sodium citrate buffer (10mM Sodium Citrate, 0.05% Tween 20, pH 6.0) and transferred into a microwave (350W for 5 minutes). When the boiling was seen, they were left to cool at room temperature. When cooling was finished, first, they were rinsed in PBS again and then, they were incubated within the TUNEL reaction mixture in an incubator adjusted to 37 °C for 60 minutes. Rinsing in PBS was repeated and counterstaining with 4',6-diamino-2-phenylindoline was performed. The slides were mounted with Glycerol solution and inspected under an Olympus BX53 microscope with 20X magnification (28, 29). Apoptotic cells in 50 different areas were counted for the apoptotic index.

Statistical analysis

IBM SPSS Statistics for Windows, v25.0 (IBM Corp. Released 2017. Armonk, NY) was used for statistical ana-

lyses. The results were given in mean \pm standard deviation (SD). A one-way ANOVA test was used for the comparison between the three groups. Tukey's test was used as post-Hoc test. The statistical value of $p < 0.05$ was considered as significant.

Results

Sperm analysis results

The effects of *Cornus mas* extract on seminal parameters of nicotine given rats were given in Figure 1. Accordingly, all parameters were statistically lower in the nicotine group ($p < 0.001$). Those parameters were lower in the nicotine + Cornus Mas group than control and Cornus Mas groups. However, it was higher than the nicotine group ($p < 0.001$).

Biochemical results

The statistical expressions of markers of oxidative stress and antioxidants in addition to biochemical analysis results and graphics were given in Figure 2. MDA, TOS, OSI and antioxidant enzyme levels (SOD, GPx) were significantly higher in the nicotine group than in the control group ($p < 0.001$). OSI and MDA levels were reduced in the nicotine + Cornus Mas group than nicotine group ($p < 0.001$). TOS level was reduced in the same way; however, this decrease was not statistically significant. TAS and GSH levels in the nicotine group were significantly lower than in the control group ($p < 0.05$). TAS was statistically significantly lower in the nicotine + Cornus Mas group than in the control group and it was higher than the nicotine group.

The results of proinflammatory cytokines which are tumor necrosis factor- α (TNF α) and interleukin-6 (IL-6), are given in Figure 3. When compared to the control group, both cytokines were higher in the nicotine group, while it was lower in the nicotine + Cornus Mas group ($p < 0.001$). There was no statistical significance between the groups control, Cornus Mas and nicotine + Cornus Mas.

Histological, immunohistochemical and apoptotic results

Histopathological results

According to JTBS, there was a significant tubular damage in the nicotine group than control group (Table 1, Figure 4). The tubular damage was reduced significantly in the nicotine + Cornus Mas group.

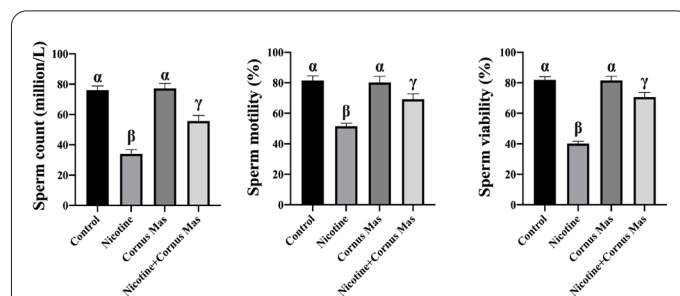


Figure 1. The effects of nicotine and Cornus Mas extract on sperm count, motility, and viability. Data are expressed as mean+std. There is a statistically significant difference between groups that do not share a common symbols (α , β , γ), $p < 0.05$.

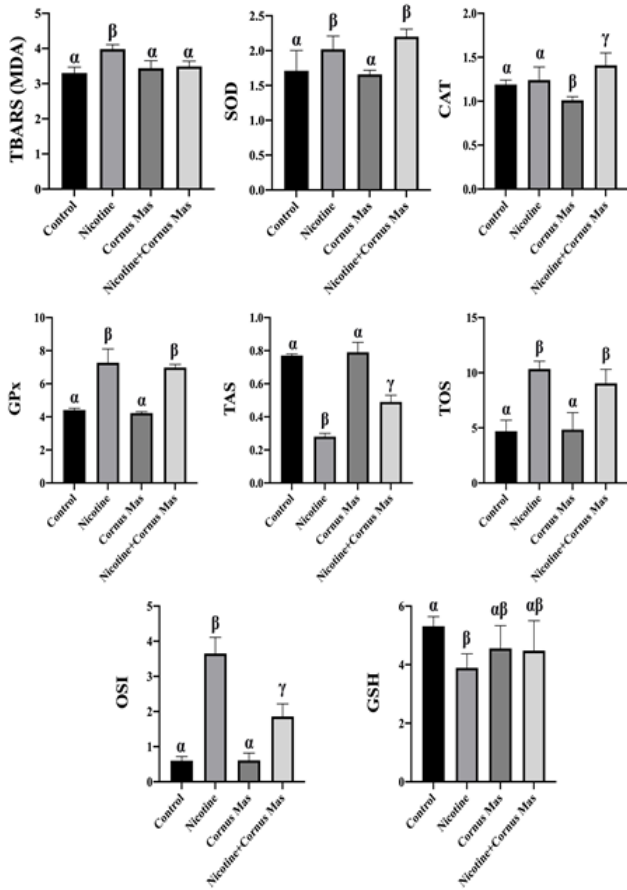


Figure 2. The distribution of biochemical analyses results of oxidative stress and antioxidant markers by groups. TBARS (MDA): Thio-barbituric Acid Reactive Substances (Malondialdehyde), SOD: Superoxide Dismutase, CAT: Catalase, GPx: Glutathione Peroxidase, TAS: Total Anti-oxidative Status, TOS: Total Oxidative Status, OSI: Oxidative Stress Index, GSH: Glutathione. Data are expressed as mean+std. There is a statistically significant difference between groups that do not share a common symbols (α , β , γ), $p<0.05$.

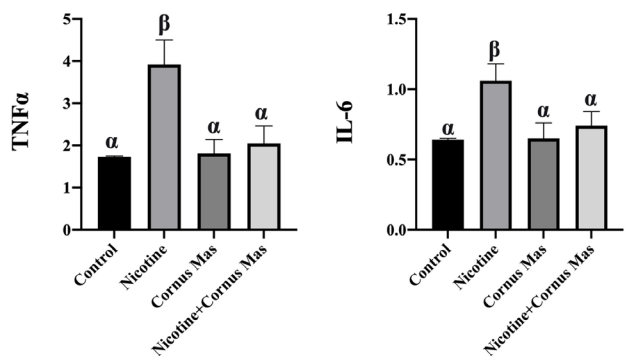


Figure 3. The results of proinflammatory cytokine analyses by groups. TNFα: Tumour Necrosis Factor-α, IL-6: Interleukin-6. Data are expressed as mean+std. There is a statistically significant difference between groups that do not share a common symbols (α , β), $p<0.05$.

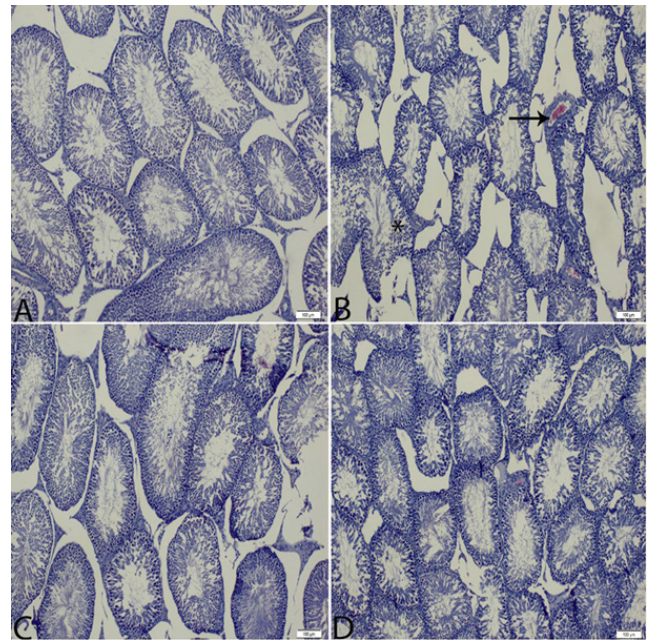


Figure 4. (A) Control group, (B) Nicotine group, (C) Cornus mas group, (D) Nicotine+Cornus mas group. Black arrow indicates hemorrhage, and asterisk indicates the deterioration in spermatogenic series (X100).

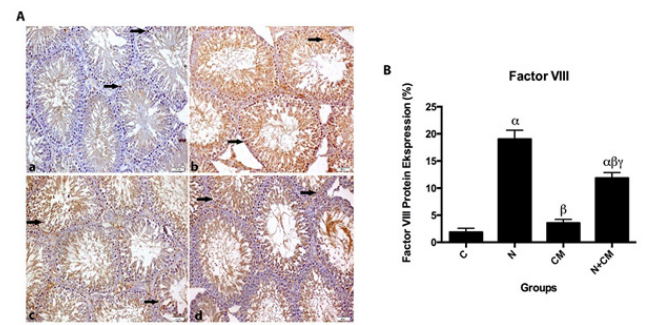


Figure 5. (A) Factor VIII immune stainings in the subjects of control group (a), nicotine (b) Cornus mas (c) and nicotine + Cornus mas (d) (Dark arrow indicates the immune reactive areas). (B) Histopathological scores are given in histogram. Control group (C); $\alpha p<0.05$ Nicotine group (N); $\beta p<0.05$ Cornus Mas group (CM); $\gamma p<0.05$ Nicotine + Cornus mas group (N+CM) (X200).

Results of immunohistochemical evaluation

Factor VIII expressions in the nicotine group were statistically significantly higher than in the other groups ($p<0.05$) (Figure 5). However, Cornus Mas and control groups did not show any significant difference between each other ($p>0.05$). Factor VIII expressions in the nicotine+ Cornus Mas group were statistically significantly higher than in the control group, however, it was lower than the nicotine group ($p<0.05$).

TUNEL reaction results

Apoptotic cell counts were statistically significantly different between the groups ($p<0.001$) (Table 2, Figure

Table 1. Johnsen testicular biopsy score results.

Groups	Control	Nicotine	Cornus mas	Nicotine+Cornus mas	p
JTBS	9.40±0.66 ^α	7.12±1.00 ^β	9.28±1.48 ^α	8.93±0.92 ^α	<0.001

Data is shown as mean± standard deviation. Mean values within a row not sharing common superscript symbols (α , β) were significantly different, $p<0.05$.

Table 2. TUNEL results.

Groups	Control	Nicotine	Cornus mas	Nicotine+Cornus mas	<i>p</i>
TUNEL Positive cell	0.32±0.81 ^α	1.62±2.24 ^β	0.54±0.90 ^α	0.58±0.94 ^α	<0.001

Data is shown as mean± standard deviation. Mean values within a row not sharing common superscript symbols (α , β) were significantly different, $p < 0.05$.

6). It was higher in the nicotine group than in the control group. Also, there was a statistically significantly lower apoptotic cell count in the nicotine + Cornus Mas group than in the nicotine group ($p < 0.05$).

Discussion

Oxidative stress-modulating natural products and dietary agents have gained significant appreciation. The effects of fruits with high antioxidant properties are in the spotlight of current research. CM, which is one of these fruits, is thought to have protective effects against cellular oxidation reactions via antioxidative mechanisms. Flavonoids that contain phenolics contribute to the antioxidative properties of fruits and are found in abundance in CM. Associated with its antioxidant properties, CM is thought to have antibacterial, anti-inflammatory, anticarcinogenic, anti-allergic, antiviral, antithrombotic, vasodilatory and hepatoprotective effects (30).

Impaired sperm quality as a result of smoking and nicotine exposure is one of the important causes of male infertility. Studies have emphasized that the destructive effect of nicotine is due to oxidative stress. A comprehensive study has reported that testicular oxidative stress causes a significant decrease in the number of germ cells and impairs various stages of spermatogenesis (31). In another study, nicotine was reported to cause oxidative stress-mediated DNA fragmentation and decrease the percentage of progressive motile sperm and viable spermatozoa (32). The damage in question also triggers apoptotic mechanisms in Leydig cells, Sertoli cells, and tubule epithelium (33, 34). This cellular damage caused by the increase of intratesticular reactive oxygen species (ROS) has negative effects on the reproductive hormones, thus in turn, impairing spermatogenesis (31, 35). Therefore, in our study, we used nicotine to create a testicular oxidative stress model in rats. According to our results, intratesticular damage and apoptotic cell count were significantly higher in rats exposed to nicotine compared to the control group ($p < 0.05$).

Nicotine-associated oxidative stress triggers inflammation, where inflammatory cells release mediators, and cause apoptosis (36). Apoptosis can be induced by the apoptotic pathway of TNF- α (11). In addition, secondary necrosis occurs in apoptotic cells when the cellular content and degradative enzymes are released into the environment during the clearance of these cells. The resulting change in the local pH and enzymatic reactions may cause intratesticular damage. Natural products and dietary agents have been reported to play significant role in the prevention and amelioration of wide variety of diseases (37). Along with apoptosis-enhancing effects, proinflammatory cytokines may have a negative effect on the blood-testis barrier which is formed by combined Sertoli cells supported by tight junctions and separates the germ cells from the systemic circulation during the developmental process (38). It has been reported that TNF- α and IL-6 increase the production of nitrite oxide, thus affecting spermatozoal function

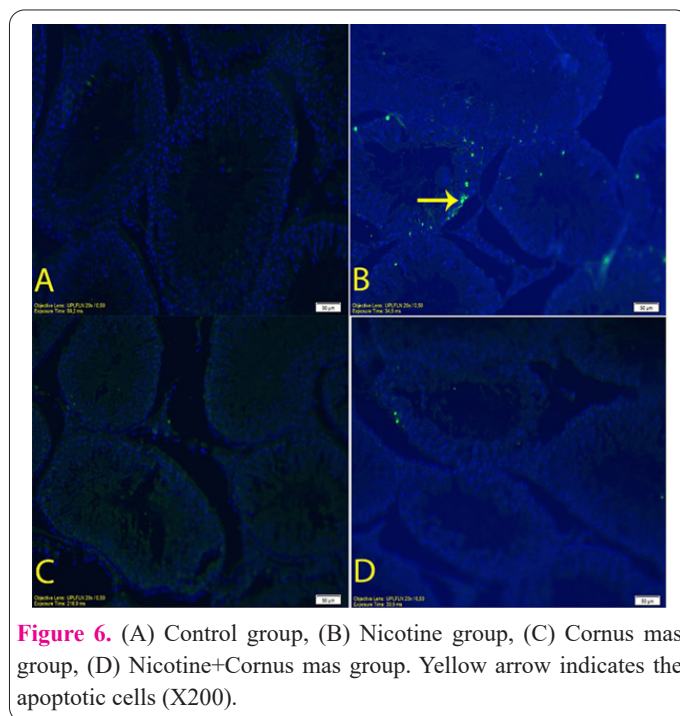


Figure 6. (A) Control group, (B) Nicotine group, (C) Cornus mas group, (D) Nicotine+Cornus mas group. Yellow arrow indicates the apoptotic cells (X200).

(39). Moreover, IL-6 may damage the blood-testis barrier by disrupting tight junctions in Sertoli cells (9). In addition, it has been reported that nicotine exposure in germ cells causes an increase in apoptosis activity and TUNEL-positivity increases in cells that have undergone apoptosis (40, 41). According to the results of our study, the levels of TNF- α and IL-6 were significantly higher in rats exposed to nicotine compared to the control group. In our study, we used the TUNEL method to show cells that underwent apoptosis as a result of nicotine exposure. We observed nicotine-associated increases in apoptotic cells and proinflammatory cytokines, however, the number of apoptotic cells and cytokine levels were noted to be significantly reduced in rats administered with CM extract together with nicotine compared to the group receiving nicotine alone. CM significantly decreased nicotine-induced apoptosis in testicular tissue. These results suggested that CM extract exerted protective effects on the blood testis barrier due to its anti-inflammatory properties. We also found that CM inhibits inflammation increased by nicotine.

Oxidative stress products can cause destructive effects on sperm membranes and DNA. Spermatogenesis may be negatively affected by an increase in ROS and lipid peroxidation in the testicles (42, 43). Oxidative stress-related induction of lipids in the cell membrane releases unsaturated reactive aldehyde product MDA, which is used as an indicator of oxidative stress (44). Therefore, in our study, we decided to measure oxidative stress by analysis of MDA levels. Rats exposed to nicotine had significantly higher MDA, TOS, and OSI values compared to the control group. When the rats were exposed to CM and nicotine there was a significant decrease in MDA and OSI levels compared to the nicotine-only group. In addition, the levels of antioxidative biochemical markers such

as TAS and GSH were significantly lower in the nicotine group compared to the control group. In the CM + nicotine group, there was an increase in both TAS and GSH levels but a significant increase was observed in TAS level. These results suggest that CM extract may have protective effects against the destructive effects of nicotine through antioxidative mechanisms. Thus, CM inhibits reactive oxygen species by increasing antioxidant capacity. This shows that oxidative stress is significantly reduced by CM.

Another parameter evaluated in this study was factor VIII, which is an essential coagulation factor that is synthesized from the vascular endothelium and released into the bloodstream. Factor VIII is an important indicator of vascularization and evaluates neovascularization by vascular density analysis (45). Emerging evidence suggested that oxidative stress-induced hypoxia triggered the process of angiogenesis. ROS induces endothelial migration and proliferation by increasing VEGF (Vascular Endothelial Growth Factor) expression in endothelial cells, smooth muscle cells, and macrophages. In our study, high levels of factor VIII protein in nicotine-treated animals support the notion that angiogenesis was induced by oxidative stress. Factor VIII levels were significantly lower in the nicotine + CM group compared to the nicotine group, which suggests that CM extract reduced the angiogenic effects of nicotine. Our Johnsen testicular biopsy score, apoptosis, and factor VIII results together indicate that CM extract significantly decreases nicotine-induced tissue damage and suggest that this plant has protective features.

The semen analysis in our study showed that nicotine disrupted spermatogenesis and significantly decreased sperm count, motility and viability compared to the control group. Significant improvements were observed in seminal parameters when CM extract was given together with nicotine. In line with our results, CM has been reported to improve the semen parameters mainly through a reduction in oxidative stress (21). We have evidence to believe that CM extract counteracts nicotine's harmful effects on spermatogenesis by both histological and biochemical protective mechanisms. Importantly, natural products have remarkable pharmacological properties. In recent years, substantial achievements have been made in the characterization of the fundamental molecular mechanisms underlying pathogenesis (46-50). Therefore, there is a need to identify the most potent bioactive ingredients of CM extracts and critically evaluate the inhibitory effects on oxidative stress-induced testicular damage. Furthermore, evaluation of the biodistribution of the extracts and active ingredients in testicular tissues is another exciting area of research. It has been observed that CM application reduces the damage to the testicular tissue and thus significantly improves the semen analysis results.

Limitations of the study

We have several limitations in our study. Firstly, the effect of the CM extract was not titrated by evaluating dose intervals. Secondly, reproductive hormones were not assessed.

The effects of little-known antioxidant fruits on human health are the focus of current research studies. It is known that nicotine exerts destructive effects on the testicular tissue via oxidative and inflammatory mechanisms. In this study, we investigated the protective effects of CM fruit against the nicotine-induced biochemical, inflammatory,

histological and seminal parameters. We found that CM extract reduces intratesticular damage, apoptosis and angiogenesis and consequently increases spermatogenesis via antioxidative and anti-inflammatory mechanisms. More prospective randomized studies are needed to clarify specific mechanisms involved in this process. In this context, we believe that it will be an important source for researchers who will evaluate the effects of CM on different infertility models. At the same time, we plan to continue to evaluate the effects of CM on infertility with new methods and to continue the evaluation with clinical trials in the future.

Conflict of interest

The authors declare no conflict of interest.

Author contributions

Ünal Öztekin; Project administration, Conceptualization. Mehmet Caniklioğlu; Roles/Writing of original draft. Şükrü Ateş; Investigation; Methodology. Züleyha Doğanıyigit; Conceptualization; Data curation. Emin Kaymak; Writing - review & editing. Fatih Fırat; Investigation; Methodology. Ayşe Yeşim Göçmen; Conceptualization; Data curation. Fatih Ataç; Formal analysis, Investigation. Rukset Attar; Writing - review & editing. Seher Yılmaz; Investigation; Methodology.

References

1. Kazimierski M, Regula J, Molska M. Cornelian cherry (*Cornus mas* L.) - characteristics, nutritional and pro-health properties. *Acta Sci Pol Technol Aliment* 2019; 18(1): 5-12.
2. Moldovan B, Filip A, Clichici S, Suharoschi R, Bolfa P, David L. Antioxidant activity of Cornelian cherry (*Cornus mas* L.) fruits extract and the in vivo evaluation of its anti-inflammatory effects. *J Funct Foods* 2016; 26: 77-87.
3. Hosseinpour-Jaghdani F, Shomali T, Gholipour-Shahraki S, Rahimi-Madiseh M, Rafeian-Kopaei M. *Cornus mas*: a review on traditional uses and pharmacological properties. *J Complement Integr Med* 2017; 14(3): /j/jcim.2017.14.issue-3/jcim-2016-0137/jcim-2016-0137.xml.
4. Motaghinejad M, Motevalian M, Fatima S, Faraji F, Mozaffari S. The Neuroprotective Effect of Curcumin Against Nicotine-Induced Neurotoxicity is Mediated by CREB-BDNF Signaling Pathway. *Neurochem Res* 2017; 42(10): 2921-2932.
5. Saad AB, Rjeibi I, Brahmi N, Elaloui E, Zouari N. Nicotine-induced oxidative stress, testis injury, AChE inhibition and brain damage alleviated by *Mentha spicata*. *Inflammopharmacology* 2020; 28(4): 939-948.
6. Zhao F, Guo L, Wang X, Zhang Y. Correlation of oxidative stress-related biomarkers with postmenopausal osteoporosis: a systematic review and meta-analysis. *Arch Osteoporos* 2021; 16(1): 4.
7. de Vries DK, Kortekaas KA, Tsikas D, Wijermars LG, van Noorden CJ, Suchy MT, Cobbaert CM, Klautz RJ, Schaapherder AF, Lindeman JH. Oxidative damage in clinical ischemia/reperfusion injury: a reappraisal. *Antioxid Redox Signal* 2013; 19(6): 535-45.
8. Hedger MP. Testicular leukocytes: what are they doing? *Rev Reprod* 1997; 2(1): 38-47.
9. Zhang H, Yin Y, Wang G, Liu Z, Liu L, Sun F. Interleukin-6 disrupts blood-testis barrier through inhibiting protein degradation or activating phosphorylated ERK in Sertoli cells. *Sci Rep* 2014; 4: 4260.
10. Lombard C, Farthing D, Sun J, Fariss MW, McKallip RJ. Reference moist smokeless tobacco-induced apoptosis in human

- monocytes/macrophages cell line MM6. *Int Immunopharmacol* 2010; 10(9): 1029-1040.
11. Nie D, Zhang D, Dai J, Zhang M, Zhao X, Xu W, Chen Z, Wang L, Wang Z, Qiao Z. Nicotine Induced Murine Spermatozoa Apoptosis via Up-Regulation of Deubiquitinated RIP1 by Trim27 Promoter Hypomethylation. *Biol Reprod* 2016; 94(2): 31.
 12. Carson SA, Kallen AN. Diagnosis and Management of Infertility: A Review. *JAMA* 2021;326(1):65-76.
 13. Matzuk MM, Lamb DJ. Genetic dissection of mammalian fertility pathways. *Nat Cell Biol* 2002; 4 Suppl: s41-9.
 14. Gabrielsen JS, Tanrikut C. Chronic exposures and male fertility: the impacts of environment, diet, and drug use on spermatogenesis. *Andrology* 2016; 4(4): 648-661.
 15. Wu J, Xu W, Zhang D, Dai J, Cao Y, Xie Y, Wang L, Qiao Z, Qiao Z. Nicotine inhibits murine Leydig cell differentiation and maturation via regulating Hedgehog signal pathway. *Biochem Biophys Res Commun* 2019; 510(1): 1-7.
 16. Bisong SA, Ukoh IE, Nna VU, Ebong PE. Vitamin E attenuates nicotine- and noise-induced reproductive impairment in male albino Wistar rats. *Andrologia* 2018; 50(7): e13050.
 17. Ezzatabadipour M, Azizollahi S, Sarvazad A, Mirkahnooj Z, Mahdinia Z, Nematollahi-Mahani SN. Effects of concurrent chronic administration of alcohol and nicotine on rat sperm parameters. *Andrologia* 2012; 44(5): 330-6.
 18. Hamed KA, El-Fiky SA, Gawish AM, Khalil WKB, Mohamed HRH. Alleviation of nicotine-induced reproductive disorder, clastogenicity, and histopathological alterations by fenugreek saponin bulk and nanoparticles in male rats. *Environ Sci Pollut Res Int* 2022; 29(31): 47488-47501.
 19. Oztekin U, Caniklioglu M, Firat F, Atac F, Doganyigit Z, Gocmen AY, Yilmaz S, Tokpinar A. Carob attenuates nicotine-induced oxidative stress and intratesticular damage in male rats. *Andrologia* 2020; 52(9): e13670.
 20. Hosseinpour-Jaghdani F, Shomali T, Gholipour-Shahraki S, Rahimi-Madiseh M, Rafeian-Kopaei M. *Cornus mas*: a review on traditional uses and pharmacological properties. *J Complement Integr Med* 2017; 14(3): /j/jcim.2017.14.issue-3/jcim-2016-0137/jcim-2016-0137.xml.
 21. Zarei L, Shahrooz R, Sadrkhanlou R, Malekinejad H, Ahmadi A, Bakhtiary Z. Protective effects of *Cornus mas* extract on in vitro fertilization potential in methotrexate treated male mice. *Vet Res Forum* 2015; 6(1): 55-61.
 22. Yilmaz S, Alpa Ş, Nisari M, Karatoprak GS, Doğanyigit Z, Ülger H, Ertekin T. Examining the Antitumoral Effect of Cornelian Cherry (*Cornus mas*) in Ehrlich Ascites Tumor-Induced Mice. *J Anat Soc India* 2019; 68(1): 16-22.
 23. Alavian SM, Banihabib N, Es Haghi M, Panahi F. Protective Effect of *Cornus mas* Fruits Extract on Serum Biomarkers in CCl4-Induced Hepatotoxicity in Male Rats. *Hepat Mon.* 2014; 14(4): e10330.
 24. Lowry OH, Rosebrough NJ, Farr AL, Randall RJ. Protein measurement with the Folin phenol reagent. *J Biol Chem* 1951; 193(1): 265-275.
 25. Öztürk O, Gümüşlü S. Changes in glucose-6-phosphate dehydrogenase, copper, zinc-superoxide dismutase and catalase activities, glutathione and its metabolizing enzymes, and lipid peroxidation in rat erythrocytes with age. *Exp Gerontol* 2004; 39(2): 211-216.
 26. Karabulut D, Öztürk E, Kaymak E, Akin AT, Yakan B. Thymoquinone attenuates doxorubicin-cardiotoxicity in rats. *J Biochem Mol Toxicol* 2021; 35(1): e22618.
 27. Johnsen SG. Testicular biopsy score count--a method for registration of spermatogenesis in human testes: normal values and results in 335 hypogonadal males. *Hormones* 1970; 1(1): 2-25.
 28. Doğanyigit Z, Silici S, Demirtaş A, Kaya E, Kaymak E. Determination of histological, immunohistochemical and biochemical effects of acute and chronic grayanotoxin III administration in different doses in rats. *Environ Sci Pollut Res Int* 2019; 26(2): 1323-1335.
 29. Öztürk E, Kaymak E, Akin AT, Karabulut D, Ünsal HM, Yakan B. Thymoquinone is a protective agent that reduces the negative effects of doxorubicin in rat testis. *Hum Exp Toxicol* 2020; 39(10): 1364-1373.
 30. Mizgier P, Kucharska AZ, Sokol-Letowska A, Kolniak-Ostek J, Kidon M, Fecka I. Characterization of phenolic compounds and antioxidant and anti-inflammatory properties of red cabbage and purple carrot extracts. *J Funct Foods* 2016; 21: 133-146.
 31. Jana K, Samanta PK, De DK. Nicotine diminishes testicular gametogenesis, steroidogenesis, and steroidogenic acute regulatory protein expression in adult albino rats: possible influence on pituitary gonadotropins and alteration of testicular antioxidant status. *Toxicol Sci* 2010; 116(2): 647-659.
 32. Condorelli RA, La Vignera S, Giacone F, Iacoviello L, Vicari E, Mongioi' L, Calogero AE. In vitro effects of nicotine on sperm motility and bio-functional flow cytometry sperm parameters. *Int J Immunopathol Pharmacol* 2013; 26(3): 739-746.
 33. Kim KH, Joo KJ, Park HJ, Kwon CH, Jang MH, Kim CJ. Nicotine induces apoptosis in TM3 mouse Leydig cells. *Fertil Steril* 2005; 83 Suppl 1: 1093-1099.
 34. Nesseim WH, Haroun HS, Mostafa E, Youakim MF, Mostafa T. Effect of nicotine on spermatogenesis in adult albino rats. *Andrologia* 2011; 43(6): 398-404.
 35. Erat M, Ciftci M, Gumustekin K, Gul M. Effects of nicotine and vitamin E on glutathione reductase activity in some rat tissues in vivo and in vitro. *Eur J Pharmacol* 2007; 554(2-3): 92-97.
 36. Kushwaha S, Jena GB. Effects of nicotine on the testicular toxicity of streptozotocin-induced diabetic rat: intervention of enalapril. *Hum Exp Toxicol* 2014; 33(6): 609-622.
 37. Farooqi AA, Pinheiro M, Granja A, Farabegoli F, Reis S, Attar R, Sabitaliyevich UY, Xu B, Ahmad A. EGCG Mediated Targeting of Deregulated Signaling Pathways and Non-Coding RNAs in Different Cancers: Focus on JAK/STAT, Wnt/β-Catenin, TGF/SMAD, NOTCH, SHH/GLI, and TRAIL Mediated Signaling Pathways. *Cancers (Basel)*. 2020 Apr 12;12(4):951. doi: 10.3390/cancers12040951.
 38. Kopera IA, Bilinska B, Cheng CY, Mruk DD. Sertoli-germ cell junctions in the testis: a review of recent data. *Philos Trans R Soc Lond B Biol Sci* 2010; 365(1546): 1593-1605.
 39. Lampiao F, du Plessis SS. TNF-alpha and IL-6 affect human sperm function by elevating nitric oxide production. *Reprod Biomed Online* 2008; 17(5): 628-631.
 40. Gu Y, Xu W, Nie D, et al. Nicotine induces Nme2-mediated apoptosis in mouse testes. *Biochem Biophys Res Commun* 2016; 472(4): 573-579.
 41. He L, Gong H, Zhang J, et al. Interaction of exposure concentration and duration in determining the apoptosis of testis in rats after cigarette smoke inhalation. *Saudi J Biol Sci* 2016; 23(4): 531-541.
 42. Aprioku JS, Ugwu TC. Comparative Evaluation of the Impact of Subacute Exposure of Smokeless Tobacco and Tobacco Smoke on Rat Testis. *Int J Reprod Med* 2015; 2015: 676245.
 43. Kiziler AR, Aydemir B, Onaran I, Alici B, Ozkara H, Gulyasar T, Akyolcu MC. High levels of cadmium and lead in seminal fluid and blood of smoking men are associated with high oxidative stress and damage in infertile subjects. *Biol Trace Elem Res* 2007; 120(1-3): 82-91.
 44. Aprioku JS. Pharmacology of free radicals and the impact of reactive oxygen species on the testis. *J Reprod Infertil* 2013; 14(4): 158-172.
 45. de Souza TR, de Souza AK, Garcia SB, das Neves LMS, Barbosa

- RI, de Jesus Guirro RR, de Oliveira Guirro EC. Photobiomodulation Increases Viability in Full-Thickness Grafts in Rats Submitted to Nicotine. *Lasers Surg Med* 2020; 52(5): 449-455.
46. Farooqi AA, Qureshi MZ, Khalid S, Attar R, Martinelli C, Sabitaliyevich UY, Nurmurazayevich SB, Taverna S, Poltronieri P, Xu B. Regulation of Cell Signaling Pathways by Berberine in Different Cancers: Searching for Missing Pieces of an Incomplete Jig-Saw Puzzle for an Effective Cancer Therapy. *Cancers (Basel)*. 2019 Apr 4;11(4):478. doi: 10.3390/cancers11040478.
47. Wang HR, Tang JY, Wang YY, Farooqi AA, Yen CY, Yuan SF, Huang HW, Chang HW. Manoalide Preferentially Provides Antiproliferation of Oral Cancer Cells by Oxidative Stress-Mediated Apoptosis and DNA Damage. *Cancers (Basel)*. 2019 Sep 4;11(9):1303. doi: 10.3390/cancers11091303.
48. Farooqi AA, Fayyaz S, Hou MF, Li KT, Tang JY, Chang HW. Reactive oxygen species and autophagy modulation in non-marine drugs and marine drugs. *Mar Drugs*. 2014 Nov 13;12(11):5408-24. doi: 10.3390/md12115408.
49. Yu TJ, Shiau JP, Tang JY, Farooqi AA, Cheng YB, Hou MF, Yen CH, Chang HW. Physapruin A Exerts Endoplasmic Reticulum Stress to Trigger Breast Cancer Cell Apoptosis via Oxidative Stress. *Int J Mol Sci*. 2023 May 16;24(10):8853. doi: 10.3390/ijms24108853.
50. Gasparri ML, Besharat ZM, Farooqi AA, Khalid S, Taghavi K, Besharat RA, Sabato C, Papadia A, Panici PB, Mueller MD, Ferretti E. MiRNAs and their interplay with PI3K/AKT/mTOR pathway in ovarian cancer cells: a potential role in platinum resistance. *J Cancer Res Clin Oncol*. 2018 Dec;144(12):2313-2318. doi: 10.1007/s00432-018-2737-y.