

Expression and clinical significance of Capase3 and C-IAP1/2 in ectopic endometrium of patients with endometriosis

Xiaoyun Zhang, Weiyang Zhao*

Zhongda Hospital Southeast University (Jiang Bei), Nanjing, China

ARTICLE INFO

Original paper

Article history:

Received: April 02, 2023

Accepted: June 12, 2023

Published: July 31, 2023

Keywords:

Capase3, C-IAP1/2, endometriosis

ABSTRACT

To analyze the expression of capase3 and C-IAP1/2 in endometriosis and their relationship with clinical practice. Ectopic and eutopic endometrial tissues were collected from women with endometriosis, and the control tissues were obtained from regular patients without endometriosis. The expression level of capase3 and C-IAP1/2 was detected by immunohistochemistry; in addition, the relationship between C-IAP1/2 expression and the clinical stage of endometriosis was analyzed. The expression of Caspase-3 in ectopic and eutopic endometrium was significantly lower than that in the control group ($P < 0.005$). The expression of C-IAP1/2 in ectopic and situ endometrium was significantly higher than in the control group ($P < 0.005$). The expression of C-IAP1/2 in stage III-IV was higher than in stage I-II endometriosis. The positive expression of c-IAP1 protein in ectopic endometrial tissue was negatively correlated with the positive expression of Caspase-3 protein in ectopic endometrial tissue ($P < 0.001$). The low expression of Caspase-3 and the high expression of C-IAP1/2 in the ectopic endometrium and eutopic endometrial tissues compared with the controls. The results indicated that the apoptotic ability of eutopic and ectopic endometrium is weakened, which is involved in the pathogenesis of endometriosis. It is expected to be a target for the diagnosis and therapy of this disease. At the same time, the expression level of C-IAP1/2 is related to the stage of endometriosis, which can guide clinical treatment.

Doi: <http://dx.doi.org/10.14715/cmb/2023.69.7.20>Copyright: © 2023 by the C.M.B. Association. All rights reserved. 

Introduction

Endometriosis (EMs) is a common gynecological condition in women of childbearing age. Endometriosis of the ovaries is the most common. EMs is an often painful condition of the uterus in which tissue similar to the lining of the uterus (endometrium) begins to grow outside the uterus. Therefore, it may involve the ovaries (ovarian endometriosis), fallopian tubes, and pelvic lining. Endometrial-like tissue is rarely found outside the area of the pelvic organs. During EMs, the removed tissue also thickens and breaks down with each menstrual cycle. It is for this reason that women with this disorder experience heavy bleeding. Because the heterotopic tissue cannot leave your body, it becomes trapped. When it affects the ovaries, cysts called endometrioma cysts or endometriosis cysts may develop (1).

Penetration of the endometrium into the tissue covering the pelvis can cause pelvic tissues and organs to stick together. This issue is usually effective on reducing the fertility of women. Nowadays, a lot of research has been done on EMs and pregnancy.

The most important initial symptom of EMs is pelvic pain, often accompanied by menstrual periods. This pain may get worse over time. Other common signs and symptoms of EMs include: 1) Pain during menstruation (dysmenorrhea): Pelvic pain and cramping may start before menstruation and continue for a few days after menstruation. You may also experience pain in your lower back and abdomen (a symptom of an endometrioma). 2) Pain during

sex: With endometriosis, pain during or after sex is common. 3) Pain during bowel movements or urination (bladder endometriosis symptoms): You often experience these symptoms during your period. 4) Excessive menstrual bleeding: You may even experience spotting during your period (a symptom of endometriosis) (1-3).

Although much research has been done on EMs, the specific pathogenesis of the disease is still unclear, and its prevention and treatment remain challenging. In recent years, an increasing number of researchers have focused on the role of apoptosis in developing the disease (2-4). In this study, we compared the expression of capase3 and C-IAP1/2 in the ectopic and eutopic endometrial tissues of normal subjects and patients with endometriosis. We correlated C-IAP1/2 with clinical staging to investigate the role of capase3 and C-IAP1/2 in endometriosis disease and to reveal the relationship between apoptosis and the development of endometriosis disease. This study aims to examine the role of apoptosis and C-IAP1/2 in endometriosis, show the relationship between apoptosis and endometriosis, and lay the foundation for the prevention, diagnosis, and treatment of the disease.

Materials and Methods

General information

Twenty-two cases of endometriosis with concomitant diagnostic curettage admitted to our hospital from November 2017 to March 2022 were selected for the study. The patients were aged 29-45 years (median 44 years) accor-

* Corresponding author. Email: 17512550780@163.com

ding to the clinical staging criteria of the American Fertility Society: stage I-II in 8 cases and stage III-IV in 12 cases. Two patients with abdominal wall endometriosis are listed separately.

Inclusion criteria: Ectopic endometrial tissue was diagnosed by post-operative pathology, ectopic endometrial tissue was obtained from patients with endometriosis by curettage or surgical excision, and all patients had complete medical records and signed an informed consent form.

Exclusion criteria: Hormone therapy six months before surgery, endocrine disease, and tumor history. Twenty-five normal endometrial tissues were selected as controls from patients who had undergone hysterectomy for uterine fibroids but not for endometriosis or adenomyosis. The age of the patients ranged from 42 to 56 years (median 50 years), and the difference in age between the two groups was not statistically significant.

Research Methodology

Main reagents and instruments

Immunohistochemistry (histochemistry) kits were purchased from Beijing Zhongshan Jinqiao Biotechnology Co Ltd. (Beijing, China), primary antibodies Capase3 and C-IAP1/2 were purchased from Abcam (Cambridge, MA, USA), and secondary antibodies for immunohistochemistry were purchased from Thermo Fisher (Waltham, MA, USA). An Olympus light microscope and an Olympus (Tokyo, Japan) microphotography system were used for observation and photography.

Using immunohistochemistry (SP method)

Capase3 and C-IAP1/2 expression were detected according to the kit instructions as follows: sections were baked at 60°C for 20 min, then dewaxed by immersion in xylene, hydrated in anhydrous alcohol, 95%, 80%, and 70% alcohol for 2 min, rinsed three times in PBS, boiled in 0.01 mol/L citrate buffer (pH 6.0) (95°C, 15-20 min), cool naturally for 20 min or more for antigen repair, rinse three times in PBS, incubate 20 min at room temperature, incubate primary antibody overnight at four °C, rinse three times in PBS, incubate secondary antibody at room temperature for one h, rinse three times in PBS, stain in DAB for 5-10 min, color under a microscope, rinse 10 min in tap water to terminate The reaction was released by rinsing with tap water for 10 min, hematoxylin staining for 30 s, dehydration, blocking (using a drop of neutral gum next to the tissue, then covering with a coverslip) and microscopic examination.

Determination of results

Each section was randomly selected from 10 fields of view, and 100 cells were counted. The percentage of positive staining (<25% is 1, 25%-75% is 2, >75% is 3) is determined by the product of the intensity of staining and the percentage of positive cells, with a yield of less than three being considered harmful and more than or equal to 3 being considered positive.

Statistical analysis

Statistical Product and Service Solutions (SPSS) 17.0 statistical software (SPSS Inc., Chicago, IL, USA) was used for statistical analysis, and statistical data were ex-

pressed as (cases (%)). χ^2 test was used for comparison between the two groups, and the t-test was used for measurement data (\pm).spearman correlation analysis was used.

Results

Expression of capase3 in various groups

The positive expression of capase3 protein was lower in ectopic endometrium, and ectopic endometrial tissues than in normal endometrial tissues in patients with endometriosis, and the difference was statistically significant ($\chi^2=15.6, P=0.000; \chi^2=32.6, P=0.000$). Ectopic endothelial tissues showed lower capase3 positive expression than eutopic endothelial tissues, and the difference was statistically significant ($\chi^2=5.5, P=0.02$). See Table 1, Figure 1.

Expression of C-IAP1/2

The positive expression of C-IAP1/2 protein was higher in both eutopic and ectopic endometrial tissues than in normal endometrial tissues, and the difference was statistically significant ($\chi^2=11.8, P=0.001; \chi^2=32.6, P=0.000$), and the positive expression of C-IAP1/2 protein was higher in Ectopic than eutopic endometrial tissues. The difference was statistically significant ($\chi^2=8.28, P= 0.004$). See Table 2, Figure 2.

Association of capase3 and C-IAP1/2 expression with clinical stage of endometriosis

In EMs eutopic endometrium (of which two abdominal wall endometriosis were excluded), the difference in capase3 expression between stage I-II and between stage III-IV was not statistically significant ($\chi^2=0.357, P>0.05$)

The difference in expression of C-IAP1/2 between

Table 1. Expression of capase3 protein in patients with endometriosis.

Group	amount	capase3(+)	capase3(-)
Control	25	22(88.0)	3(12.0)
Eutopic	22	7(32.0)	15(68.0)
Ectopic	22	1(4.5)	21(95.5)

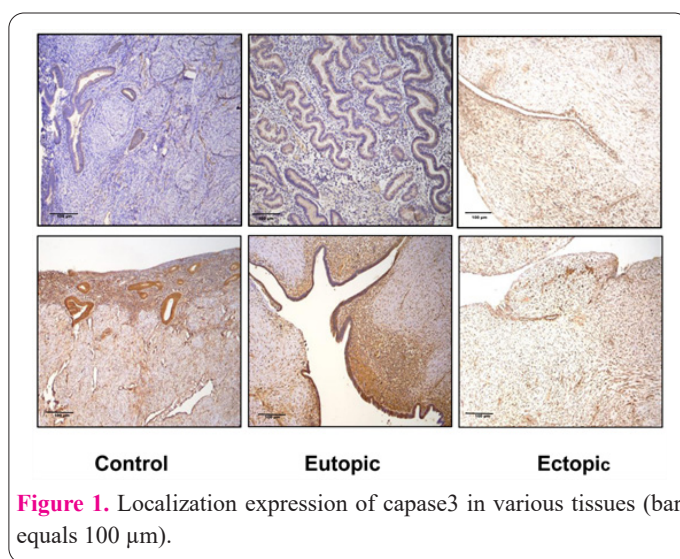
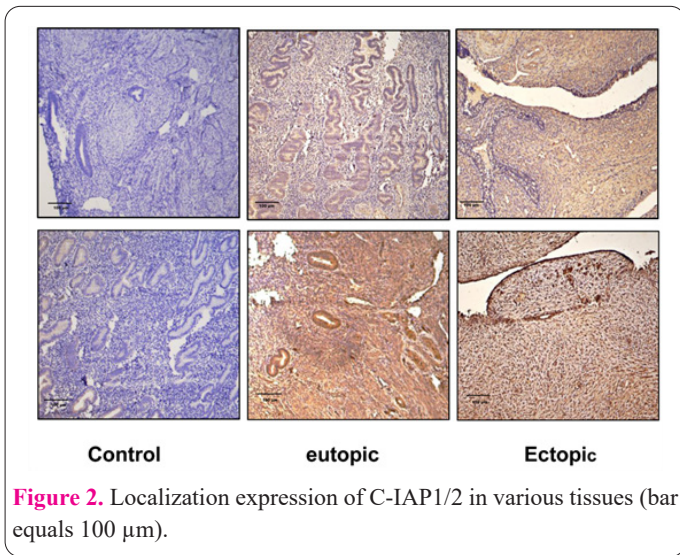


Figure 1. Localization expression of capase3 in various tissues (bar equals 100 µm).

Table 2. Expression of C-IAP1/2 protein in patients with endometriosis.

Group	Amount	C-IAP1/2(+)	C-IAP1/2(-)
Control	25	1(4.0)	24(96.0))
Eutopic	22	13(59.0)	9(41.0)
Ectopic	22	21(95.5)	1(4.5)



stages I-II and stage III-IV was statistically substantial ($\chi^2=4.848, P=0.02$); see Table 3.

Among the 22 patients with ectopic endometrial tissue, c-IAP1 and Caspase-3 protein were both positively expressed in 2 cases and negatively expressed in 3 cases. The positive expression of c-IAP1 protein in ectopic endometrial tissue was negatively correlated with the positive expression of Caspase-3 protein in ectopic endometrial tissue ($P<0.001$), as shown in Table 4.

Discussion

Although endometriosis is a common benign disease, it is characterized by malignant tumor invasion and metastasis (5-7). Most scholars believe that EMs develop due to a combination of immune, endocrine, and internal and external environmental factors (8, 9). In recent years, researchers have shown that endometrial cells in patients with endometriosis exhibit reduced apoptosis, significantly higher proliferation rates, and disrupted cycles (10). Currently, capase3 and C-IAP1/2 have been shown to play an essential role in the development and progression of various malignancies (4).

Caspase family as a class of cysteine proteases (11). Caspase-3 is one of the most critical proteases in the Caspase family Caspase-3 is one of the essential proteases in the Caspase family (12). The increased expression of caspase-3 can promote apoptosis (13). Therefore, it is called "death executive protease", which plays the final pivotal role in various kinds of apoptosis signal transduction.

Inhibitors of apoptosis proteins (IAPs), which have functions in regulating apoptosis, cycling, signal transduction, etc. (14, 15). The expression of IAPs is highly correlated with the nature, prognosis, and efficacy of tumors. The face is positively associated with tumor nature, prognosis, and outcome (16). Scientists have identified eight members of human IAPs: NAIP, cIAP1, cIAP2, XIAP, Survivin, BRUCE, Livin, and ILP-2 (17). Among them, c-IAP1/2 is an essential constituent member whose mechanism of action is to inhibit the activation of the caspase family members by inhibiting their mediated protease cascade reaction, thus acting as an inhibitor of apoptosis, which is considered to be an essential mechanism of anti-apoptosis in tumor cells This is deemed to be an important mechanism of anti-apoptosis in tumor cells (18). Now many studies have shown that c-IAP1/2 is highly expressed in a variety of tumors, such as prostate cancer, kidney clear cell cancer, laryngeal cancer, leukemia, etc., and the degree of expression is positively correlated with the severity of the disease (19, 20).

The results of this study showed that the positive expression of Caspase-3 protein in the eutopic and ectopic tissues of patients with endometriosis was significantly lower than that in normal control tissues. In contrast, the expression of c-IAP1/2 in the eutopic and ectopic tissues of patients with endometriosis showed high expression. This suggests that the abnormal expression of c-IAP1 /2 and Caspase-3 is closely related to endometriosis and has a role in the development and progression of the disease. The elevation of c-IAP1/2 may inhibit the activity of caspase3, which in turn inhibits apoptosis, resulting in a disordered state of diminished apoptosis and increased anti-apoptosis and uncontrolled proliferation of endometriosis cells, leading to the development of ectopic lesions, although the exact mechanisms involved need to be investigated in depth. This study also revealed that the expression of C-IAP1/2 was significantly higher in patients with stage III-IV endometriosis than in those with background I-II. This suggests that the degree of its expression is related to the clinical phase of the disease and provides a new direction for the treatment of endometriosis disease.

In conclusion, the abnormal expression of c-IAP1 /2 and Caspase-3 in endometriosis tissues is presumed to promote endometriosis by disrupting the balance between apoptosis and proliferation, leading to the disruption of apoptosis. This is a promising target for this disease's diagnosis and gene therapy. Due to our limited sample size, this study requires an expanded or multicentre study for

Table 3. Relationship between the expression of capase3 and C-IAP1/2 and the clinical staging of endometriosis.

Group	Amount	Capase3		C-IAP1/2	
		(+)	(-)	(+)	(-)
I~II	8	3	5	2	6
III~IV	12	3	9	9	3

Table 4. Spearman rank correlation analysis of c-IAP1 and Caspase-3 protein expression in ectopic endometrial tissue.

Group	capase3 ectopic tissue		r	P
c-IAP1/2 ectopic tissue	(+)	(-)		
(+)	2	16	-0.683	<0.001
(-)	1	3		

further clarification.

Declarations

Ethics approval and consent to participate

Not applicable

Consent for publication

Not applicable

Availability of data and materials

All data generated or analysed during this study are included in this published article

Competing interests

The authors declared that they have no conflicts of interest to this work.

Funding

Not applicable

Authors' contributions

XYZ analyzed and interpreted the patient data, and was a major contributor in writing the manuscript. WYZ is the director of the article. All authors read and approved the final manuscript.

Acknowledgements

None.

References

1. Yilmaz HB, Guler CS, Ata B. Endometrioma and ovarian reserve: effects of endometrioma per se and its surgical treatment on the ovarian reserve. *Facts Views Vis Obgyn* 2019; 11(2): 151-157.
2. Rolla E. Endometriosis: advances and controversies in classification, pathogenesis, diagnosis, and treatment. *F1000Res* 2019; 8: F1000 Faculty Rev-529.
3. Vetvicka V, Lagana AS, Salmeri FM, et al. Regulation of apoptotic pathways during endometriosis: from the molecular basis to the future perspectives. *Arch Gynecol Obstet* 2016; 294(5): 897-904.
4. Filip L, Duica F, Pradatu A, et al. Endometriosis Associated Infertility: A Critical Review and Analysis on Etiopathogenesis and Therapeutic Approaches. *Medicina-Lithuania* 2020; 56(9): 460.
5. Patel BG, Lenk EE, Lebovic DI, Shu Y, Yu J, Taylor RN. Pathogenesis of endometriosis: Interaction between Endocrine and inflammatory pathways. *Best Pract Res Clin Ob* 2018; 50: 50-60.
6. Reis FM, Monteiro CS, Carneiro MM. Biomarkers of Pelvic Endometriosis. *Rev Bras Ginecol Obs* 2017; 39(3): 91-93.
7. Han SJ, O'Malley BW. The dynamics of nuclear receptors and nuclear receptor coregulators in the pathogenesis of endometriosis. *Hum Reprod Update* 2014; 20(4): 467-484.
8. Zhang JW, Long TY, Pan W, Zhong QQ, Qian ZX, Jing R. MiR-808 inhibits cardiomyocyte apoptosis and expressions of caspase-3 and caspase-9 in rats with myocardial infarction by regulating TGF-beta1 signaling pathway. *Eur Rev Med Pharmacol* 2020; 24(12): 6955-6960.
9. Hsueh KC, Lin CL, Tung JN, Yang SF, Hsieh YH. Nimbolide induced apoptosis by activating ERK-mediated inhibition of c-IAP1 expression in human hepatocellular carcinoma cells. *Environ Toxicol* 2018; 33(9): 913-922.
10. Chen Q, Hang Y, Zhang T, Tan L, Li S, Jin Y. USP10 promotes proliferation and migration and inhibits apoptosis of endometrial stromal cells in endometriosis through activating the Raf-1/MEK/ERK pathway. *Am J Physiol-Cell Ph* 2018; 315(6): C863-C872.
11. Brentnall M, Rodriguez-Menocal L, De Guevara RL, Cepero E, Boise LH. Caspase-9, caspase-3 and caspase-7 have distinct roles during intrinsic apoptosis. *BMC Cell Biol* 2013; 14: 32.
12. Ledet MM, Harman RM, Fan JC, et al. Secreted sphingomyelins modulate low mammary cancer incidence observed in certain mammals. *Sci Rep-Uk* 2020; 10(1): 20580.
13. Kaya C, Alay I, Guraslan H, et al. The Role of Serum Caspase 3 Levels in Prediction of Endometriosis Severity. *Gynecol Obstet Inves* 2018; 83(6): 576-585.
14. Liang J, Zhao W, Tong P, et al. Comprehensive molecular characterization of inhibitors of apoptosis proteins (IAPs) for therapeutic targeting in cancer. *Bmc Med Genomics* 2020; 13(1): 7.
15. Fung S, Knoefel WT, Krieg A. Clinicopathological and Prognostic Significance of Inhibitor of Apoptosis Protein (IAP) Family Members in Lung Cancer: A Meta-Analysis. *Cancers* 2021; 13(16): 4098.
16. Cossu F, Milani M, Mastrangelo E, Lecis D. Targeting the BIR Domains of Inhibitor of Apoptosis (IAP) Proteins in Cancer Treatment. *Comput Struct Biotech* 2019; 17: 142-150.
17. Finlay D, Teriete P, Vamos M, Cosford N, Vuori K. Inducing death in tumor cells: roles of the inhibitor of apoptosis proteins. *F1000Res* 2017; 6: 587.
18. Van Opdenbosch N, Lamkanfi M. Caspases in Cell Death, Inflammation, and Disease. *Immunity* 2019; 50(6): 1352-1364.
19. Hsueh KC, Lin CL, Tung JN, Yang SF, Hsieh YH. Nimbolide induced apoptosis by activating ERK-mediated inhibition of c-IAP1 expression in human hepatocellular carcinoma cells. *Environ Toxicol* 2018; 33(9): 913-922.
20. Hu G, Wang X, Han Y, Wang P. Protein arginine methyltransferase 5 promotes bladder cancer growth through inhibiting NF-kB dependent apoptosis. *Excli J* 2018; 17: 1157-1166.