



Differential diagnosis of IgG4-related pancreatitis and pancreatic cancer by MRI features and its correlation with serum IgG4 level

Tao Lian¹, Xiaoyu Huang², Jie Fang¹, Lvye Huang¹, Xiaolan Yan¹, Jieyun Chen^{1*}

¹ Department of Imaging, Quanzhou First Hospital of Fujian Province, Quanzhou, 362000, Fujian Province, China

² Department of Pharmacy, Quanzhou First Hospital of Fujian Province, Quanzhou, 362000, Fujian Province, China

ARTICLE INFO

Original paper

Article history:

Received: December 15, 2022

Accepted: January 10, 2023

Published: January 31, 2023

Keywords:

MRI; IgG4-related AIP, PC, DDS, PD perforation sign, diagnostic sensitivity

ABSTRACT

It was to analyze the diagnostic value of MRI in immunoglobulin G (IgG4)-related autoimmune pancreatitis (AIP) and pancreatic cancer (PC) and its relationship with serum IgG4 level. 35 patients with IgG4-related AIP (group A1) and 50 patients with PC (group A2) were enrolled. MRI was performed to determine serum IgG4 levels. Spearmen was used to analyze the relationship between MRI characteristics and serum IgG4 level. It was found that patients in group A1 showed double duct sign (DDS), pancreatic duct (PD) perforation sign, the proportion of main PD truncation, and main PD diameter/pancreatic parenchymal width ratio, which were different from those of patients in group A2 ($P < 0.05$). MRI had a sensitivity (Sen) of 88%, specificity (Spe) of 91.43%, accuracy (Acc) of 89.41%, positive predictive value (PPV) of 0.936, and negative predictive value (NPV) of 0.842 for the diagnosis of IgG4-related AIP and PC. Serum IgG4 levels were significantly negatively correlated with DDS and main PD truncation, significantly positively correlated with PD penetration sign, and extremely significantly negatively correlated with main PD diameter/pancreatic parenchymal width ($P < 0.001$). The results showed that MRI had high sensitivity and specificity for differentiating IgG4-related AIP from PC, and the diagnostic effect was good, which had a high correlation with serum IgG4 levels in patients.

Doi: <http://dx.doi.org/10.14715/cmb/2022.69.1.18>

Copyright: © 2023 by the C.M.B. Association. All rights reserved.

Introduction

IgG is mainly synthesized and secreted by plasma cells in the spleen and lymph nodes, and IgG is the main component of immunoglobulin in serum, accounting for about 75% of the total immunoglobulin content in serum, of which 40 to 50% is distributed in serum and the rest is distributed in tissues (1-3). IgG4-related diseases are a type of chronic and progressive autoimmune diseases of unknown cause, in which the serum IgG4 cell level is significantly increased in patients, and the affected tissues and organs develop enlarged or nodular and proliferative lesions due to massive lymphocyte and IgG4-positive plasma cell infiltration, accompanied by tissue fibrosis, resulting in simultaneous or sequential involvement of multiple organs, and it can only involve one organ (4,5). IgG-associated pancreatitis is an immune-mediated chronic fibroinflammatory disease, and painless obstructive jaundice is the first clinical manifestation, followed by abdominal pain, decreased body mass, skin itching, and fatigue. It can be combined with extrapancreatic organ involvement, such as bile duct, lacrimal gland, salivary gland, retroperitoneum, lymph nodes, and aorta, and it often presents with local space-occupying manifestations of the affected organs or secondary symptoms caused by mass and is easily misdiagnosed as pancreatic malignancies (6-8). Therefore, the differential diagnosis of pancreatitis and PC is the focus of clinical research.

IgG-related pancreatitis is more common in elderly men, the clinical manifestations lack specificity, and it is difficult to confirm the diagnosis by clinical symptoms. Patients mostly present with obstructive jaundice, usually accompanied by abdominal dull pain and discomfort, weight loss, and extrapancreatic organs involvement, such as lacrimal glands, salivary glands, and thyroid glands, which present with dry eyes, dry mouth, and specific thyroiditis, and it can also cause Mikulicz syndrome, sclerosing cholangitis, and retroperitoneal fibrosis (9,10). CT, MRI, and PET-CT imaging are usually used to diagnose pancreatic diseases in clinical practice (11). According to the different absorption and transmittance of X-rays in different tissues of the human body, CT mainly uses an instrument with very high sensitivity to detect the human body, and the data that were obtained from the detection are input into the electronic computer. After the data are processed by the electronic computer, it can take the cross-sectional or stereoscopic image and find the small lesions, but its display performance for soft tissues is poor (12,13). PET-CT is the integration of PET and CT to complement the advantages of the two imaging techniques, Molecular information such as function are provided from PET images, and CT presents fine anatomical and pathological information. Through fusion techniques, pathophysiological changes and morphological changes in the disease can be observed by imaging, which is widely used in the diagnosis of malignant tumors as well as the differential

* Corresponding author. Email: chenjieyun@stu.cpu.edu.cn

diagnosis of benign and malignant lesions (14). MRI examination is mainly through the amount of hydrogen element content in the human body, in order to distinguish the corresponding image characteristics, and then through different image characteristics, to determine the corresponding organ function and the nature of the lesion, with the advantages of high resolution and high sensitivity (15).

Serum IgG4 is the most common, commonly used, and effective early warning sign in clinical practice, and IgG4 is often investigated in patients with high suspicion of PC in clinical practice. Elevated serum IgG4 is an important indicator for the diagnosis and disease evaluation of IgG4-related immune diseases, and is one of the most important biological markers for the diagnosis of the disease, evaluation of activity and efficacy of disease, as well as prognostic evaluation (16). However, as an item of diagnostic criteria, the specificity of serum IgG4 is not high, and its increase can be found in many other diseases, such as tumors, infections, connective tissue diseases, hematologic diseases, or allergic diseases, so it is not clear that the high level of IgG4 is significantly correlated with the condition of pancreatitis (17). Therefore, 85 patients who visited Quanzhou First Hospital of Fujian Province Hospital from October 10, 2016 to October 15, 2022 were enrolled as the study subjects. IgG4-related AIP patients were divided into group A1 and PC patients were divided into group A2. MRI images were performed to determine the serum IgG4 level. Spearsman was used to analyze the relationship between MRI image characteristics and serum IgG4 level. The diagnostic value of MRI technology for IgG4-related AIP and PC and the relationship with serum IgG4 level was deeply analyzed.

Materials and Methods

Study subjects

35 IgG4-related AIP patients and 50 PC patients who were diagnosed and treated at the dermatology clinic of Quanzhou First Hospital of Fujian Province Hospital from October 10, 2016 to October 15, 2022 were included as the study subjects, and IgG4-related AIP patients were enrolled in group A1 and PC patients in group A2. After review and approval by the hospital ethics committee, this clinical trial was approved and executed, and all patients signed an informed consent form before the implementation of the topic.

Inclusion criteria: (i) Patients with pancreatic head lesions; (ii) Patients with other pancreatic diseases; (iii) Patients older than 18 years; (iv) Patients who did not receive hormones, immunosuppressive agents, or biological agents; (v) Patients who were newly diagnosed.

Exclusion criteria: (i) Patients with infectious diseases; (ii) Patients with another tumor history; (iii) Patients with metastatic PC; (iv) Patients with severe heart, liver, and kidney organ disorders.

Imaging examination method

Patients were examined using a Discovery MR750w 3.0T system (GE, USA) with an 8-channel body-phased array surface coil. Fasting was performed for 8 h and water deprivation for 6 h before the examination, and the relevant knowledge and precautions of MRI scans were explained to the patients to guide the patients for holding their breath. The patients were in the supine position, foot at

front, and it was supplemented by respiratory gating, fixed phased array surface coil. All patients underwent cross-sectional T1-weighted imaging (T1WI), T2-weighted imaging (T2WI), and magnetic resonance cholangiopancreatography (MRCP). T1WI scan parameters: time of repetition (TR) 3.5 ms, time of echo (TE) 1.5 ms, the field of view (FOV) 450 mm × 400 mm, slice thickness 4.5 mm, interslice distance 1.5 mm, matrix 265 × 240. T2WI scan: TR 950 ms, TE 73 ms, FOV 360 mm × 300 mm, slice thickness 5 mm, interslice distance 1.5 mm, matrix 225 × 225. MRCP scan: TR 5,500 ms, TE 1,000 ms, matrix 300 × 250, excitation number 1.

Criteria for MRI image evaluation

Obtained MRI images were delivered to the workstation for processing and blinded assessment by two experienced radiologists. If the assessment results were inconsistent, two physicians communicated and discussed and finally consistent results were obtained. Evaluation items: (1) whether there is DDS in the main PD (the diameter of the main PD in the head of the pancreas is > 3 mm, and the diameter of the common bile duct is > 8 mm), the main PD is smooth or uneven in thickness, and the main PD penetrates the lesion area, measuring the diameter of the main PD, the diameter of the main PD/width of the pancreatic parenchyma; (2) the distribution of the dilated branch PD (only located in the head and neck, only located in the body and tail or the whole process of dilatation) and shape (dendritic dilatation, cystic dilatation or both); (3) the shape of the distal common bile duct (stenosis or truncation).

IgG4 detection method

4.5 mL of venous blood was collected from patients at the beginning of the day (empty stomach), centrifuged to separate serum, and serum IgG4 levels were measured by immune nephelometry.

Statistical processing

SPSS 19.0 statistical software was adopted to analyze data, with measurement data presented as mean ± standard deviation ($\bar{x} \pm s$), and enumeration data presented as percentage (%). The *t*-test and log-rank test were applied to the analysis of the differences in data between the groups. Spearsman was used to analyze the correlation between serum IgG4 levels and MRI diagnostic results in patients. Two-sided tests were statistically significant at $P < 0.05$.

Results

Analysis of MRI image data of patients in groups A1 and A2

Figure 1 shows MRI images of a 61-year-old female patient with IgG4-related AIP. Diffuse hypointense changes were observed on T1WI images, slightly hyperintense on

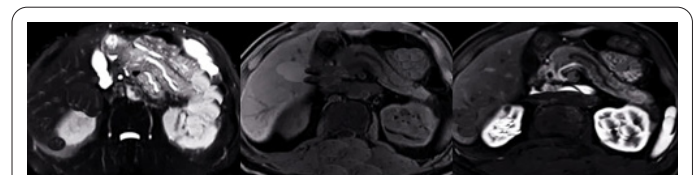


Figure 1. MRI images of patients with IgG4-related AIP. (Female, 61 years old, diarrhea due to abdominal distension after eating).

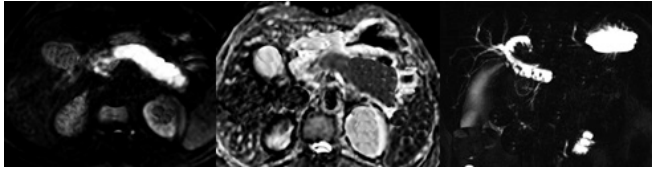


Figure 2. MRI images of a patient with PC. (male, 64-year-old, admitted to the hospital due to yellow staining of skin for three weeks).

T2WI images, and delayed enhancement of the pancreas in the lesion area after enhancement.

Figure 2 shows MRI images of a 74-year-old male patient with PC. History of present illness: The patient had yellow urine without obvious inducement 3 weeks ago, icteric sclera 2 weeks ago, progressive systemic yellow staining of the skin, and no abdominal pain. MRI images showed hypointense shadows around the inferior mesenteric artery, significant diffusion restriction in the body and pancreas tail, and patent but not smooth PD. T1WI showed slightly low signal intensity and T2WI showed slightly high signal intensity.

Comparison of age and gender between groups A1 and A2

Group A1 had 22 males and 13 females, with mean age of 58.12 ± 8.35 ; the average age of patients in group A2 was 60.07 ± 6.95 , 32 males and 18 females. The comparison showed that there was no obvious difference in the average age and sex between both groups ($P > 0.05$) (Figure 3).

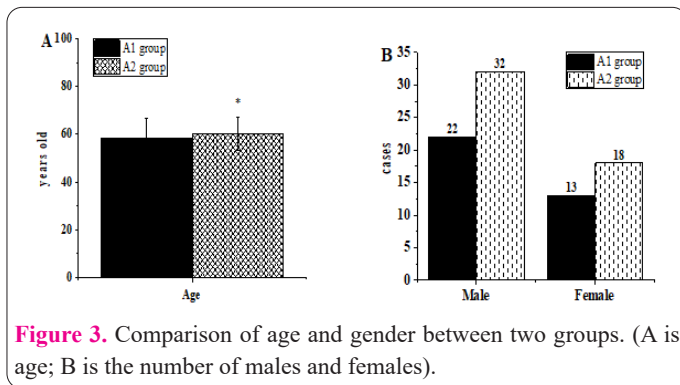


Figure 3. Comparison of age and gender between two groups. (A is age; B is the number of males and females).

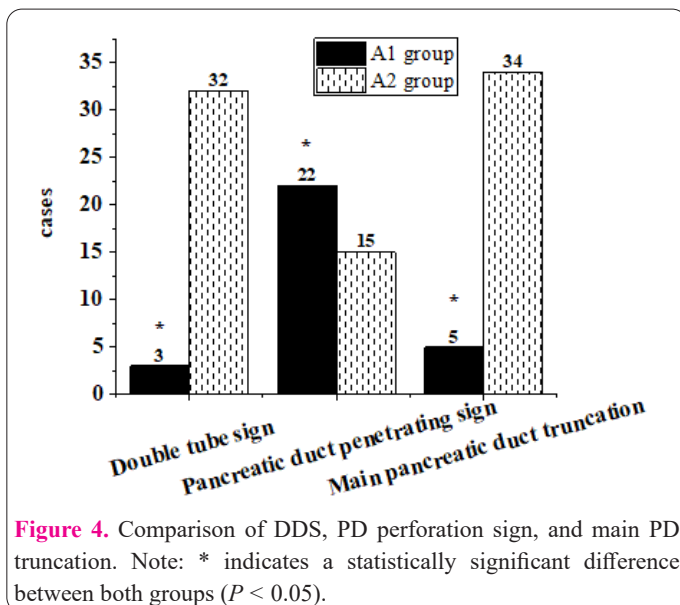


Figure 4. Comparison of DDS, PD perforation sign, and main PD truncation. Note: * indicates a statistically significant difference between both groups ($P < 0.05$).

Comparison of pancreaticobiliary imaging characteristics

As shown in Figure 4, group A1 presented with DDS in 3 patients (8.57%), PD perforation sign in 22 patients (62.86%), and main PD truncation in 5 patients (14.29%); group A2 presented with DDS in 32 patients (64%), PD perforation sign in 15 patients (32%), and main PD truncation in 34 patients (68%). The comparison showed that the proportion of DDS, PD perforation sign, and main PD truncation of group A1 was significantly different in contrast with that of group A2 ($P < 0.05$).

The diameter of the main PD was 4.68 ± 1.04 mm and the diameter of the main PD/width of the pancreatic parenchyma was 0.24 ± 0.07 in group A1; the diameter of the main PD was 5.11 ± 1.32 mm and the diameter of the main PD/width of the pancreatic parenchyma was 0.39 ± 0.11 in group A2. The comparison revealed that there was no obvious difference in the diameter of the main PD between the two groups; the diameter of the main PD/width of pancreatic parenchyma in group A1 was significantly lower than that in group A2 ($P > 0.05$) (Figure 5).

MRI performance in differentiating IgG4-related AIP from PC

As shown in Figures 6-7, MRI had a Sen of 88%, Spe of 91.43%, Acc of 89.41%, PPV of 0.936, and NPV of 0.842 for the diagnosis of IgG4-related AIP and PC.

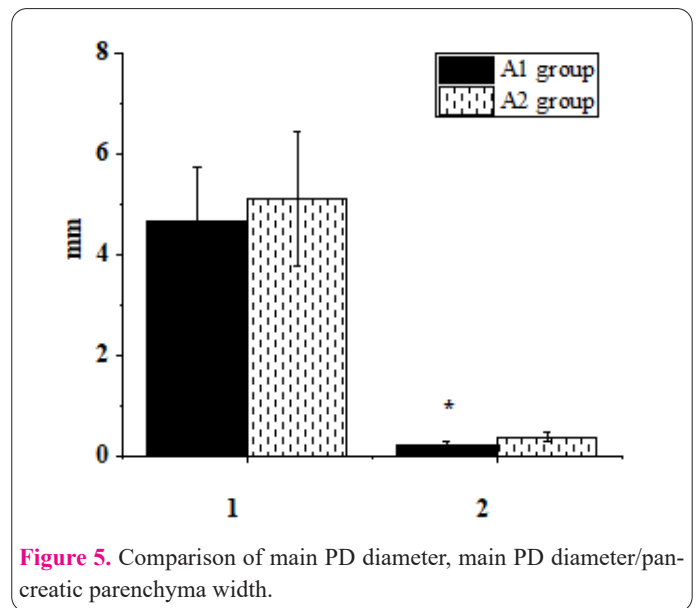


Figure 5. Comparison of main PD diameter, main PD diameter/pancreatic parenchyma width.

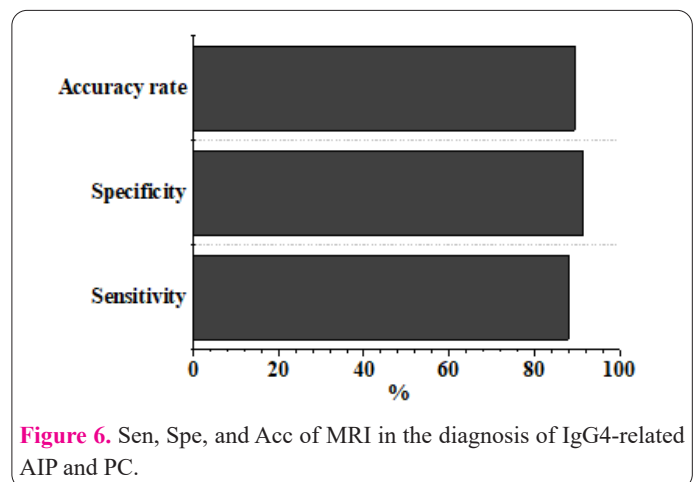


Figure 6. Sen, Spe, and Acc of MRI in the diagnosis of IgG4-related AIP and PC.

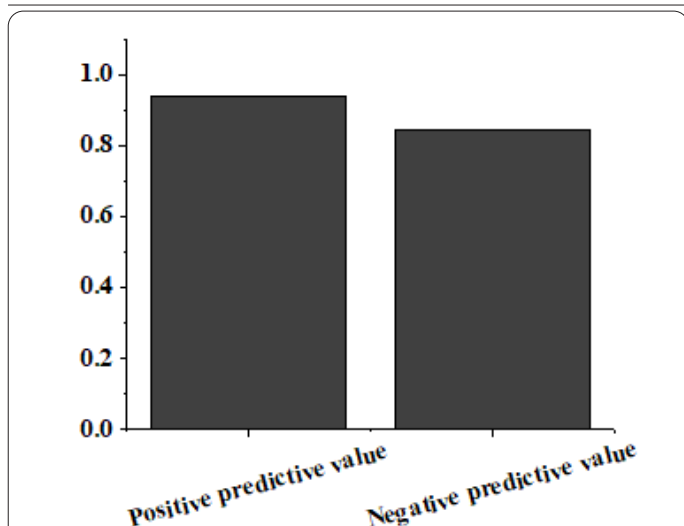


Figure 7. PPV and NPV of MRI in the diagnosis of IgG4-related AIP and PC.

Relationship between MRI characteristics and serum IgG4 levels in patients

Spearsman was used to analyze the relationship between MRI image characteristics and serum IgG4 levels in patients (Table 1). There was a clear negative relationship between serum IgG4 levels and double-duct sign ($r = -0.142$, $P = 0.008$), main PD truncation ($r = -0.125$, $P = 0.014$), a significant positive correlation between serum IgG4 levels and PD perforation sign ($r = -0.117$, $P = 0.011$), and a highly significant negative correlation between serum IgG4 levels and main PD diameter/pancreatic parenchymal width ($r = -0.183$, $P = 0.000$). Serum IgG4 levels were different from the main PD diameter ($r = -0.073$, $P = 0.062$).

Discussion

The pancreas is long, and it can be separated into several parts: head, body, and tail. The enlarged head of the pancreas is on the right side and is encircled by the duodenum. The end of the PD penetrating into the duodenal wall joins the common bile duct to be opened in the duodenal papilla to deliver pancreatic juice produced by the pancreatic exocrine part to the digestive tract. The pancreas is in close proximity to the stomach, duodenum, liver, gall bladder, spleen, and kidney and is a very important organ (18,19). Pancreatitis is an important affecting factor for PC. Pancreatitis and PC are diseases that occur in the pancreas of the human body, but their nature and degree of harm are different. Clinically, many patients with PC experience early symptoms and are mistaken for pancreatitis and miss the best time for treatment (20). In addition, pancreatitis is divided into acute and chronic pancreatitis, acute pancreatitis will easily develop into chronic pancrea-

titis, and inflammation for a long time is easy to deteriorate into PC. Chronic pancreatitis often coexists with PC. Because PC can obstruct the PD and lead to the occurrence of pancreatitis, it is not easy to judge the cause and effect of the two. Seeking efficient identification methods is the direction of clinical research (21,22). 85 patients who were diagnosed and treated at the dermatology clinic of XXX Hospital from October 10, 2016 to October 15, 2022 were included, with IgG4-related AIP patients in group A1 and PC patients in group A2, and MRI images were obtained. From the age and gender of the patients, there was no difference in the mean age and sex between the patients in the two groups ($P > 0.05$). The balance of baseline data between groups is to ensure the comparability of observation results of response variables between groups and to investigate the real impact of treatment factors on observation results under similar baseline conditions, which provides the basis for subsequent study and analysis.

The obtained MRI images were delivered to the workstation for processing, and a blinded assessment was performed by two experienced radiologists to analyze the imaging characteristics of the two groups of patients. The results suggested there was a difference in DDS, PD perforation sign, the proportion of main PD truncation, and the ratio of main PD diameter/pancreatic parenchymal width between the two groups ($P < 0.05$). DDS, truncation of the main PD at the lesion, and atrophy of the pancreatic parenchyma are widely considered highly suspicious findings for PC, and PD perforation sign, irregular dilatation of the main PD, and calcification of the pancreatic parenchyma are considered characteristic features of IgG4-related AIP (23,24). It revealed there was a distinction in the MRI features between IgG4-related AIP and PC. The higher the proportion of DDS and main PD truncation, the larger the ratio of main PD diameter/pancreatic parenchymal width indicated the greater the possibility of PC, while the higher the proportion of PD perforation sign indicated the greater the possibility of IgG4-related AIP. From the differential indicators, MRI had a Sen of 88%, Spe of 91.43%, Acc of 89.41%, PPV of 0.936, and NPV of 0.842 to diagnose IgG4-related AIP from PC. It indicated that MRI had a high sensitivity and specificity for the differentiation of IgG4-related AIP from PC and a good diagnostic effect (25). Spearsman was used to analyze the relationship between MRI characteristics and serum IgG4 levels, and it was observed that serum IgG4 levels were negatively related to double-duct sign ($r = -0.142$, $P = 0.008$), main PD truncation ($r = -0.125$, $P = 0.014$), positively to PD perforation sign ($r = -0.117$, $P = 0.011$), and negatively to main PD diameter/pancreatic parenchymal width ($r = -0.183$, $P = 0.000$). It suggested that MRI characteristics were highly correlated with serum IgG4 levels in patients, showing that the combined detection of the two can be applied in the differentiation of IgG4-related AIP from PC.

Table 1. Relationship between MRI image features and serum IgG4 levels.

Imaging characteristics	<i>r</i>	<i>P</i>
DDS	-0.142	0.008
Perforating PD sign	0.117	0.011
Truncation of main PD	-0.125	0.014
Main duct diameter	0.073	0.062
Main duct diameter/pancreatic parenchyma width	-0.183	0.000

35 IgG4-related AIP patients and 50 PC patients who visited Quanzhou First Hospital of Fujian Province Hospital from October 10, 2016 to October 15, 2022 were enrolled as the study subjects. IgG4-related AIP patients were divided into group A1 and patients with PC were divided into group A2. MRI images were performed to determine the serum IgG4 levels. Spearsman was used to analyze the relationship between MRI image characteristics and serum IgG4 levels. The results showed that MRI had high sensitivity and specificity in differentiating IgG4-related AIP from PC, and the diagnostic effect was good. It had a high correlation with serum IgG4 levels in patients and could be considered for combined application in clinical diagnosis. However, the sample size was small, and the source was single. Only some MRI characteristics of the patients were analyzed to calculate the diagnostic performance indicators of a single MRI. Therefore, more patient samples need to be re-included in the subsequent study to increase the comparative analysis with MRI and further analyze the application value of MRI. In conclusion, the result provides a reference for the clinical diagnosis.

References

- Zheng YK, Gu NY, Wu J. A case of IgG4-related retroperitoneal fibrosis with multiple involvement. *Cell Mol Biol* 2017; 63(8): 67-70.
- Zhang YJ, Zheng JX, Wang LB. The value of serum IgG4 level in the differential diagnosis of IgG4-related hepatobiliary diseases and other hepatobiliary diseases. *Acta Medica Mediterranea* 2019; 35(2): 883-885.
- Marco Lanzillotta, Gaia Mancuso, Emanuel Della-Torre. Advances in the diagnosis and management of IgG4 related disease. *BMJ* 2020 Jun 16; 369: m1067.
- John H Stone, Yoh Zen, Vikram Deshpande. IgG4-related disease. *N Engl J Med* 2012 Feb 9; 366(6): 539-51.
- Kosuke Minaga, Tomohiro Watanabe, Hobyung Chung, et al. Autoimmune hepatitis and IgG4-related disease. *World J Gastroenterol* 2019 May 21; 25(19): 2308-2314.
- Inga Koneczny. Update on IgG4-mediated autoimmune diseases: New insights and new family members. *Autoimmun Rev* 2020 Oct; 19(10): 102646.
- Terumi Kamisawa, Kazuichi Okazaki. Diagnosis and Treatment of IgG4-Related Disease. *Curr Top Microbiol Immunol* 2017; 401: 19-33.
- Marinos C Dalakas. IgG4-Mediated Neurologic Autoimmunities: Understanding the Pathogenicity of IgG4, Ineffectiveness of IVIg, and Long-Lasting Benefits of Anti-B Cell Therapies. *Neurol Neuroimmunol Neuroinflamm* 2021 Nov 29; 9(1): e1116.
- Steven O Stapel, Ricardo Asero, Barbara Ballmer-Weber, et al. Testing for IgG4 against foods is not recommended as a diagnostic tool: EAACI Task Force Report. *Allergy* 2008 Jul; 63(7): 793-6.
- Yu JF, Song YP, Tian WZ. How to select IgG subclasses in developing anti-tumor therapeutic antibodies. *J Hematol Oncol* 2020 May 5; 13(1): 45.
- Maria Maslinska, Joanna Dmowska-Chalaba, Michal Jakubaszek. The Role of IgG4 in Autoimmunity and Rheumatic Diseases. *Front Immunol* 2022 Jan 25; 12: 787422.
- Zhang L, Liu TX, Luo J. IgG4-related spinal pachymeningitis. *Clin Rheumatol* 2016 Jun; 35(6): 1549-53.
- Dinesh Pradhan, Niharika Pattnaik, Russell Silowash, et al. IgG4-related kidney disease--A review. *Pathol Res Pract* 2015 Oct; 211(10): 707-11.
- Bohyun Kim, Jin Hee Kim, Jae Ho Byun, et al. IgG4-related kidney disease: MRI findings with emphasis on the usefulness of diffusion-weighted imaging. *Eur J Radiol* 2014 Jul; 83(7): 1057-1062.
- Ana Primitivo, Maria Helena Oliveira, Afonso Gonçalves. IgG4-related hepatic inflammatory pseudotumour: could MRI suggest the correct diagnosis? *BMJ Case Rep* 2021 Aug 23; 14(8): e244572.
- Yong Sub Song, Ho-Kyung Choung, Sun-Won Park, et al. Ocular adnexal IgG4-related disease: CT and MRI findings. *Br J Ophthalmol* 2013 Apr; 97(4): 412-8.
- Jordan Swensson, Temel Tirkes, Mark Tann, et al. Differentiating IgG4-related sclerosing cholangiopathy from cholangiocarcinoma using CT and MRI: experience from a tertiary referring center. *Abdom Radiol (NY)* 2019 Jun; 44(6): 2111-2115.
- Adam Sulewski, Dominik Sieroń, Karol Szyluk, et al. Avascular Necrosis Bone Complication after Active COVID-19 Infection: Preliminary Results. *Medicina (Kaunas)* 2021 Nov 30; 57(12): 1311.
- Grenacher L. Pankreatikohepatobiliäre Erkrankungen bei IgG4-assoziierten Autoimmunerkrankungen [Hepatopancreaticobiliary diseases in IgG4-associated autoimmune diseases]. *Radioologe* 2016 Dec; 56(12): 1052-1060. German.
- Mousa N Alrashdi. Immunoglobulin G4-related spinal pachymeningitis. *Saudi Med J* 2020 Jun; 41(6): 652-656.
- Motohisa Yamamoto, Hiroki Takahashi. IgG4-Related Disease in Organs Other than the Hepatobiliary-Pancreatic System. *Semin Liver Dis* 2016 Aug; 36(3): 274-82.
- Li YL, Luo B, Zhang J. Clinical relevance of serum immunoglobulin G4 in glucocorticoid therapy of Graves' ophthalmopathy. *Clin Endocrinol (Oxf)* 2021 Oct; 95(4): 657-667.
- Chae Dong Yim, Hyo Jung An, Seong Ki Ahn, et al. IgG4-related disease presenting as otogenic skull base osteomyelitis. *Auris Nasus Larynx* 2021 Feb; 48(1): 166-170.
- Isao Nishimori, Makoto Otsuki. Autoimmune pancreatitis and IgG4-associated sclerosing cholangitis. *Best Pract Res Clin Gastroenterol* 2009; 23(1): 11-23.
- Aigli G Vakrakou, Maria-Elephtheria Evangelopoulos, Georgios Boutzios, et al. Recurrent myelitis and asymptomatic hypophysitis in IgG4-related disease: case-based review. *Rheumatol Int* 2020 Feb; 40(2): 337-343.