

## The Intervention of Nano-targeted Drugs and Angioplasty in Treatment and Prevention of Vascular Restenosis and its Influence on Monocyte Chemotactic Protein-1 in Lower Extremity Angiopathy

Kun Ji<sup>#</sup>, Yaming Zhang<sup>#</sup>, Daojing Huang<sup>\*</sup>

Department of General Surgery, Tongji Hospital, School of Medicine, Tongji University Medicine School, 389 Xincun Road, Shanghai, 200065, China

<sup>#</sup>These authors contributed equally to this work as co-first author

### ARTICLE INFO

#### Original paper

#### Article history:

Received: November 03, 2021

Accepted: March 15, 2022

Published: March 31, 2022

#### Keywords:

Angioplasty, restenosis, lower extremity angiopathy, MCP-1, nano-targeted drugs, dexamethasone

### ABSTRACT

It was to make use of the nano-targeted drugs and angioplasty to treat and prevent vascular restenosis and analyze its influence on monocyte chemotactic protein 1 (MCP-1) of lower extremity angiopathy (LEA) patients since the patients with diabetic lower extremity angiopathy may be easily infected with vascular restenosis. In this article, the dexamethasone nano drugs were firstly prepared. After that, its related physical and chemical properties were tested, then dexamethasone nano drugs were applied in treating patients with diabetic lower extremity angiopathy. The results showed that the prepared dexamethasone nanoparticles' encapsulation rate attained 99.2%. The laser light scattering experiment manifested that the particle size of the nanoparticles ranged from 200 to 300nm, and the average particle size was 258nm. The MCP-1 of the control group, conventional group, and observation group were  $33.28 \pm 1.93 \mu\text{g/mL}$ ,  $78.27 \pm 9.73 \mu\text{g/mL}$ , and  $75.29 \pm 8.99 \mu\text{g/mL}$ , respectively. The MCP-1 values of the conventional and observation groups were higher than that of the control group, and there was a notable difference ( $P < 0.05$ ). After interventional treatment, the MCP-1 level of the conventional group was  $57.82 \pm 5.82 \mu\text{g/mL}$ , and that of the observation group was  $41.93 \pm 6.92 \mu\text{g/mL}$ . The MCP-1 level of the group which received the treatment of nano-targeted drugs and angioplasty was superior to that of the conventional group which received the traditional operation, and there was a notable difference ( $P < 0.05$ ). In conclusion, MCP-1 is one of the major causes of lower extremity angiopathy. The nano-targeted drugs and angioplasty can raise the expression level of MCP-1 in patients with lower extremity angiopathy. The experimental results had a high application value and the nano-targeted drugs and angioplasty can be promoted clinically.

DOI: <http://dx.doi.org/10.14715/cmb/2022.68.3.38>

Copyright: © 2022 by the C.M.B. Association. All rights reserved.



### Introduction

Cardiovascular disease (CVD) is a disease with higher morbidity and mortality rate in the world. The statistics of the World Health Organization showed that 20 million people die from cardiovascular disease every year, and account for about 30% of the total deaths in the world. The literature studies manifested that vascular inflammation is intimately related to atherosclerosis, myocardial infarction, vascular restenosis, intracranial aneurysm, stroke and peripheral artery disease, and the pathogenesis of various cardiovascular diseases (1). Vascular restenosis is easily occurred due to cardiovascular

diseases. At present, the pathogenesis of this disease is still unclear. Interventional angioplasty is the main method to treat cardiac vascular stenosis and obstruction. However, postoperative vascular restenosis is 35-40% (2). How to prevent postoperative vascular restenosis has turned into a critical research topic in interventional cardiology worldwide (3). The accumulated endocardium would invade the blood vessel lumen. The collagen will also be deposited and crusted in the damaged adventitia, resulting in the blood vessel's deformation and reducing the blood vessel's outer space (4). Since the decrease in volume of blood vessels lowers its ability

\*Corresponding author. E-mail: [jkl10808@163.com](mailto:jkl10808@163.com)  
Cellular and Molecular Biology, 2022, 68(3): 347-355

to contain the neointima, and the vessel lumen is further reduced to cause the restenosis of the blood vessel. The neointima formation and vascular deformation may occur in most patients with vascular restenosis.

The monocyte chemotactic protein 1 (MCP-1) is a research index that has been prevalent in recent years. It is a chemokine and is related to abnormal in-vivo coagulation function and the formation of thrombosis (5). The MCP-1 has multiple sulfhydryl and hydroxyl, which can be integrated with glycoprotein ligands to stimulate monocytes and macrophages to promote the generation of microvessels (6). Meanwhile, MCP-1 can also gather platelets, raise cell viability, and promote the hypercoagulate of partial cells to trigger the formation of a thrombus (7). The rise in the MCP-1 level will cause neutrophil-induced vascular endothelial cell damage, and enrich fibrin, to increase the probability of reoccurrence of thrombosis and ultimately induce vascular restenosis (8). Diabetic lower extremity angiopathy is one of the complications that severely threaten middle-aged and elderly diabetic patients (9). When the disease develops to a certain degree, the varying degrees of vascular stenosis and occlusion may occur in the patient and lead to the insufficient blood supply to the lower limbs and feet, causing foot infection, ulcer formation, damage to deep tissues of the foot, and severe amputation, and even endanger life.

At present, nanoparticles-based targeted therapy is regarded as a promising method for treating cardiovascular diseases. Vascular inflammation can be detected or diagnosed through various therapeutic drugs and visual imaging delivered (10). A variety of nanoparticles have been developed into a targeted carrier for treating atherosclerosis, myocardial infarction, heart failure, severe limb ischemia, and vascular restenosis. In these examples, the polymer lipid nanoparticles, inorganic nanoparticles, metal nanoparticles and hybrid nanoparticles are used to deliver therapeutic drugs. The nanoparticles can also be employed to improve the orientation efficiency of blood vessels by means of adjusting their physical properties, changing molecular groups, or functionalizing the special cell membrane (11).

In conclusion, the topic of this study was to analyze the clinical effects of nano-targeted drugs and angioplasty in the treatment of diabetic lower

extremity angiopathy and its influence on MCP-1 to provide the reference for subsequent clinical studies.

## Materials and Methods

### General information on patients

Fifty subjects were included in this study, including 10 healthy people and 40 type-2 diabetes patients. The blank control group was made of 10 healthy people, while the diabetes group included 20 type-2 diabetes patients who received the traditional surgical treatment (angioplasty), which was denoted as the conventional group and 20 type-2 diabetes patients who received the treatment with targeted nano-pharmaceuticals and angioplasty, which was denoted as the observation group.

Inclusion standard: it met the diagnostic criteria for diabetes of the World Health Organization (2016) (12). Diabetes with lower extremity angiopathy: the typical clinical manifestations, signs, and diagnosis of color Doppler ultrasound, age, and gender of each group were consistent. Before the experiment, all the subjects were informed and reached an agreement. Exclusion standard: the patients who had a smoking history, and the patients who suffered from diabetic ketosis, peripheral vascular disease or peripheral vascular embolism, infectious diseases, and patients who used inflammatory inhibitors. The research topic was approved by the Ethics Committee of Tongji Hospital, School of Medicine, and all the participants had already known the content of this study and signed an informed consent form for the operation.

### Treatment method

In the fasting condition in the morning, 5 mL of venous blood was drawn from 40 patients who had type 2 diabetes with lower extremity angiopathy and the normal control group, respectively. One tube of venous blood was placed at room temperature for 30 minutes and centrifuged at high speed for 10 minutes after blood coagulation. The serum was isolated and stored in a refrigerator at  $-78^{\circ}\text{C}$  for detection of MCP-1. The general biochemical indicators of another tube were detected in time.

Before the patients received the operation, their blood glucose level was controlled, microcirculation was improved, and the antiplatelet drugs were administered to the patients; the location and degree of arteriostenosis were determined using the color

Doppler ultrasound or CT angiography, and magnetic resonance angiography (MRA) for lower extremity artery. The patients underwent the femoral artery puncture under partial or general anesthesia, and then received the systematical reintubation after a successful puncture (13). Digital subtraction angiography (DSA) was adopted to segment the distal angiography of the affected limb. Under fluoroscopy, saccules with different diameters were used to expand the lesion area, 6-8 saccules were employed to expand the surface of the femur, and the deep saccules with a diameter of less than 4 mm were used to expand the lower leg artery and inferior lower leg artery. Each expansion lasted for about 3 minutes and was continued 2-3 times. When the expansion effect was not met, the self-expandable stent was applied as per the patient's condition and pathological changes.

#### Preparation of dexamethasone nanoparticles

In this experiment, the dexamethasone nanoparticles were prepared through the phacoemulsification solvent evaporation process (14). Specific method: in a methylene chloride condition, 500 mg of PLGA (polylactic acid-polyglycolic acid copolymer) and dexamethasone acetate powder were dissolved in 10 ml of acetone. Two kinds of organic solvents were mixed uniformly and filled into 40 mL of polyvinyl alcohol (PVA) (2%) or aqueous solution, and underwent ultrasonic treatment for 10 minutes in an ice bath and were placed at normal pressure for 12 hours. After 2-hour pressure reduction, the organic solvent was removed from organic solvents, which were ultracentrifuged at 23000 rpm for about 20 minutes, to collect the nanoparticles. The Polyvinyl Acetate Bond on the surface of the nanoparticles was washed away using distilled water, and the nanoparticles were frozen for 48 hours in freezing conditions. The preparation process was completed. The recovery rate of the prepared nanoparticles was the ratio of the weight of the nanoparticles finally obtained to the sum of the amount of dexamethasone added (Figure 1).

#### Detection of performance of nano-drug

1) The characterization of nanoparticles, particle size and distribution of nanoparticles were detected with the laser scattering experiments. The photon correlation spectrometer (purchased from PSC US),

photometer, laser, and other instruments were used. The distilled water with a suitable amount of suspension nanoparticles was filtered through 0.3µm filter membrane, and transferred into a clean measuring bottle, and went through the laser scattering at 25°C. A small amount of nano-particle freeze-dried product was laid on the sticky surface of tin foil, and its surface was mentally sprayed, the characterization of the particles was observed through a scanning electron microscope.

2) The drug content in nano-drug-loaded particles was measured. 1 milligram of prepared nanoparticles was taken as samples and dissolved in chloroform, and methanol was added. The precipitated polymer was centrifuged at 3000 rpm for 30 minutes. The content of dexamethasone in the supernatant was directly measured using high-pressure liquid chromatography. In the following equation, Q represents the actual measured drug loading rate, D indicates the theoretical drug loading rate, H represents the measured volume of dexamethasone, and P indicates the sampling volume of nanoparticles.

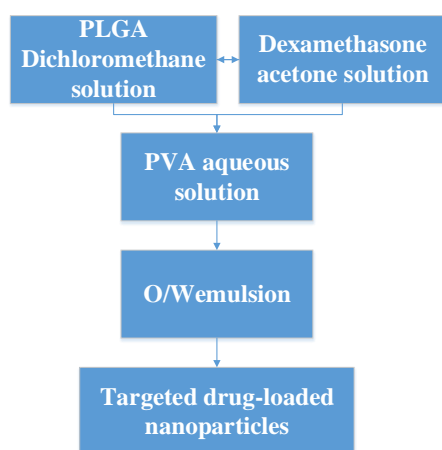
$$\text{Encapsulation rate} = \frac{Q}{D} * 100\% \quad [1]$$

$$\text{Drug loading rate} = \frac{H}{P} * 100\% \quad [2]$$

3) Linear relationship: the dexamethasone was accurately weighed and stored in the prepared flask and was dissolved with a little methanol, to equilibrate the mobile phase and form 1000µg/mL standby solution. 1mL of the standby solution was accurately absorbed, and filled into 10mL of mobile phase, and diluted to a standard solution with a concentration of 100µg/mL, then diluted into standard solution with a series of concentrations of 5, 15, 30, 50 µg/mL at a mobile phase ratio. 15g sample was injected and diluted at a mobile phase ratio, and the peak value and area of the chromatogram was recorded.

4) In vitro drug release: in vitro release experiments of dexamethasone nanoparticles were conducted in a double-chamber dialysis cell separated through a microporous membrane (15). An appropriate number of samples were filled into 5 ml of phosphate buffer solution. The suspension liquid was transferred to one side of the double-chamber dialysis cell, which is a release device to separate the receiving side with a filter membrane. Two samples were placed on a

shaking table at 200 rpm and 40°C for the release experiment. The buffer solution in the receiving tank was replaced with a new buffer at regular intervals, while the fresh buffer was replaced with a new buffer solution. The absorption value of the sample collected from the opposite side was measured using an ultraviolet spectrophotometer, and its concentration was identical to that of dexamethasone according to the standard curve. The calculation equation for the release was concluded and the cumulative release curve was drawn.



**Figure 1.** The schematic diagram for preparation of dexamethasone nano drug-loaded particles

### Detection of MCP-1 level in serum

The quantitative double-antibody sandwich ELISA method was adopted here, and the MCP-1 ELISA kit was bought from Shanghai Westang Biotechnology Co., Ltd. The experimental procedures shall comply with the instructions in the ELISA kit.

### Postoperative observation

The patient had to rest in bed for about 12 hours after the operation and received a subcutaneous injection of low molecular heparin for a week. The patient’s coagulation function, involving subcutaneous hematuria, hematuria, blood spots, and melena, should be carefully observed. If the patient’s partial activated thromboplastin time value was lower or identical to 2.5 times the normal value, it was regarded as save. After the patient was discharged from the hospital, he was orally administered 60 mg of Plavix every day for about five months. He also took 80 mg of aspirin daily and received regular detection of coagulation function. The dosage was

adjusted according to the improvement of the coagulation function.

### Evaluation index of therapeutic effect

The angiographic manifestations were observed; the successful operation standard was that at least one occlusive blood vessel was opened, the postoperative hemadostenosis was less than 30%, and some blood flow to the foot directly; the therapeutic effect was evaluated based on the Wagner’s grading (16): if the lesion had no obvious improvement or deterioration, the therapeutic effect was deemed as ineffective, if 1 grade was reduced, the therapeutic effect was regarded as effective; if 2 grades were reduced, the therapeutic effect was remarkably effective; the complications were also observed.

### Statistical method

The SPSS19.0 statistical software was used to process data herein, and the mean value of measurement data  $\pm$  the standard deviation was expressed as  $\bar{x} \pm s$ , the enumeration data was expressed by the percentage (%), verified by t and  $\chi^2$ . The treatment success rate, second operation rate, and complications of different groups were verified by variance.  $P < 0.05$  indicated the statistical significance of differences.

### Results and discussion

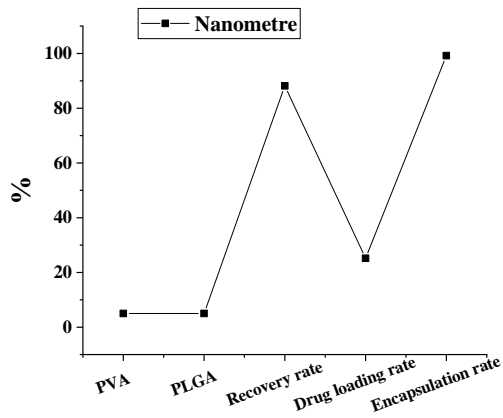
#### Characterization of dexamethasone nanoparticles

Figures 2 and 3 showed that PLGA aqueous solution with the concentration of 2% and PVA aqueous solution with the concentration of 2%, and theoretical drug loading rate were used in this experiment to prepare the nanoparticles, and its maximum encapsulation rate could be attained to 99.2%. The laser scattering experiment showed that the particle size of nano-particles ranged from 200 to 300nm and the average particle size was 258nm.


#### Drug release in vitro of nanoparticles

Figure 4 shows the cumulative drug release process in vitro of dexamethasone nano pharmacy. The release trends for nanoparticles in two kinds of release solutions are relatively consistent. In the early 10 days, 40.17% was released from the release solution with pH 6.0; in the early 20 hours, 33.67% was released from the release solution with pH 7.2. The in-

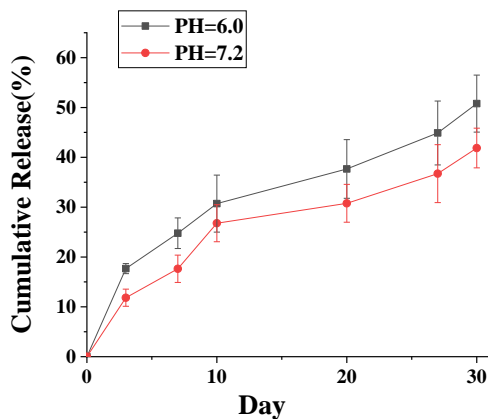
in vitro release of dexamethasone presented no obvious linear rising trend and started from 0 and lasted for 30 days. As the time is prolonged, the release speed becomes gradually slower.



**Figure 2.** Analysis of properties of dexamethasone nanoparticles



**Figure 3.** Dexamethasone nanoparticles under an electron microscope. (a) represents the micrograph with the size of  $\times 100$ ; (b) indicates the micrograph with the size of  $\times 400$

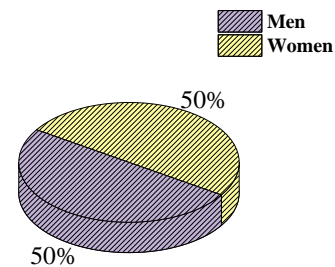


**Figure 4.** In-vitro drug release of dexamethasone nano pharmacy

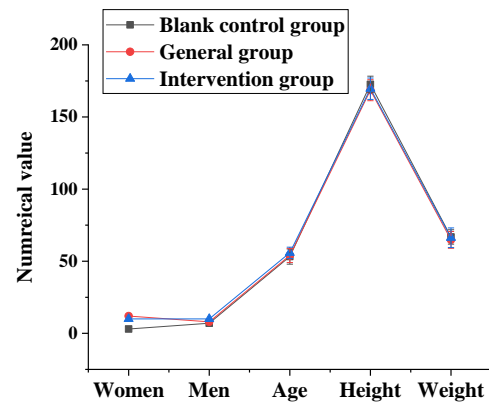
### Comparison of general information on patients

Figure 5 shows that 50 subjects were included in the study, including 25 male subjects and 25 female subjects. The blank control group was 10 healthy subjects, including 7 men and 3 women. In this group,

the average age was  $53.22 \pm 5.27$  years old, and the average height was  $172.6 \pm 5.67$ , and the average weight was  $66.83 \pm 4.98$  kg. Another 20 patients who suffered from type 2 diabetic lower extremity angiopathy received the conventional treatment, including 8 male patients and 12 female patients. In this group, the average age was  $54.01 \pm 4.89$  years old, their average height was  $168.6 \pm 7.28$ , and their average weight was  $64.82 \pm 5.83$  kg; the remaining 20 patients who suffered from type 2 diabetic lower extremity angiopathy received the interventional therapy of nano-targeted drugs and angioplasty, including 10 male patients and 10 female patients. In this group, the average age was  $55.83 \pm 3.91$  years old, their average height was  $169.6 \pm 7.39$ , and their average weight was  $66.32 \pm 6.82$  kg. There was no statistical difference in comparison between the three groups ( $P < 0.05$ ) (Figure 6).



**Figure 5.** Distribution of female and male subjects

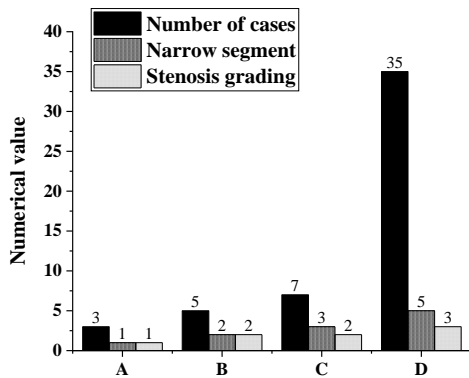


**Figure 6.** Comparison of general information on subjects

### Manifestations of CTA

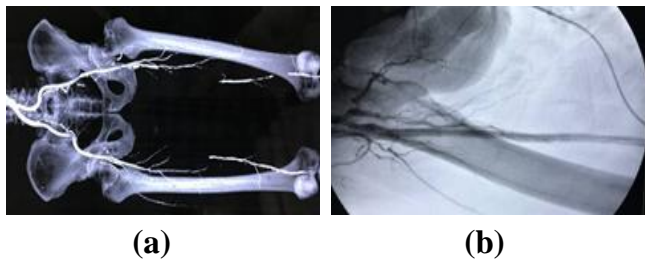
Figure 7 shows that, among 40 patients with type 2 diabetes, 3 patients got femoral artery disease with the grade-1 stenosis, 5 patients had popliteal artery disease and 7 patients had carotid artery disease with grade-2 stenosis; 35 patients got mixed arterial lesions, with grade-3 stenosis. The CTA results showed that all patients suffered from vascular

disease, and diffuse, multi-segmental, and severe vascular occlusion occurred to the involved vessels (Figure 8).



**Figure 7.** Analysis of DSA contrast of patients with type 2 diabetic lower extremity angiopathy before treatment. A represents the femoral artery; B indicates the popliteal artery; C is the carotid artery; D stands for the mixed artery.

In the grading of stenosis, the stenosis degree of less than 50% is marked as 0 points, the stenosis degree of 50%-70% is scored as 1 point, the stenosis degree of more than 75% is recorded as 2 points, and the lumen which is completely occluded is marked as 3 points.

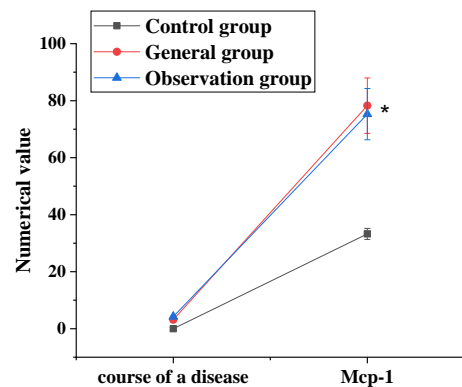


**Figure 8.** Preoperative CT shows multi-segment occlusion of femoral arteries of double lower extremities. (a) the right femoral artery occlusion was longer. (b) After the treatment of nano drugs and angioplasty, the imaging showed that the blood circulation of the right femoral artery was smooth

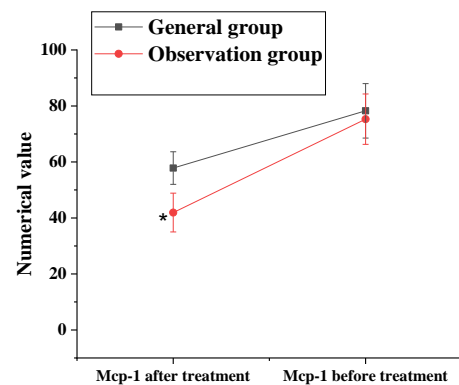
### Comparison of clinical test results of patients

Figure 9 shows the comparison of the MCP-1 level of three groups of subjects before/after treatment. Before treatment, the pathogenesis of three groups of patients was compared, which had no obvious disparity and no statistical significance ( $P < 0.05$ ). The MCP-1 of the control group, conventional group, and observation group were  $33.28 \pm 1.93 \mu\text{g/mL}$ ,  $78.27 \pm 9.73 \mu\text{g/mL}$ , and  $75.29 \pm 8.99 \mu\text{g/mL}$ , respectively. The MCP-1 values of the conventional group and the observation group were apparently higher than that of the control group, of which the difference had a statistical significance ( $P < 0.05$ ). The

slight difference between the conventional and observation group had no statistical significance ( $P > 0.05$ ); after interventional treatment, the MCP-1 level of the conventional group was  $57.82 \pm 5.82 \mu\text{g/mL}$ , and that of the observation group was  $41.93 \pm 6.92 \mu\text{g/mL}$ . After the treatment, the MCP-1 level of the group which received the treatment of nano-targeted drugs and angioplasty was superior to that of the conventional group which received the traditional operation, which had a statistical difference in comparison of groups ( $P < 0.05$ ).



(a)



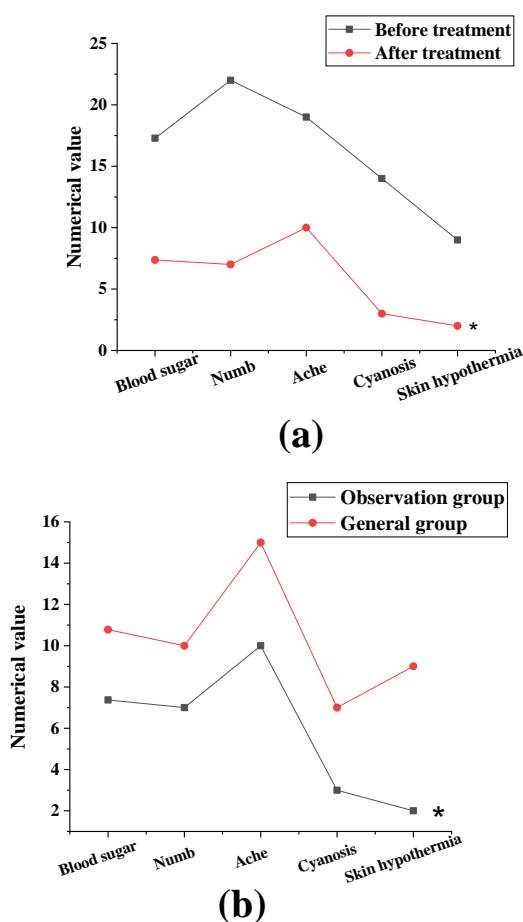
(b)

**Figure 9.** Comparison of pathogenesis and MCP-1 of patients before treatment. indicates the statistical difference between the observation group and other groups ( $P < 0.05$ )

### Comparison of clinical symptoms of patients before/after treatment

Figure 10 shows the comparison of clinical symptoms of the observation group before/after treatment. Before the treatment, the patient's blood glucose index was 17.28, 22 patients had numbness, 19 patients got pains, 14 patients had cyanosis, and 9 patients suffered from skin hypothermia; after the treatment, the patient's blood glucose index was about

7.37. 7 patients had numbness. 10 patients got pains, 3 patients had cyanosis, and 2 patients got skin hypothermia symptoms, which had a statistical difference in comparison of groups ( $P<0.05$ ); The Figure 10 (b) showed the comparison of clinical symptoms of the conventional group and observation group after two-week treatment. The figure manifested that the clinical symptoms of the observation group were apparently lower than that of the conventional group, which had a statistical difference between the two ( $P<0.05$ ).



**Figure 10.** Comparison of clinical symptoms of patients before/after treatment. (a) Comparison of clinical symptoms of the observation group before/after treatment, (b) Comparison of clinical symptoms of the observation group and control group after two-week treatment. (a) \* indicates the statistical difference in comparison of clinical symptoms after treatment ( $P<0.05$ ), (b) \* represents the statistical difference in comparison between the observation group and control group

Lower extremity angiopathy is the major cause of diabetic foot (DF), which is commonly seen in middle-aged and elderly people. The studies

manifested that, about 20% of diabetic patients suffered from lower extremity angiopathy. The interventional therapy of angioplasty can maintain the patency of the blood vessels with lesions, and the drug treatment can also improve the expression level of in-vivo MCP-1 in the patient. In this article, the dexamethasone nano drugs were firstly prepared. After that, its related physical and chemical properties were tested, then dexamethasone nano drugs were applied in the treatment of vascular restenosis, meanwhile, and its influence on MCP-1 level in lower extremity angiopathy was analyzed on this basis. The results showed that the encapsulation rate of the prepared dexamethasone nanoparticles attained 99.2%. The laser light scattering experiment manifested that the particle size of the nanoparticles ranged from 200 to 300nm, and the average particle size was 258nm. The release trends for dexamethasone nanoparticles in two kinds of release solutions are relatively consistent. In the early 10 days, 40.17% was released from the release solution with pH 6.0, while, in the early 20 hours, 33.67% was released from the release solution with pH 7.2. The release of dexamethasone presented no obvious linear rising trend and started from 0 and lasted for 30 days. As the time is prolonged, the release speed becomes gradually slower. Nakamura et al. (2017) (17) pointed out in the study that the rat model was orally administered with nanoparticle-coated insulin, which can reduce hyperglycemia by about 50% in animals. However, insulin alone did not affect lowering blood glucose. This experiment showed that the dexamethasone nanoparticles prepared in this study have better physical and chemical properties and can be applied in the treatment of vascular restenosis.

Among 40 patients with type 2 diabetes, 3 patients got femoral artery disease with grade-1 stenosis, 5 patients had popliteal artery disease and 7 patients had carotid artery disease with grade-2 stenosis; 35 patients got mixed arterial lesions with grade-3 stenosis. The CTA results showed that all patients were suffering from vascular disease, and diffuse, multi-segmental, and severe vascular occlusion occurred to the involved vessels. The MCP-1 of the control group, conventional group, and observation group were  $33.28\pm 1.93 \mu\text{g/mL}$ ,  $78.27\pm 9.73 \mu\text{g/mL}$ , and  $75.29\pm 8.99 \mu\text{g/mL}$ , respectively. The MCP-1 values of the conventional group and the observation

group were apparently higher than that of the control group, of which the difference had a statistical significance ( $P<0.05$ ). Queck et al. (2020) (18) highlighted in the rat model study that the MCP-1 might stimulate the proliferation and migration of vascular smooth muscle cells and make the monocytes adhering to the endothelium enter the vascular intima, to form foam cells, and lead to the vascular stenosis, vascular sclerosis, and other diseases. It indicated that the type-2 diabetes patients had higher expression level of MCP-1 in lower extremity angiopathy and prompted that the MCP-1 may be the important cause of diabetic lower extremity angiopathy; After interventional treatment, the MCP-1 level of the conventional group was  $57.82\pm 5.82$   $\mu\text{g/mL}$ , and that of the observation group was  $41.93\pm 6.92$   $\mu\text{g/mL}$ . The MCP-1 level of the group which received the treatment of nano-targeted drugs and angioplasty was obviously superior to that of the conventional group which received the traditional operation, which had a statistical difference in comparison of groups ( $P<0.05$ ); It is similar to the research conclusion of Rull et al. (2016) (19). The results manifested that the nano-targeted drugs and angioplasty have a certain effect on the treatment of vascular restenosis and can reduce the MCP-1 level in patients remarkably; before the treatment, the patient's blood glucose index was 17.28, 22 patients had numbness, 19 patients got pains, 14 patients had cyanosis, and 9 patients suffered from skin hypothermia; after the treatment, the patient's blood glucose index was about 7.37. 7 patients had numbness. 10 patients got pains, 3 patients had cyanosis, and 2 patients got skin hypothermia symptoms, which had a statistical difference in comparison of groups ( $P<0.05$ ); The figure showed that, after two-week treatment, the clinical symptoms of the observation group were apparently lower than that of the conventional group, which had a statistical difference between the two ( $P<0.05$ ).

## Conclusions

In this article, the dexamethasone nano drugs were firstly prepared. After that, its related physical and chemical properties were tested, then dexamethasone nano drugs were applied in the treatment of patients with diabetic lower extremity angiopathy. The results showed that the interventional therapy of nano-

targeted drugs and angioplasty for lower extremity angiopathy could remarkably reduce the MCP-1 level in patients. The MCP-1 is one of the main causes to lower extremity angiopathy. The study provided the reference for the treatment plan for cardiovascular disease. However, the study still has many disadvantages. This article lacks the controlled trials of other treatment plans during the experiment. Therefore, the experiment results possess definite subjectivity. The article has less samples, and the experiment results are not widely applicable. The comparative experiments will be further conducted in the future to understand the properties and applications of nano drugs and get more perfect results and theoretical basis. In conclusion, the nano-targeted drugs and angioplasty can improve the expression level of MCP-1 in patients with vascular restenosis and lower extremity angiopathy. The experimental results had a high application value and can be promoted in clinical application.

## Acknowledgments

Not applicable.

## Interest conflict

The authors declare that they have no conflict of interest.

## References

1. Raikou V.D., Kyriaki D. Factors related to peripheral arterial disease in patients undergoing hemodialysis: the potential role of monocyte chemoattractant protein-1. *Hypertens Res.* 2019 Oct, 42(10): pp. 1528-1535.
2. Hoogeveen R.C., Morrison A., Boerwinkle E., et al. Plasma MCP-1 level and risk for peripheral arterial disease and incident coronary heart disease: Atherosclerosis Risk in Communities study. *Atherosclerosis.* 2015 Dec, 183(2): pp. 301-7.
3. Nylaende M., Kroese A., Strandén E., et al. Markers of vascular inflammation are associated with the extent of atherosclerosis assessed as angiographic score and treadmill walking distances in patients with peripheral arterial occlusive disease. *Vasc Med.* 2016 Feb, 11(1): pp. 21-8.
4. Nakamura T., Satoh K., Fukuda T., et al. Pentosan polysulfate treatment ameliorates motor function with increased serum soluble vascular cell adhesion molecule-1 in HTLV-1-associated neurologic disease. *J Neurovirol.* 2018 Jun, 20(3): pp. 269-77.
5. Patel M.R., Conte M.S., Cutlip D.E., et al. Evaluation and treatment of patients with lower extremity peripheral artery disease: consensus definitions from



- Peripheral Academic Research Consortium (PARC). *J Am Coll Cardiol*. 2015 Mar 10, 65(9): pp. 931-41.
6. Kayssi A., Al-Atassi T., Oreopoulos G., et al. Drug-eluting balloon angioplasty versus uncoated balloon angioplasty for peripheral arterial disease of the lower limbs. *Cochrane Database Syst Rev*. 2016 Aug 4, (8): pp. CD011319.
  7. Schoenweger P., Miller F., Cromwell D.A., et al. Outcomes of Lower Limb Angioplasty Vary by Area Deprivation in England. *Eur J Vasc Endovasc Surg*. 2020 Nov, 60(5): pp. 784-785.
  8. Hamid A., Lamirault G., Gouëffic Y., et al. Duration of sick leave after same-day discharge for lower extremity arterial disease and varicose vein interventions in active population of French patients, 2013-2016: observational study. *BMJ Open*. 2020 Jun 28, 10(6): pp. e034713.
  9. Kim W., Quesada R., Scherthaner M.B., et al. Effects of Percutaneous Transluminal Angioplasty on Diastolic Function in Patients With Chronic Occlusion of Lower-Extremity Artery. *J Invasive Cardiol*. 2016 Dec, 28(12): pp. 498-504.
  10. Fan J., Liu B., Long Y., et al. Sequentially-targeted biomimetic nano drug system for triple-negative breast cancer ablation and lung metastasis inhibition. *Acta Biomater*. 2020 Sep 1, 113: pp. 554-569.
  11. Li M., Li S., Zhou H., et al. Chemotaxis-driven delivery of nano-pathogenoids for complete eradication of tumors post-phototherapy. *Nat Commun*. 2020 Feb 28, 11(1): pp.1126.
  12. Wang Y., Li L., Zhao W., et al. Targeted Therapy of Atherosclerosis by a Broad-Spectrum Reactive Oxygen Species Scavenging Nanoparticle with Intrinsic Anti-inflammatory Activity. *ACS Nano*. 2018 Sep 25, 12(9): pp. 8943-8960.
  13. Liu J., Luo L., Xu F., et al. Cyclic RGD Peptide Targeting Coated Nano Drug Co-Delivery System for Therapeutic Use in Age-Related Macular Degeneration Disease. *Molecules*. 2020 Oct 23, 25(21): pp. 4897.
  14. Lai K., Li Y., Gong Y., et al. Triptolide-nanoliposome-APRPG, a novel sustained-release drug delivery system targeting vascular endothelial cells, enhances the inhibitory effects of triptolide on laser-induced choroidal neovascularization. *Biomed Pharmacother*. 2020 Nov, 131: pp. 110737.
  15. Hoogeveen R.C., Morrison A., Boerwinkle E., et al. Plasma MCP-1 level and risk for peripheral arterial disease and incident coronary heart disease: Atherosclerosis Risk in Communities study. *Atherosclerosis*. 2015 Dec, 183(2): pp. 301-7.
  16. Arnesen H., Seljeflot I. Markers of vascular inflammation are associated with the extent of atherosclerosis assessed as angiographic score and treadmill walking distances in patients with peripheral arterial occlusive disease. *Vasc Med*. 2017 Feb, 11(1): pp. 21-8.
  17. Nakamura T., Satoh K., Fukuda T., et al. Pentosan polysulfate treatment ameliorates motor function with increased serum soluble vascular cell adhesion molecule-1 in HTLV-1-associated neurologic disease. *J Neurovirol*. 2017 Jun, 20(3): pp. 269-77.
  18. Queck A., Bode H., Uschner F.E., et al. Systemic MCP-1 Levels Derive Mainly From Injured Liver and Are Associated With Complications in Cirrhosis. *Front Immunol*. 2020 Mar 11, 11: pp. 354.
  19. Rull A., Hernandez-Aguilera A., Fibla M., et al. Understanding the role of circulating chemokine (C-C motif) ligand 2 in patients with chronic ischemia threatening the lower extremities. *Vasc Med*. 2016 Dec, 19(6): pp. 442-51.