



Evaluation of sperm chromatin/DNA integrity, morphology, and Catsper expression on diabetic C57BL/6 mice

Elnaz Khordad¹, Mohammad Reza Nikravesh^{1*}, Mahdi Jalali¹, Alireza Fazel¹, Mojtaba Sankian², Fatemeh Alipour¹

¹Department of Anatomy and Cellular Biology, Faculty of Medicine, Mashhad University of Medical Sciences, Mashhad, Iran

²Bou-Ali Research Institute, Immunology Research Center, Mashhad University of Medical Sciences, Mashhad, Iran

ARTICLE INFO

Original paper

Article history:

Received: July 24, 2021

Accepted: January 10, 2022

Published: February 28, 2022

Keywords:

Diabetes, sperm, chromatin, Catsper, mouse

ABSTRACT

Diabetes is associated with reproductive impairment in the male reproductive system and causes complications such as decreased libido, fertility, spermatogenesis, sperm motility, and morphology. High levels of blood sugar may affect sperm quality and reduce the potential for male fertility. Increased levels of sperm DNA damage are often associated with reduced count and motility or abnormal morphology. This experimental study was conducted at Mashhad University of Medical Sciences. In this work, 40 mice (C57BL/6) were divided randomly into 4 groups: 1) Control, 2) Diabetic, 3) Diabetic + Insulin, and 4) Sham. After 35 days, the right epididymis of all specimens was used for Real-Time PCR and the left epididymis for evaluation of sperm parameters using Aniline blue, Toluidine blue, Papanicolaou, and immunohistochemical study. Also, testes were applied for immunohistochemical, TUNEL studies, and biochemical assay. Results of this study showed that chromatin integrity, morphology, cation channels of sperm (Catsper) expression, and biochemical factors level were significantly changed in diabetic mice in comparison to other groups ($P < 0.05$) and treatment with insulin improved these parameters. Our findings showed that the sperm parameters such as DNA integrity, morphology, and Catsper expression change in diabetic mice.

DOI: <http://dx.doi.org/10.14715/cmb/2022.68.2.2>

Copyright: © 2022 by the C.M.B. Association. All rights reserved.



Introduction

Diabetes mellitus is known as one of the important common metabolic disorders. The disease is spreading throughout the world and is estimated to increase to 592 million people by the year 2035. Diabetes is associated with much functional and structural impairment of the male reproductive system. Diabetes has significant disturbances in libido, fertility, testosterone levels, spermatogenesis, sperm motility, and morphology, and semen volume (1-4). Some studies indicated that a high level of blood sugar might affect sperm quality and reduce the potential for male fertility. Also, it has been revealed that diabetes is accompanied by decreased semen volume and reduced vitality and motility of the spermatozoa, but the viscosity of the seminal does not change (5). Sperm motility is one of the most fundamental parameters in assessing fertilizing ability (6-8). Appropriate motility is essential for sperm to reach the female reproductive system. Since spermatozoa are released from the testis,

the system is not able to fertilize. Full potential biological can be achieved following the process of capacitation. The first event in the capacitation is increasing intracellular calcium and bicarbonate (9). Regulation of intracellular calcium concentration is important for spermatogenesis and also vital for the maturation of sperm, acrosome reaction, sperm mobility, and capacitation (10-13). A family of cation channels of sperm (CatSper) contains special CatSper 1 to 4 (14) and additional auxiliary subunits including CatSper β , CatSper γ , and CatSper δ , which are exclusively localized to the membrane of the sperm (15-17). CatSper1, as one of the genes controlling spermatogenesis, has a key role in the control of sperm motility and is essential for male fertility, ovum penetration, and the entry of calcium ions (18). CatSper2 is essential for the sperm motility and also necessary for successful fertilization (14).

The evaluation of sperm nuclear chromatin is a new procedure for the microscopic appraisalment of sperm

*Corresponding author. E-mail: Nikraveshmr@mums.ac.ir
Cellular and Molecular Biology, 2022, 68(2): 8-18

for the investigation of male fertility (5). There is a negative correlation between sperm nuclear DNA integrity and outcomes of reproduction. Furthermore, sperm chromatin condensation plays a major role in male fertility. Increased levels of sperm DNA damage often is associated with reduced count and motility or abnormal morphology (19-21). The compaction of sperm chromatin structure changes during the spermatogenesis process, mainly by replacing histones with protamines. Any defect in the expression of sperm nucleoprotein leads to abnormal sperm nuclear structure and may affect male fertility. The disulfide bonds between the protamine molecules are necessary for sperm nuclear compaction. Such nuclear compaction protects the sperm genome from damages including oxidative stress. Hyperglycemia by producing oxidative stress has an important role in the progress of diabetic morbidity. Oxidative stress is the main factor in male infertility that changes the cell function like sperm motility and increases DNA damage. Few studies indicate the effects of DM on sperm DNA integrity (4, 5, 22). Therefore, the present work was designed to examine the possible relationship between diabetes and sperm chromatin/DNA integrity, sperm morphology, and CatSper expression in the mouse.

Materials and methods

Animals

This experimental study was performed at Mashhad University of Medical Sciences, a total of 40 male C57BL/6 mice (two months old) with 20-25 gr body weight were purchased from Pasteur Institute, Tehran, Iran. The study was done in accordance with the rules provided by the National Institute of Health Guide for the Care and Use of Laboratory Animals (NIH Publications No. 80-23, revised 1978) and approved by the Ethical Committee at Mashhad University of Medical Sciences, Mashhad, Iran. The mice were housed in standard animal cages and kept under standard laboratory conditions (12 h light and dark cycles, at 22-24°C temperatures, and 50% relative humidity). Animals were given free access to food and drinking water during the study.

Study design

After adaptation to the animal house, mice were randomly divided into 4 groups: 1) Control group

without any intervention, 2) Diabetic group: treated mice with 50 mg/kg STZ, 3) Diabetic + Insulin group: treated mice with STZ and insulin (1.5 U of LANSULIN 70/30), and 4) Sham group that received citrate buffer. At the end of the exposure period, animals were anesthetized and sacrificed by cervical dislocation and epididymis was removed from each group. The right epididymis was stored at -70°C for RNA extraction and the left epididymis for sperm preparation. Testes were washed in normal saline and fixed in 10% formalin for immunohistochemical, TUNEL studies and biochemical assay. After fixation, the specimens were dehydrated with an ascending ethanol series, cleared with xylene, and embedded in paraffin. The blocks were cut into 5-µm thick sections.

Streptozotocin treatment and induction of diabetes

Diabetes in mice was induced by intraperitoneal injection of STZ at a dose of 50 mg/kg (freshly dissolved in 0.01 mol/L (pH: 4.5) sodium citrate buffer) for 5 consecutive days (23). The blood glucose levels were taken from the tail vein and measured using a blood glucometer (Easy Gluco, Infopia, Korea) 72 h after injection of STZ. The mice with blood glucose concentrations of 250 mg/dl and higher were considered as diabetic.

Apoptotic cell detection

TUNEL immunohistochemical method was conducted for apoptosis analysis. DNA fragmentations in apoptotic cell nuclei were revealed using TUNEL reaction by means of TUNEL Kit (Roche, Germany), in this technique. For this purpose, tissue sections were deparaffinized with the xylene, rehydrated by reducing the concentrations of ethanol, and rinsed in 0.1 M PBS for 10 min. Then, they were treated with 20 µg/ml proteinase K (Roche, Germany) for 20 min at room temperature. To inactivate endogenous peroxidase, the specimens were treated with 3% H₂O₂ in methanol for 10 min. After washing with PBS, the samples were incubated in the labeling reaction mixture containing terminal deoxynucleotidyl transferase and the deoxynucleotide mixture at 4°C overnight. All the sections were rinsed in PBS and incubated with horseradish peroxidase (1:500) after the incubation, for 30 min at room temperature. Then, the sections were washed extensively with PBS for 3 min and treated with diaminobenzidine (Sigma, USA) solution (30 mg

diaminobenzidine and 200- μ l H₂O₂/100 ml PBS) for 15 min in dark at room temperature. All the sections were counterstained with hematoxylin for 1 min, after washing under running water. Ultimately, the sections were dehydrated in increasing graded ethanol, cleared in xylene, and mounted with a coverslip. Apoptotic nuclei were recognized by the presence of dark brown staining in this method.

Quantification of apoptotic cells

Using a light microscope with a 40 \times objective lens (UPlan FI, Japan), the sections were scanned and photographed and using a high-resolution camera (BX51, Japan) the images were transferred to a computer. To count TUNEL positive cells per unit area in testes tissue, Image J software was used. The mean number of TUNEL positive cells (N_A) in testes was calculated based on the following formula:

$$N_A = \frac{\sum Q}{a/f \cdot \sum P}$$

In this formula, “ $\sum Q$ ” is the sum of counted particles that appeared in the sections, “ a/f ” is the area associated with each frame, and “ $\sum P$ ” is the sum of frame associated points hitting space (24, 25).

Epididymal sperm preparation

The epididymis was cut into small pieces by a scalpel and the pieces were placed in 1 ml at 37°C normal saline and incubated in a 5% CO₂ incubator for 15 min and allowed sperm to swim out into the dish. To evaluate sperm parameters, 10 μ l of sperm samples were pipetted onto a slide, air-dried and then fixed in methanol 70%. In order to assess sperm count, 10 μ L of sperm suspension was placed on a microscope slide, and ten fields were selected randomly in the sample from each animal to determine the sperm count (26).

Sperm chromatin/DNA integrity assessments

To evaluate the sperm DNA integrity, two different staining methods including Aniline blue (AB) and toluidine blue (TB) were applied. We used AB staining for assessment of the excessive presence of histones and TB staining for assessing the quality and the quantity of sperm nuclear chromatin condensation/DNA fragmentation via binding to phosphate groups of DNA strands (5, 27, 28).

Aniline blue (AB) staining

For this staining, samples were washed in distilled water for 2 min, followed by staining by 5% solution of AB (Merck, Germany) in acetic acid 4% with a pH of 3.5 for 5 min. Afterward, samples were rinsed with distilled water and dehydrated by alcohol 96 and 100, then cleared by xylene and mounted. The slides were examined by Olympus BX51 light microscope at 1000 \times magnification. The percentage of colorless sperm cells (AB⁻) and blue sperm cells (AB⁺) were obtained (28).

Toluidine blue (TB) staining

To do this staining, the sample was washed in distilled water for 2 min and then incubated in 0.1 N hydrochloric acid for 5 min at 4°C. Next, they were washed with distilled water for 3 min. Afterward, samples were stained with 0.05% TB in 50% citrate phosphate for 10 min, washed with distilled water and dehydrated by alcohol 96 and 100, and cleared by xylene and finally mounted. The samples were evaluated using Olympus BX51 light microscope at 1000 \times magnification. Metachromatic staining of sperm head with light blue (TB⁻) and dark blue (TB⁺) was considered (21).

Papanicolaou staining for Sperm morphology

The slides were washed with distilled water for 2 min and stained with Harris Hematoxylin for 5 min and then the slides were rinsed in running water for 3 min and distilled water for 1 min. In the next step, the slides were dipped in acid alcohol followed by washing in running water for 3 min. The slides were dipped in 96% alcohol I and II for 15 s. After that, samples were stained in OG6 for 5 min followed by 96% alcohol I and II for 15 s. Afterward, the slides were stained with EA 50 for 5 min followed by 96% alcohol I, II for 15 s and 100% alcohol for 1 min. Finally, the slides were cleared with xylene and mounted (29).

Immunohistochemistry study in epididymal smear and testis

To perform this technique, first, the prepared smear was washed in phosphate-buffered saline solution (PBS) (pH 7.4) for 15 min. The antigen retrieval was done by heating. Samples were placed in Tris/ Ethylene diamine tetraacetic acid (EDTA) pH 9.0 solutions for

20 min in a hot water bath. After washing with PBS for inhibiting the endogenous peroxidase activity, the samples were incubated in a solution of hydrogen peroxide 3% and methanol for 20 min. After this step, the samples were washed with PBS and incubated for 30 min in a blocking buffer. CatSper1 and 2 polyclonal primary antibodies (mouse antigoat CatSper antibodies (separately) were first diluted with 1:50 concentration, dropped on samples, and kept at 37°C for 2 h. The samples were washed with PBS and then incubated with the donkey anti-goat polyclonal secondary antibody (HRP conjugated IgG) at a concentration of 1:200 and temperature of 37°C for 2 h. After washing with PBS, samples were placed in a solution of substrate 3, 3-diaminobenzidine 0.03% (DAB) for 15 min. Following the washing process, the samples were treated in xylene and dehydrated in a graded ethanol series of 70-100%. Next, they were mounted with entellan. The samples were observed and studied under an Olympus BX51 light microscope at a 100× magnification, an objective lens (UPlan FI, Japan). The reaction was ranked by two persons as the following: weak (+), moderate (++), strong (+++), and highly strong (+++ +). Next, the sections were deparaffinized and dipped in descending grades of alcohol 70%, 90%, 95%, and 100% in the order of their appearance. Immunohistochemistry detection of Catsper 1 and Catsper 2 proteins in testis tissues was performed according to the procedure mentioned in (30, 31).

RNA extraction

Total RNA was isolated from epididymal tissue using the Total RNA Extraction Kit (Parstous, Iran) according to the manufacturer's recommendations. Briefly, 20 mg of tissue was lysed in 750 µl of RL solution and then 150µl Chloroform was added to the solution. In the next step, it was incubated at room temperature for 3 min and centrifuged for 12 min. 400 µl of the upper phase was transferred into a tube and an equal volume of ethanol 70% was added to the solution. The tube was centrifuged for 1 min at 4°C. Then, 700µl and 500µl PW were added and centrifuged for 2 min at 4°C. Finally, 50µl Diethyl pyrocarbonate (DEPC) was added and centrifuged for 1 min at 4°C. The purity and integrity of obtained RNA were checked by 260/280 nm ratio measurement and 1% agarose gel electrophoresis. Total RNA was kept at -70°C.

cDNA synthesis

cDNA was synthesized using a cDNA synthesis Kit (Parstous Company, Iran) in accordance with the manufacturer's instructions. The total RNA (0.5µl) was reverse transcribed with 1µl oligo (dt) and 8.5µl DEPC water. After that, the solution was incubated at 65°C for 5 min. The solution was immediately transferred to ice and then added 10µl reverse transcription (RT) premix (reaction volume =20 µl). The samples were incubated at 50°C for 60 min and then the transcriptase was stopped at 70°C for 10 min. Eventually, cDNA samples were stored at -70°C.

Real-time PCR

To assess gene expression, the real-time PCR method was done by SYBER Green/ROX master mix (Parstous Corporation, Iran) kit. All samples were tested in duplicate. The primer sets are described in Table 1. PCR master mix contains 10µl SYBR Green, 1µl of each gene-specific primer (forward and reverse), 7.1µl of distilled water, 0.4µl ROX, and 0.5µl of cDNA (volume of reaction = 20 µl in each tube). The PCR program was as the following: keeping at 94°C for 10 min followed by 35 cycles (95°C for 30 s, 60°C for 1 min, and 72°C for 30 s). For internal control, GAPDH was used to determine the relative expression quantity of the target genes. Real-time data were calculated using the ratio formula (Ratio= 2^{-ΔΔCt}), where ΔΔCt = ΔCt (control sample) - ΔCt (target sample) (30).

Table 1. Primers used for real-time PCR

Gene	primer sequences	product size (bp)	Annealing Temperature (°C)
CatSper1	5'-ACC AGG TTG AGG AAG ATG AAG T-3' (R)	227	59
	5'-TTT ACC TGC CTC TTC CTC TTC T-3' (F)		
CatSper2	5'-ACC AAT GAT CCA AGG TGA AGA-3' (R)	261	59
	5'-GGG TGC TGA GGT CTC TCA AAC-3' (F)		
GAPDH	5'-CTGTAGCCATATTCATTGTCATACCA-3' (R)	385	59
	5'-AACTCCCATTCTCCACCTTTG-3' (F)		

GAPDH; Glyceraldehyde 3-phosphate dehydrogenase

Measurement of lipid peroxidation (MDA), Superoxide dismutase (SOD) and thiol

Lipid peroxidation level was measured by determining the MDA in the testicular samples by monitoring the creation of thiobarbituric acid-reactive substances (TBARS) and the production of a red-

colored complex, which involves a peak absorbance at 535 nm. Almost 2 ml thiobarbituric acid (TBA)/trichloroacetic acid (TCA)/hydrochloric acid (HCl) reagent was added to 1 ml homogenate and the solution was incubated for 40 min in a boiling water bath. The MDA concentration was calculated based on the explanation in (32).

Total thiol content was measured using DTNB (2, 2'-dinitro-5, 5'-dithiodibenzoic acid) reagent reacting with the SH groups and producing a yellow-colored complex with a peak absorbance at 412 nm. In summary, 1 ml Tris-EDTA (ethylene diamine tetraacetic acid) buffer (pH = 8.6) was added to 50 μ l testes homogenate in 1 ml cuvettes and the absorbance was read at 412 nm against Tris-EDTA buffer. Next, 20 μ l DTNB reagent (10mM in methanol) was added to the mixture and the absorbance was read again after 15 min incubation at room temperature. The absorbance of the DTNB reagent was also recited as a blank. Based on an equation previously described in (32). The total thiol concentration was calculated.

SOD activity was measured by the technique explained by Madesh and Balasubramanian (33). This process is a colorimetric assay based on the inhibition of superoxide-dependent reduction of the tetrazolium dye to its formazan by SOD and the generation of superoxide by pyrogallol autoxidation. The colorimetric alterations were measured at 570 nm. One unit of SOD activity was defined as the amount of enzyme leading to the 50% inhibition in the tetrazolium dye (MTT: (3-(4, 5-dimethylthiazol-2-yl) 2,5-diphenyltetrazolium bromide) reduction rate.

Statistical analysis

All the statistical analyses were conducted using the statistical package for social sciences (SPSS v.16) software. The results of immunohistochemistry staining were evaluated by Kruskal-Wallis nonparametric test followed by the Mann-Whitney test. Quantitate data were analyzed using one-way ANOVA followed by Tukey tests. A p-value of <0.05 was considered statistically significant.

Results and discussion

Apoptosis cell density

Apoptosis is a gene-regulated phenomenon that is characterized by unique morphological features such as chromatin condensation, nuclear shrinkage, and oligonucleosomal DNA fragmentation. These features

can be detected by means of the TUNEL method in which apoptotic nuclei are detected by the presence of dark brown staining. The results show a significant increase in apoptotic cells in germinal epithelium including spermatogonia, primary spermatocyte, and early spermatid in the Diabetic group compared with Control and Sham groups ($P < 0.001$). Comparison of apoptotic cells in the Diabetic + Insulin groups with the Diabetic group revealed a significant decrease in apoptotic cells ($P < 0.001$, Figures. 1 and 2) but no statistically significant difference between the Control, Sham, and Diabetic + Insulin with each other (Figures. 1 and 2).

The effect of diabetes on Chromatin quality

As shown in Table 2, the rates of immature spermatozoa with abnormal chromatin (AB^+) in the Diabetic group were significantly higher than Sham and Control groups with $p < 0.05$ (Figure. 3). The percentage of abnormal chromatin in the Diabetic + Insulin group in comparison to the Diabetic group decreased significantly ($p < 0.05$). There were no significant changes in the Diabetic + Insulin, Sham, and Control groups. The results of TB staining also showed a significant increase in abnormal spermatozoa in the Diabetic group compared to the Sham and Control groups with $p < 0.05$. There was a significant decrease in the Diabetic + Insulin group in comparison to the Diabetic group ($p < 0.05$) (Figure. 3). There was not a significant difference among the Diabetic + Insulin, Sham, and Control groups.

The effect of diabetes on sperm morphology

The details of sperm morphology and sperm count in different groups are presented in Table 2 and sperm abnormalities are shown in Figure. 3. As can be seen, the main abnormality involved is in the head and tail of the mice. The percentage of normal spermatozoa and sperm count in the Diabetic group is significantly lower than that of the Control group ($p < 0.05$). However, in the group treated with insulin, the percentage of normal spermatozoa and sperm count, in comparison with the Diabetic group increased significantly ($p < 0.05$). In this regard, there were no significant changes in the Diabetic + Insulin, Sham, and Control groups.

Effects of diabetes on CatSper 1, 2 proteins in male mice

The immunohistochemistry technique showed the localization of CatSper proteins. Figures. 4 and 5 show immunoreactivity of CatSper 1 and 2 proteins in mice sperm, respectively. Various parts that reacted to the antibodies are shown in brown. The reaction was observed in the head and sperm flagellum. Among all groups, no significant difference was observed in the head and tail immunoreactivity. Compared to Control and Sham groups, the Diabetic group showed a significant reduction in the severity of the reaction in the middle piece ($p < 0.05$). The results also showed no significant difference between Control and Sham groups. There was a significant increase in the intensity of reactivity in the Diabetic + Insulin group compared to the diabetic group ($p < 0.05$, Figure. 6). Figures. 4, E and 5, E illustrates the immunohistochemistry localization of CatSper 1 and 2 proteins in seminiferous tubules of testis tissue. Positive staining for CatSper proteins is shown in brown. We found that reaction of immunohistochemistry was restrained to spermatids, and the immunoreactivity patterns of Catsper1 and Catsper 2 were identical.

The effect of diabetes on CatSper 1, 2 expressions

Our results showed a significant decrease in CatSper 1 and 2 expressions in the Diabetic compared to the Control group and also a significant decrease between the Diabetic and Sham groups ($p < 0.001$). There was no significant difference between Control and Sham groups. Compared to the Diabetic group, the Diabetic + Insulin group showed a significant increase ($p < 0.001$, Figure. 7).

The effect of diabetes on MDA, SOD and Thiol

The details of the results of the biochemical test in different groups are presented in Table 3. Our results showed a statistically significant increase in MDA in the Diabetic compared to the Control group and also a statistically significant increase in the Diabetic and Sham groups ($p < 0.01$). Compared to the Diabetic group, the Diabetic + Insulin group showed a statistically significant decrease ($p < 0.01$). Results of the SOD test revealed a statistically significant decrease in the Diabetic compared to the Control group and also a statistically significant decrease between the Diabetic and Sham groups ($p < 0.001$). Compared to the

Diabetic group, the Diabetic + Insulin group showed a statistically significant increase ($p < 0.001$).

There was no statistically significant difference between Control and Sham groups in MDA and SOD tests. Results of the Thiol test showed a decrease in the Diabetic compared to Control, sham, and Diabetic + Insulin groups but this difference was not statistically significant between the groups.

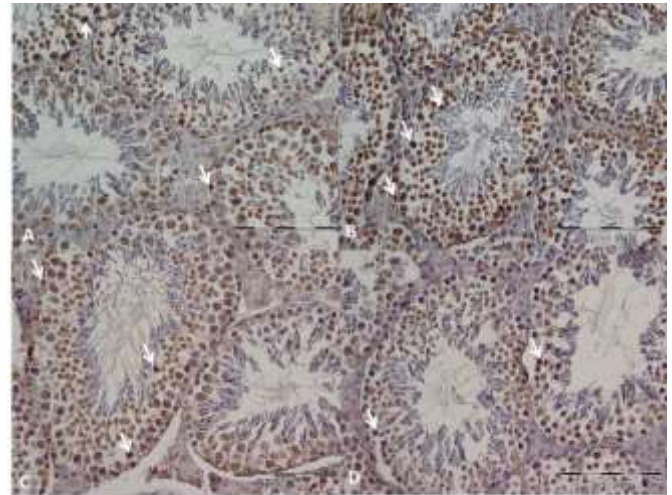


Figure 1. Photomicrographs show the TUNEL positive cells in the germinal epithelium of testes in different groups. Control (A), Diabetic (B), Diabetic+Insulin (C) and Sham (D) groups. Arrows show apoptotic cell (magnification 40 \times , scale bar = 100 μ).

Table 2. The results of sperm chromatin/DNA and morphology evaluation in different groups

Variable	Control	Diabetic	Diabetic + Insulin	Sham
AB (%)	19 \pm 2.236	42 \pm 3.082 ^{ab}	25 \pm 3.240	23 \pm 2.549
TB (%)	23 \pm 2.738	50 \pm 3.162 ^{ab}	29 \pm 2.236	23 \pm 1.479
Normal Spermatozoa(%)	85 \pm 3.391	55 \pm 3.391 ^{ab}	78 \pm 2.549	83 \pm 3.344
Count ($\times 10^6$ /ml)	46 \pm 3.28	23.2 \pm 3.12 ^{ab}	39.2 \pm 4.44	43.8 \pm 3.86

AB, aniline blue; TB, toluidine blue

a Significant compared to Control and Sham groups in the same row ($P \leq 0/05$).

b Significant compared to Diabetes + Insulin group in the same row ($P \leq 0/05$).

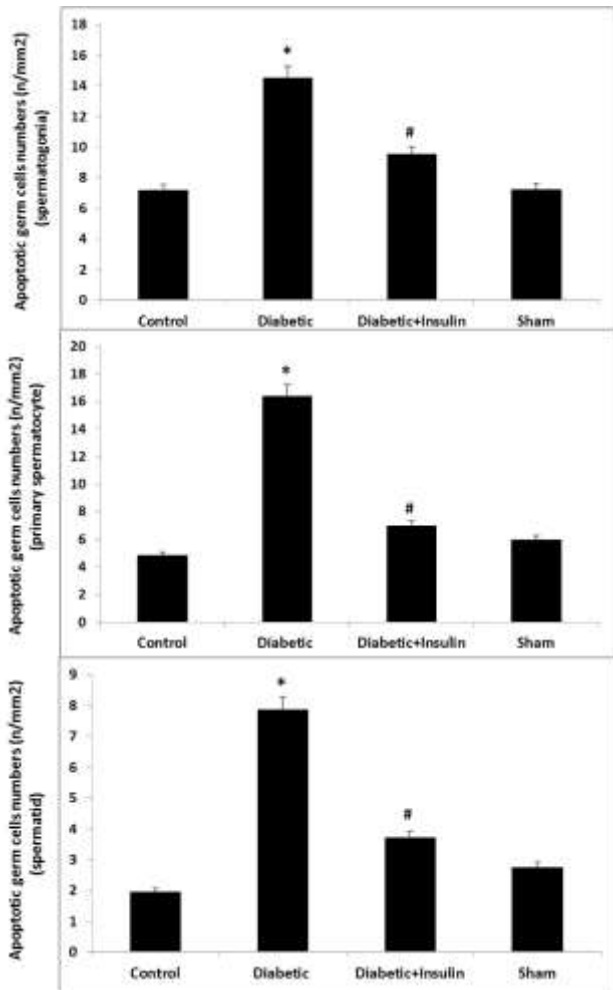


Figure 2. Comparison of TUNEL positive cell (apoptotic cell) numbers pre unit area in the germinal epithelium of mice testes. Data expressed as mean \pm SEM. There was significant differences between Control and Sham groups with Diabetic group $**P < 0.001$. There was significant differences between Diabetic and Diabetic + Insulin groups $*P < 0.001$.




Figure 3. (A) Aniline Blue-reacted spermatozoa (AB⁺) and normal sperm cell (AB⁻). Aniline Blue staining, (B). Toluidine Blue staining of spermatozoa. TB⁺ indicates sperm cells with abnormal chromatin and TB⁻ indicates sperm cells with normal chromatin. (C). Different forms of sperm morphological abnormalities. The arrow indicates a normal spermatozoon. Papanicolaou staining.

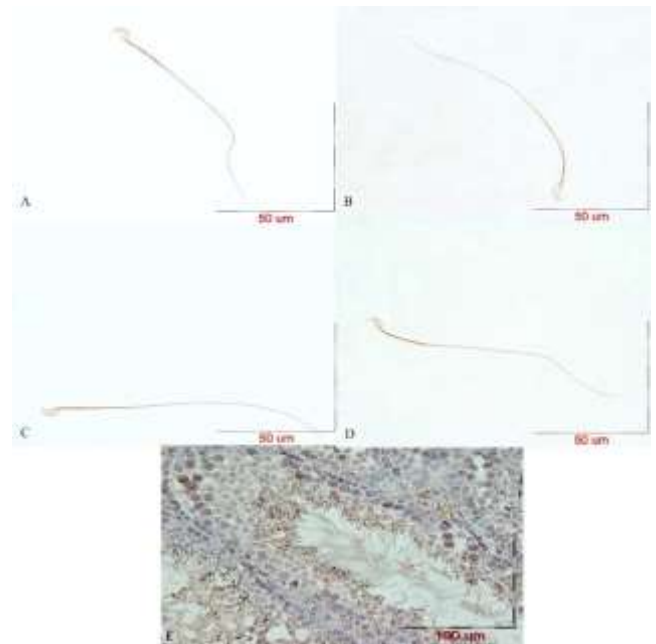


Figure 4. Effect of Diabetes on immunoreactivity of CatSper 1 protein in mice sperm. Photomicrographs show immunolocalization of CatSper 1 protein in the head, middle and tail of sperm in Control (A), Diabetic (B), Diabetic+Insulin (C) and Sham (D) groups. Positive immunoreactions were shown to different grade of intensity brown color. (E), immunolocalization of catsper 1 protein in testis tissue.

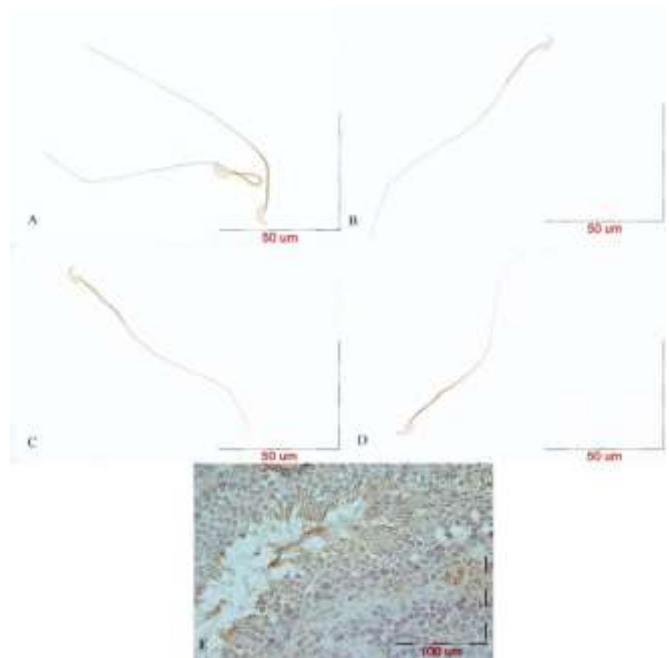


Figure 5. Effect of Diabetes on immunoreactivity of CatSper 2 protein in mice sperm. Photomicrographs show immunolocalization of CatSper 2 protein in the head, middle and tail of sperm in Control (A), Diabetic (B), Diabetic+Insulin (C) and Sham (D) groups. Positive immunoreactions were shown to different grade of intensity brown color. (E), immunolocalization of catsper 2 protein in testis tissue.

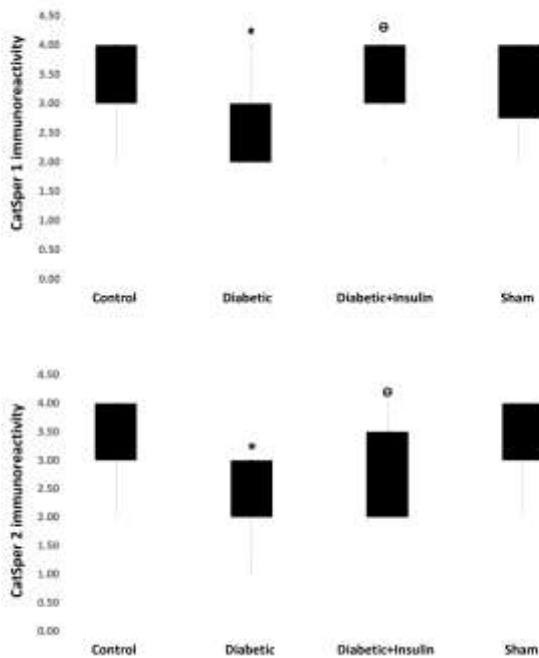


Figure 6. Boxplot shows the effect of diabetes on immunoreaction of CatSper 1,2 proteins in middle piece of sperm. Significant differences between Control and Sham groups with Diabetic group.* $P < 0.05$. Significant differences between Diabetic and Diabetic +Insulin groups $\Theta P < 0.05$.

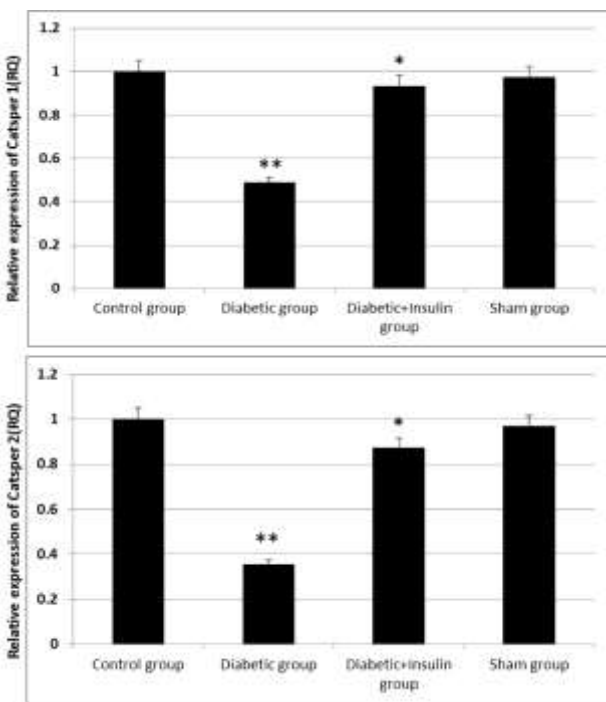


Figure 7. Effect of Diabetes on CatSper 1, 2 mRNA expression in mice epididymis. Data expressed as mean \pm SEM. There was significant differences between Control and Sham groups with Diabetic group ** $P < 0.001$. There was significant differences between Diabetic and Diabetic + Insulin groups * $P < 0.001$. RQ= Relative quantification.

Table 3. The results of MDA, SOD and Thiol measurement

Variable	Control	Diabetic	Diabetic +Insulin	Sham
MDA(nanomol/g)	8.62 \pm 1.23	13.99 \pm 2.98 ^{ab}	8.17 \pm 0.54	8.52 \pm 0.98
SOD(U/g)	35.62 \pm 1.59	24.51 \pm 2.18 ^{ab}	33.74 \pm 1.11	35.11 \pm 0.47
Thiol(micromol/g)	0.73 \pm 0.07	0.59 \pm 0.19	0.63 \pm 0.1	0.72 \pm 0.1

a Significant compared to Control and Sham groups in the same row ($P \leq 0/05$).

b Significant compared to Diabetes + Insulin group in the same row ($P \leq 0/05$).

The findings of the current study revealed that diabetes has adverse effects on DNA integrity, morphology, and Catsper expression of sperm. In addition, it is shown that insulin attenuated the morbidity of diabetes on these parameters. In the present study, we evaluated sperm quality and chromatin/DNA integrity of germ cells in diabetic mice. Sisman et al. assessed Potential Novel Biomarkers for Diabetic Testicular Damage in Streptozotocin-Induced Diabetic Rats: Nerve Growth Factor Beta and Vascular Endothelial Growth Factor. They showed that the number of TUNEL-positive cells was significantly increased in the diabetic group compared to the control group (34). Cai et al and Salimnejad et al. evaluated apoptotic germ-cell death and testicular damage in experimental diabetes. According to their results, degenerated germ cells and TUNEL-positive cells were significantly higher in diabetic rats than in control animals (35, 36). Our results were consistent with those of the mentioned studies and showed the number of apoptotic germ cells including spermatogonia, primary spermatocyte, and spermatid was significantly increased in the Diabetic group compared to the Control group. Furthermore, a comparison of apoptotic cells in the Diabetic + Insulin groups with the Diabetic group revealed a statistically significant decrease in apoptotic cells. In AB staining, which shows the sperm cells with excessive histones, we found significant differences between Control and Diabetic groups. Also, there was a significant difference between the Diabetic and Diabetic +Insulin groups. In contrast to our results, Mangoli et al. did not find any significant differences between control and diabetic groups (5). In agreement with our findings, Pouretezari et al. showed AB⁺ cells in the diabetic group increased significantly compared to control group (37). Moreover, consistent with previous findings, results of this study showed a significant difference in TB⁺ cells between the Diabetic and Control groups (5, 37). Results of this study also

showed a significant decrease in the percentage of epididymal normal sperm in the Diabetic group which is in agreement with previous studies (21, 37-39), as well as an increase in normal sperm in mice treated with insulin. Also, our findings showed that sperm count in the Diabetic group decreased significantly compared to the Control group and in the Diabetic + Insulin groups and increased significantly compared to the Diabetic group. Contrary to our findings, Agbaje et al. examined spermatozoa in diabetic and non-diabetic men and reported no significant differences in sperm concentration, total sperm count, and morphology between the two groups (5).

It has been demonstrated that diabetes affects sperm motility (40). Calcium channels such as CatSper is an essential factor for sperm motility and diabetes may affect these channels. Therefore, in this study, the effects of experimental diabetes on genes expression CatSper1 2 were evaluated. Using immunohistochemistry we observed CatSper proteins in testis tissue and noticed a significant decrease in mRNA levels of CatSper 1 and 2 in the Diabetic group compared to the other groups. Furthermore, we identified a significant increase in the Diabetic + Insulin group compared to the Diabetic group. In agreement with our reports, Mohammadi et al. assessed the effects of Vitamin-E treatment on CatSper genes expression in the testis; they concluded that CatSper proteins reaction was significant among different groups (31). Also, Ren et al. applied an indirect fluorescent antibody technique to examine CatSper1 protein location in C57BL/6 mice sperm. They suggested that CatSper proteins exist in sperm (18). Similarly, in this study, using immunohistochemistry we observed CatSper proteins localization in the head, middle piece, and tail of sperm in all groups. However, the middle piece had much more reaction among different groups and we observed a significant difference in the immunoreactivity of the middle piece in the diabetic group compared to the control group.

Mohamed et al. assessed Taurine dietary supplementation on oxidative stress in streptozotocin-induced diabetes mellitus in testes. In another study, Salimnejad et al. investigated the Effect of Garlic Aqueous Extract on Markers of Oxidative Stress in Diabetic Rats Testes. Results of these two studies showed that during diabetes, the level of MDA enzymes activity was increased while the

level of SOD enzyme activity decreased in the testes (4, 41). In line with mentioned studies, our results showed that the levels of MDA and SOD in the Diabetic group compared to other group changed significantly. It is demonstrated that the level of oxidative stress is high in a hyperglycemia state, due to excess production of reactive oxygen species (ROS). Oxidative stress is the main factor in male infertility by changing the cell function such as sperm motility, increasing DNA damage by induction of gene mutations, DNA denaturation, base-pair oxidation, and DNA fragmentation (42-45).

Conclusions

Results of this study showed that diabetes had a statistically significant difference in some of the sperm parameters such as DNA integrity, morphology, and CatSper expression in comparison with Controls. Also, we demonstrated that Diabetic + Insulin mice enhanced chromatin condensation, DNA integrity, and Catsper expression compared to the diabetic mice.

Acknowledgments

The data used in this paper is from a Ph.D. student thesis (NO: 931750). This study was supported financially by the Vice Chancellor for Research at Mashhad University of Medical Sciences, Iran. The authors would like to thank Mrs. F. Motejadded and F.Tajik for their excellent technical assistance.

Conflict interest

The authors confirm that there is no conflict of interest regarding the publication of this article.

Author's contributions

Elnaz Khordad, Mohammad Reza Nikraves, Mehdi Jalali, Alireza Fazel, Mojtaba Sankian, Fatemeh Alipour.

Kh.E.; performed experiments, analyses data, Performed transporter experiments, co-wrote the paper, Provided essential mouse strains, N.Mr.; Supervised the research, co-wrote the paper, Designed experiments, J.M.; Supervised the research, co-wrote the paper, Designed experiments, F.AR.; Consultant in immunohistochemical technique, S.M.; Consultant in real-time PCR, A.F.; performed experiments, co-wrote the paper.

References

1. Azeez SH, Jafar SN, Azizaram Z, Fang L, Mawlood AH, Ercisli MF. Insulin-producing cells from bone marrow stem cells versus injectable insulin for the treatment of rats with type I diabetes. *Cell Mol Biomed Rep* 2021;1(1):42-51. doi: 10.55705/cnbr.2021.138888.1006.
2. Khoshnoodi J, Pedchenko V, Hudson BG. Mammalian collagen IV. *Microsc Res Tech*. 2008 May;71(5):357-70.
3. Saeedi Borujeni MJ, Esfandiary E, Taheripak G, Codoner-Franch P, Alonso-Iglesias E, Mirzaei H. Molecular aspects of diabetes mellitus: Resistin, microRNA, and exosome. *J Cell Biochem*. 2017 Jul 08.
4. Mohamed. NA, Gawad. HSA. Taurine dietary supplementation attenuates brain, thyroid, testicular disturbances and oxidative stress in streptozotocin-induced diabetes mellitus in male rats. *BJBAS*. 2017;6:247-52.
5. Mangoli E, Talebi AR, Anvari M, Pouretezari M. Effects of experimentally-induced diabetes on sperm parameters and chromatin quality in mice. *Iran J Reprod Med*. 2013 Jan;11(1):53-60.
6. Alasmari W, Barratt CL, Publicover SJ, Whalley KM, Foster E, Kay V, et al. The clinical significance of calcium-signalling pathways mediating human sperm hyperactivation. *Hum Reprod*. 2013 Apr;28(4):866-76.
7. Amini M, Shirinbayan P, Behnam B, Roghani M, Farhoudian A, Joghataei MT, et al. Correlation between expression of CatSper family and sperm profiles in the adult mouse testis following Iranian Kerack abuse. *Andrology*. 2014 May;2(3):386-93.
8. Jin J, Jin N, Zheng H, Ro S, Tafolla D, Sanders KM, et al. Catsper3 and Catsper4 are essential for sperm hyperactivated motility and male fertility in the mouse. *Biol Reprod*. 2007 Jul;77(1):37-44.
9. Breitbart H. Intracellular calcium regulation in sperm capacitation and acrosomal reaction. *Mol Cell Endocrinol*. 2002 Feb 22;187(1-2):139-44.
10. Baldi E, Casano R, Falsetti C, Krausz C, Maggi M, Forti G. Intracellular calcium accumulation and responsiveness to progesterone in capacitating human spermatozoa. *J Androl*. 1991 Sep-Oct;12(5):323-30.
11. Bielfeld P, Faridi A, Zaneveld LJ, De Jonge CJ. The zona pellucida-induced acrosome reaction of human spermatozoa is mediated by protein kinases. *Fertil Steril*. 1994 Mar;61(3):536-41.
12. Darszon A, Labarca P, Nishigaki T, Espinosa F. Ion channels in sperm physiology. *Physiol Rev*. 1999 Apr;79(2):481-510.
13. De Jonge CJ, Han HL, Mack SR, Zaneveld LJ. Effect of phorbol diesters, synthetic diacylglycerols, and a protein kinase C inhibitor on the human sperm acrosome reaction. *J Androl*. 1991 Jan-Feb;12(1):62-70.
14. Quill TA, Sugden SA, Rossi KL, Doolittle LK, Hammer RE, Garbers DL. Hyperactivated sperm motility driven by CatSper2 is required for fertilization. *Proc Natl Acad Sci U S A*. 2003 Dec 9;100(25):14869-74.
15. Chung JJ, Navarro B, Krapivinsky G, Krapivinsky L, Clapham DE. A novel gene required for male fertility and functional CATSPER channel formation in spermatozoa. *Nat Commun*. 2011 Jan 11;2:153.
16. Kirichok Y, Lishko PV. Rediscovering sperm ion channels with the patch-clamp technique. *Mol Hum Reprod*. 2011 Aug;17(8):478-99.
17. Singh AP, Rajender S. CatSper channel, sperm function and male fertility. *Reprod Biomed Online*. 2015 Jan;30(1):28-38.
18. Ren D, Navarro B, Perez G, Jackson AC, Hsu S, Shi Q, et al. A sperm ion channel required for sperm motility and male fertility. *Nature*. 2001 Oct 11;413(6856):603-9.
19. Carreira JT, Trevizan JT, Carvalho IR, Kipper B, Rodrigues LH, Silva C, et al. Does sperm quality and DNA integrity differ in cryopreserved semen samples from young, adult, and aged Nellore bulls? *Basic Clin Androl*. 2017;27:12.
20. Schulte RT, Ohl DA, Sigman M, Smith GD. Sperm DNA damage in male infertility: etiologies, assays, and outcomes. *J Assist Reprod Genet*. 2010 Jan;27(1):3-12.
21. Talebi AR, Mangoli E, Nahangi H, Anvari M, Pouretezari M, Halvaei I. Vitamin C attenuates detrimental effects of diabetes mellitus on sperm parameters, chromatin quality and rate of apoptosis in mice. *Eur J Obstet Gynecol Reprod Biol*. 2014 Oct;181:32-6.
22. Kazerooni T, Asadi N, Jadid L, Kazerooni M, Ghanadi A, Ghaffarpassand F, et al. Evaluation of sperm's chromatin quality with acridine orange test, chromomycin A3 and aniline blue staining in couples with unexplained recurrent abortion. *J Assist Reprod Genet*. 2009 Nov-Dec;26(11-12):591-6.
23. Thomas J, Garg ML, Smith DW. Dietary resveratrol supplementation normalizes gene expression in the hippocampus of streptozotocin-induced diabetic C57Bl/6 mice. *J Nutr Biochem*. 2014 Mar;25(3):313-8.
24. Khordad E, Alipour F, Beheshti F, Hosseini M, Rajabzadeh AA, Asiaei F, et al. Vitamin C prevents hypothyroidism associated neuronal damage in the hippocampus of neonatal and juvenile rats: A stereological study. *J Chem Neuroanat*. 2017 Nov 24.
25. Khordad E, Fazel A, Ebrahimzadeh Bideskan A. The Effect of Ascorbic Acid and Garlic Administration on Lead-Induced Apoptosis in Rat Offspring's Eye Retina. *Iran Biomed J*. 2013 Oct;17(4):206-13.
26. Lu WP, Mei XT, Wang Y, Zheng YP, Xue YF, Xu DH. Zn(II)-curcumin protects against oxidative stress, deleterious changes in sperm parameters and histological alterations in a male mouse model of cyclophosphamide-induced reproductive damage. *Environ Toxicol Pharmacol*. 2015 Mar;39(2):515-24.
27. Heidari R, Alizadeh R, Abbasi N, Pasbakhsh P, Hedayatpour A, Farajpour M, et al. Do Pilea Microphylla Improve Sperm DNA Fragmentation and Sperm Parameters in Varicocele Rats? *Acta Med Iran*. 2015;53(9):547-54.
28. Nazar M, Talebi AR, Hosseini Sharifabad M, Abbasi A, Khoradmehr A, Danafar AH. Acute and chronic effects

- of gold nanoparticles on sperm parameters and chromatin structure in Mice. *Int J Reprod Biomed (Yazd)*. 2016 Oct;14(10):637-42.
29. Pandiar D, Baranwal HC, Kumar S, Ganesan V, Sonkar PK, Chattopadhyay K. Use of jaggery and honey as adjunctive cytological fixatives to ethanol for oral smears. *J Oral Maxillofac Pathol*. 2017 May-Aug;21(2):317.
 30. Aldaghi M, Sankian M, Sameni H, Safari M. Effects of Alpha Lipoic Acid Treatment on Laminin Alteration of the Sciatic Nerve in Streptozotocin Induced Diabetic Rats. *Middle East J Rehabil Health*. 2014;2.
 31. Mohammadi S, Jalali M, Nikravesh MR, Fazel A, Ebrahimzadeh A, Gholamin M, et al. Effects of Vitamin-E treatment on CatSper genes expression and sperm quality in the testis of the aging mouse. *Iran J Reprod Med*. 2013 Dec;11(12):989-98.
 32. Baghcheghi Y, Beheshti F, Salmani H, Soukhtanloo M, Hosseini M. Protective Effect of PPARgamma Agonists on Cerebellar Tissues Oxidative Damage in Hypothyroid Rats. *Neurol Res Int*. 2016;2016:1952561.
 33. Madesh M, Balasubramanian KA. Microtiter plate assay for superoxide dismutase using MTT reduction by superoxide. *Indian J Biochem Biophys*. 1998 Jun;35(3):184-8.
 34. Sisman AR, Kiray M, Camsari UM, Evren M, Ates M, Baykara B, et al. Potential novel biomarkers for diabetic testicular damage in streptozotocin-induced diabetic rats: nerve growth factor Beta and vascular endothelial growth factor. *Dis Markers*. 2014;2014:108106.
 35. Cai L, Chen S, Evans T, Deng DX, Mukherjee K, Chakrabarti S. Apoptotic germ-cell death and testicular damage in experimental diabetes: prevention by endothelin antagonism. *Urol Res*. 2000 Oct;28(5):342-7.
 36. Salimnejad R, Jalali M, Nikravesh MR, Fazel AR. protective effects of garlic aqueous extract on germ cells' apoptosis in the male diabetic rats. *Int J Curr Res*. 2014;4(4):1451-5.
 37. Pouretezari M, Talebi AR, Mangoli E, Anvari M, Rahimipour M. Additional deleterious effects of alcohol consumption on sperm parameters and DNA integrity in diabetic mice. *Andrologia*. 2016 Jun;48(5):564-9.
 38. Arikawe AP, Daramola AO, Odofoin AO, Obika LF. Alloxan-induced and insulin-resistant diabetes mellitus affect semen parameters and impair spermatogenesis in male rats. *Afr J Reprod Health*. 2006 Dec;10(3):106-13.
 39. Talebi AR, Vahidi S, Aflatoonian A, Ghasemi N, Ghasemzadeh J, Firoozabadi RD, et al. Cytochemical evaluation of sperm chromatin and DNA integrity in couples with unexplained recurrent spontaneous abortions. *Andrologia*. 2012 May;44 Suppl 1:462-70.
 40. Abdolahnejad A GA, Dabiri Sh. Garlic effects on reproductive complications of diabetes mellitus in male rats. *Physio & Pharma*. 2009;13:297-07.
 41. Salimnejad R, Jalali M, Nikravesh MR, Fazel AR. Effect of Garlic Aqueous Extract on Markers of Oxidative Stress in Diabetic Rats Testes. *JRUMS* 2014;13(4):371-82.
 42. Agarwal A, Prabakaran SA, Said TM. Prevention of oxidative stress injury to sperm. *J Androl*. 2005 Nov-Dec;26(6):654-60.
 43. Agarwal A, Said TM. Oxidative stress, DNA damage and apoptosis in male infertility: a clinical approach. *BJU Int*. 2005 Mar;95(4):503-7.
 44. Makker K, Agarwal A, Sharma R. Oxidative stress & male infertility. *Indian J Med Res*. 2009 Apr;129(4):357-67.
 45. Steger RW, Rabe MB. The effect of diabetes mellitus on endocrine and reproductive function. *Proc Soc Exp Biol Med*. 1997 Jan;214(1):1-11.