

Evaluation of hepatoprotective effects of crude methanolic extract of *Datura metel* L. in mice

Waqas Alam¹, Haroon Khan^{1*}, Sajjad Ali Khan¹, Niaz Ali², Naveed Sharif³, Rukhsana Ghafar⁴, Sana Nazir¹, Maria Daglia^{5,6*}

¹Department of Pharmacy, Abdul Wali Khan University Mardan, 23200, Pakistan

²Department of Pharmacology, Institute of Basic Medical Sciences (IBMS), Khyber Medical University, Peshawar, Pakistan

³Department of Pathology, Khyber Medical College/ Khyber Teaching Hospital, Peshawar, Pakistan

⁴Department of Pharmacy, University of Malakand, Malakand, Pakistan

⁵Department of Pharmacy, University of Naples Federico II, Via Domenico Montesano 49, 80131 Naples, Italy

⁶International Research Center for Food Nutrition and Safety, Jiangsu University, Zhenjiang, 212013, China

*Correspondence to: hkdr2006@gmail.com ; haroonkhan@awkum.edu.pk; maria.daglia@unina.it

Received August 10, 2020; Accepted November 28, 2020; Published January 31, 2021

Doi: <http://dx.doi.org/10.14715/cmb/2021.67.1.26>

Copyright: © 2021 by the C.M.B. Association. All rights reserved.

Abstract: *Datura metel* has been recommended in several human disorders including a remedy for liver toxicity. The current study was designed to evaluate the hepatoprotective effect of methanolic extract of *D. metel* in animal model. Acute toxicity of methanolic crude extract of *Datura metel* (MEDM) was studied in animals in various doses 500-2000 mg/kg. Mice of either sex were divided into groups ($n=6$). One group received normal saline intraperitoneally as negative control, while other gentamicin 100mg/kg for 8 days as positive control. 3rd group received 50mg/kg silymarin as standard, 4th group received 100mg/kg of MEDM, 5th group received 200mg/kg MEDM while 6th group received 300mg/kg MEDM and gentamicin 100mg/kg for 8 days. The blood samples were collected on 9th day and the animals were then dissected and the liver of all the animals were isolated. MEDM was found safe in acute toxicity test at various doses up to 2000 mg/kg. The levels of serum glutamic pyruvic transaminase and alkaline phosphatase were elevated significantly with gentamicin treatment which significantly down-regulated by MEDM (100, 200 and 300 mg/kg) in a dose dependent manner. The histological examination showed that the MEDM has markedly treated the inflammatory infiltrate, fatty changes and congested blood vessels which were induced by gentamicin. The findings of our study thus proved the absolute of MEDM in acute toxicity test; followed by significant hepatoprotective effect in gentamicin induced hepatotoxic mice.

Key words: *Datura metel* extract; Phytochemical screening; *In vivo* hepatoprotective screening; Biomarkers, Histopathology.

Introduction

Liver is the vital organ of the body and plays major role in detoxification and elimination of various metabolic products and drug's metabolites. Gentamicin causes damaging effects to liver but the underline causes are still unclear, although the elevated alkaline Phosphatase (ALP) and serum glutamic pyruvic transaminase (SGPT) levels have been linked with gentamicin administration. Gentamicin has also raised liver malonaldehyde (MDA) level but decreased serum oxide dismutase (SOD) expression (1). It has been established that aminoglycosides stimulate the production of free radicals and modify antioxidant enzymes system which results in tissue injury and it has also been reported that gentamicin modifies the activity of hepatic glycogen phosphorylase and leads to less glycogen content of liver (2).

Nowadays in developing and developed countries, medicinal plants are frequently used. WHO has reported that about 80 percent of population prefer traditional medicines for their ailments (3). Herbs are reported to have hepatoprotective effects because of the existence of various active pharmacological chemical groups (4).

D. metel is an annual herb, found to be growing as

weed but in tropic and temperate zone it is cultivated too. It belongs to solanaceae family (5). *D. metel* is commonly known as thorn's apple, Indian apple or devil's trumpet which is distributed all over the world such as Nigeria, Central Asia, Bangladesh and Central America (6, 7). *D. metel* possess anticholinergic action. *D. metel* has antifungal, antibacterial and anti-dandruff action (8). *D. metel* was used traditionally as bronchodilator, antitussive, anodyne, germicidal, antiseptic, narcotic, astringent antioxidant, sedative, anti-inflammatory, analgesic, antispasmodic and antidiabetic (9, 10). Alabri *et al.*, 2014, and Hossain *et al.*, 2014, has reported that the crude methanolic extracts of *D. metel* has the ability to exhibit antioxidant activity due to free radical scavenging activity (11, 12). Mai *et al.*, 2017, has isolated different flavonoids such as kaempferol from *D. metel* (5). Kaempferol exhibits antioxidant effect and free radical scavenging activity (13).

The traditional uses of *D. metel* for hepatic disorders and the ethnopharmacological uses of methanolic crude extract of the plant as antioxidant and free radical scavenger (11, 12) provoked us to evaluate the hepatoprotective effect of *D. metel* in animal model and also determine the scientific background for the hepatoprotective effect of *D. metel*.

Materials and Methods

Plant material

The collections of fresh plant of *D. metel* were done from the uncultivated lands of Village Patikhurd, Takht Bhai Tehsil of District Mardan, Khyber Pakhtunkhwa, Pakistan in May and June 2018. The plant specimen was identified and authenticated by Dr. Gul Jan (Assistant professor at Department of Botany, Abdul Wali Khan University Mardan (AWKUM) by comparing with specimen already present at Department of Botany, AWKUM, and Flora of Pakistan. HDB, AWKUM-75 was allotted by department of Botany, AWKUM.

Extraction and maceration

For methanolic extract, the dried powdered plant of *D. metel* (950 g) was macerated with hydroalcoholic solvent (90% methanol and 10 % distilled water) in a stainless steel closed container at room temperature for 14 days. Frequent stirring was done during the maceration period. After 14 days the hydroalcoholic soluble residues were passed through muslin cloth and then by filtration with commercial available filter paper (Whatman filter paper NO.1). This process was repeated three times with the macerated powder.

The filtrate obtained was then collected in a beaker and was dried with the help of rotary evaporator at about 40–45 °C until the filtrate was completely dried. After the complete drying of filtrate, 90 grams of a solid, oily viscous crude extract was obtained. The crude extract obtained was collected in closed glass container and was refrigerated (2–8 °C). The extract obtained was further investigated for pharmacological and phytochemical constituents.

Animals used

Healthy Swiss albino mice, ranging in weight from 25–30 grams of either sex were purchased from the Veterinary Research Institute (VRI) Peshawar, Pakistan. Cages were used for animals housing in well crossed ventilated animal house of the department of pharmacy, AWKUM, at a temp of (22±1 °C). Before the experiment, the test animals were acclimatized for one week with dark and light cycles of 12 hours. Standard diet for rodents (pellet) as well as fresh water *ad libitum* was given to test animals. All experimental measures and research was carried out according to the guidelines for laboratory animals adopted by the Ethics committee, Department of Pharmacy, Garden campus Abdul Wali Khan University, Mardan.

Acute oral toxicity test

OECD Guidelines No. 423(14), were followed to investigate acute toxicity test for extract on test animals. Four groups of the test mice (Swiss albino) were prepared. Six animals ($n=6$) were assigned to every group. *D. metel* extract was administered orally by gavage in different gradual increasing doses level of 500, 1000, 1500 and 2000 mg/kg. Animals were keenly observed for 24 hours to check the signs and symptoms (writhing, convulsions, sedations, immobility and photosensitivity) of toxicity and mortalities. The procedure was repeated thrice.

Hepatoprotective activity testing

Grouping and dosing of animals

Six groups of 36 Swiss albino mice (25–30g) were made. Six mice ($n=6$) were placed in every group. The doses for plant extract were calculated on the basis of acute toxicity study and pilot study and 100 mg/kg dose was selected as initial dose.

1. Animal in group-1 were injected intraperitoneally with 0.9% normal saline for 8 days.

2. Animals in Group 2 were administered Gentamicin (100 mg/kg/day) intraperitoneally for 8 days.

3. Animals of Group 3 were administered Silymarin (50mg/kg/day) as positive control (hepatoprotective agent) as well as Gentamicin (100mg/kg/day) intraperitoneally for 8 days.

4. Animals in group 4 were administered MEDM (100mg/kg/day) as well as Gentamicin (100mg/kg/day) were injected intraperitoneally for 8 days.

5. Animals in group 5 were administered MEDM (200mg/kg/day) as well as Gentamicin (100mg/kg/day) were delivered intraperitoneally for 8 days.

6. Animals in group 6 were administered MEDM (300mg/kg/day) as well as Gentamicin (100mg/kg/day) were given intraperitoneally for 8 days.

The MEDM and silymarin was dissolved in normal saline as vehicle for administration. After the collection of blood and urine samples the animals were sacrificed at 9th day under mild chloroform anesthesia and organs (liver) were isolated, washed with normal saline and then conserved in 10% formalin solution for histological assessment (15–17). The above procedure was performed 3 times to avoid any error.

Sample collection

The animals were fasted overnight. After 24 h of the last treatment at 9th day of the experimental procedure, the animals of individual group were anesthetized with chloroform and sacrificed. The blood was directly collected from the heart of mice by cardiac puncture. The collected blood was transferred immediately into gel tubes to prevent haemolysis. The samples were kept for 15 minutes at room temperature for coagulation, centrifuged at 4000 rpm to separate serum. The samples were kept for 15 minutes at room temperature for coagulation, centrifuged at 4000 rpm to separate serum. The serum was then preserved for biochemical assays at 2–8 °C refrigerator (16, 18). The animals were dissected and liver specimens were immediately isolated from mice and rinsed with normal saline for lipid per oxidation and histological examination (19).

Biochemical analysis

Serum glutamic pyruvic transaminase and alkaline phosphatase

The activities of SGPT and ALP were measured as parameters of liver function test. The elevation of serum level of SGPT is indicative of damage to hepatocytes. Oxidative stress is the responsible mechanism for hepatocytes damage and disease condition. Gentamicin suppresses the enzymatic antioxidants as well as non-enzymatic and causes increase generation of ROS which in turn drastically affects phospholipids membranes but also damages the membrane proteins and nucleic acids. As a result, liver damage and hepatotoxicity occurs

(20). The collected blood samples were then analyzed for SGPT and ALP by using auto analyzer and different commercial diagnostic kits (Roche) (16, 18).

Histological assessment

The already preserved (10% neutral buffered formalin) liver specimens were used and then embedded in paraffin for 24 h. The liver was incised into 4-5µm sections and de paraffinized, hydrated and stained with H&E (haematoxylin and eosin) stains. Cut sections were also stained with Periodic acid Schiff’s staining. A blinded pathologist used light microscope to examine the hepatic sections for the detection of the extent of damages to hepatocytes (21).

Statistical analysis

All the data were expressed as mean ± standard error mean. The analyses were performed by one-way ANOVA followed by Tukey post hoc multiple comparison test. $P < 0.05$ were considered as statistically significant.

Results

Acute toxicity test

The results of acute toxicity tests revealed that methanolic crude extract of *D. metel* was safe up to 2000mg/kg body weight as no mortality was seen up to 2000mg/kg dose. The animals were observed for 24 h after different dose administration, for different behavioral changes such as writhing, convulsions, sedations, immobility and photo sensitivity (table 2). Writhing was observed mildly while sedation was only observed at 1500 mg/kg and 2000mg/kg while no changes were seen in convulsions, immobility and photo sensitivity. The crude extract was found to be safe up to 2000mg/kg as no morbidity and mortality were seen for 24 h (table 1).

After the administration of dose, the animals were observed for different physical behaviors. The animals started writhing and clumsy movements, then after some time the animals which were administered with 1500 mg/kg dose and 2000 mg/kg dose remained calm. They were being awakened by tapping the cages. No convulsions, immobility and photosensitivity were seen during 24 h.

Biochemical analysis

Serum glutamic pyruvic transaminase (SGPT)

The results of our study (figure 1) showed that gentamicin has significantly raised the serum level of SGPT and caused hepatotoxicity compared to negative control. However, the level of serum SGPT has been lowered down significantly with the administration of MEDM. Different doses of MEDM were administered and different responses were observed which are shown in figure 1. The results of our study showed that MEDM in M100 group did not showed significant hepatoprotective action. Whereas in M200 and M300 groups, MEDM reduced SGPT very significantly ($P < 0.01$), comparison was made against gentamicin treated group which has highly significantly ($P < 0.001$) elevated serum SGPT level.

Alkaline phosphatase (ALP)

The results of ALP level after treated with MEDM is shown in figure 1. Administration of 100 mg/kg gen-

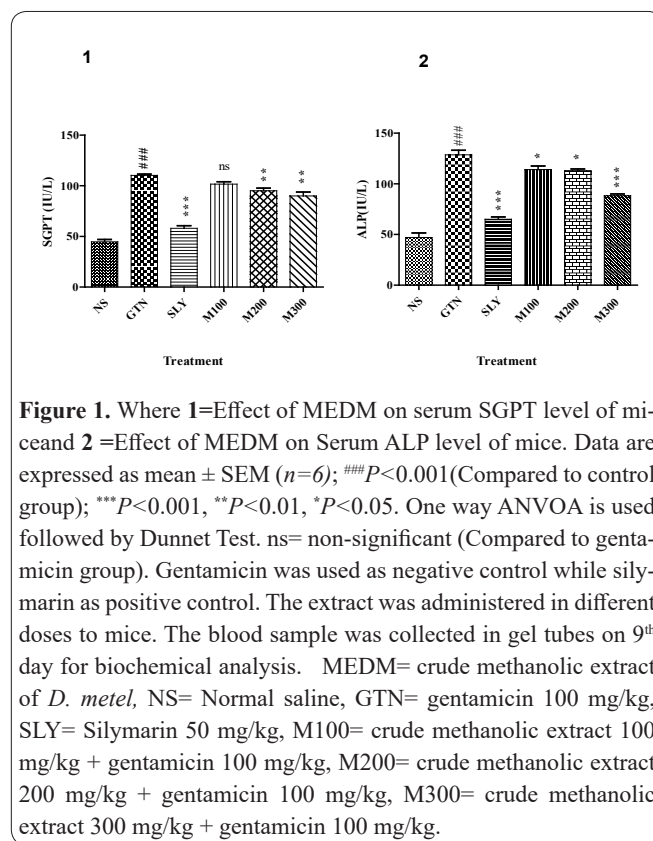


Figure 1. Where 1=Effect of MEDM on serum SGPT level of mice and 2 =Effect of MEDM on Serum ALP level of mice. Data are expressed as mean ± SEM (n=6); ###P<0.001(Compared to control group); ***P<0.001, **P<0.01, *P<0.05. One way ANOVA is used followed by Dunnet Test. ns= non-significant (Compared to gentamicin group). Gentamicin was used as negative control while silymarin as positive control. The extract was administered in different doses to mice. The blood sample was collected in gel tubes on 9th day for biochemical analysis. MEDM= crude methanolic extract of *D. metel*, NS= Normal saline, GTN= gentamicin 100 mg/kg, SLY= Silymarin 50 mg/kg, M100= crude methanolic extract 100 mg/kg + gentamicin 100 mg/kg, M200= crude methanolic extract 200 mg/kg + gentamicin 100 mg/kg, M300= crude methanolic extract 300 mg/kg + gentamicin 100 mg/kg.

Table 1. Toxicity profile and %age mortality of MEDM on animal model.

Dose (extract)	Animals died	Animals survived	% mortality
500 mg/kg	Nil	All	0%
1000 mg/kg	Nil	All	0%
1500 mg/kg	Nil	All	0%
2000 mg/kg	Nil	All	0%

Table 2. Physical behavior of test animals after 24 hours of administration of acute toxic doses.

Dose	Writhing	Convulsions	Sedations	Immobility	Photosensitivity
500 mg/kg	+	-	-	-	-
1000 mg/kg	++	-	-	-	-
1500 mg/kg	+++	-	+	-	-
2000 mg/kg	+++	-	++	-	-

Key: + (present); - (absent); + (mild); ++ (moderate); +++ (sever).

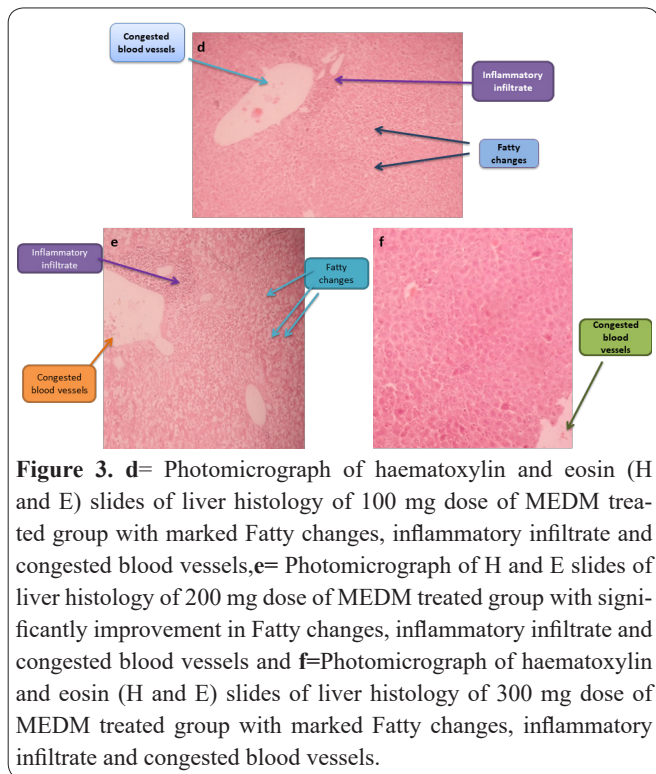
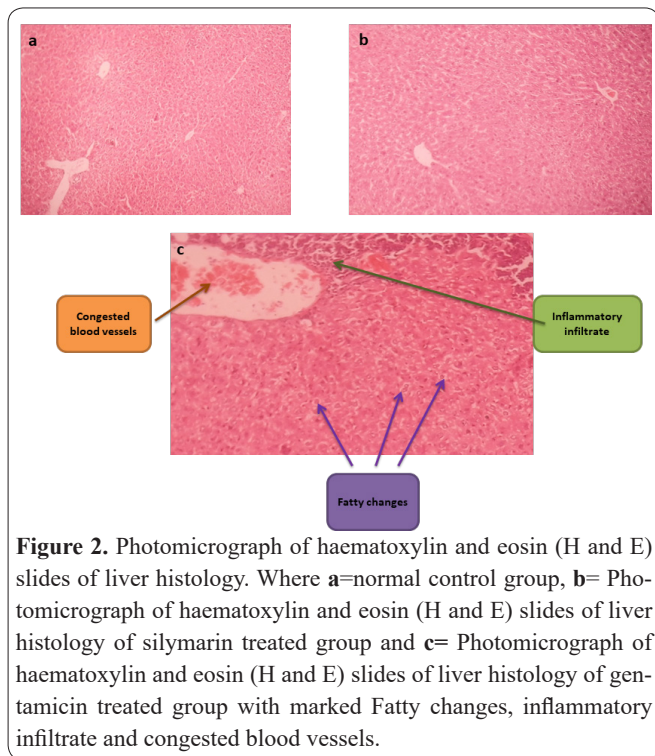


Figure 3. d= Photomicrograph of haematoxylin and eosin (H and E) slides of liver histology of 100 mg dose of MEDM treated group with marked Fatty changes, inflammatory infiltrate and congested blood vessels, e= Photomicrograph of H and E slides of liver histology of 200 mg dose of MEDM treated group with significantly improvement in Fatty changes, inflammatory infiltrate and congested blood vessels and f=Photomicrograph of haematoxylin and eosin (H and E) slides of liver histology of 300 mg dose of MEDM treated group with marked Fatty changes, inflammatory infiltrate and congested blood vessels.

Table 3. Effect of MEDM on the histology of liver of test animals.

Groups	Histological Parameters			
	Fatty Change	Centrilobular Necrosis	Inflammatory Infiltrate	Congested Blood vessels
Control	-	-	-	-
GTN	++	++	++	++
SLY	+	-	-	+
M100	+++	+	+	++
M200	+++	+	+	++
M300	-	-	-	++

Key; -: negative, +: mild, ++: moderate, +++: severe.

gentamicin intraperitoneally for 8 days has highly significantly ($P < 0.001$) elevated the level of serum ALP in test animals compared against control group. This significant raised value of ALP indicates that gentamicin has drastically damaged the liver cells and caused hepatotoxicity. It was noted that the co administration of MEDM in different groups at different doses has pronouncedly lowered the serum ALP level as was done by silymarin. In M100 and M200, level of serum ALP has been significantly ($P < 0.05$) lowered down, whereas in M300 group, serum ALP level was highly significantly ($P < 0.001$) lowered down when compared against gentamicin induced nephrotoxic groups.

Histopathological assessment

The results of our study are cited in table 3. The results of our research revealed that histological findings of liver of control group were found normal. Whereas gentamicin treated group (figure 2c) showed moderate histological changes such as fatty changes, presence of centrilobular necrosis, inflammatory infiltrate and congested blood vessels. Silymarin treated group (figure 2b) showed mild fatty changes and congested blood vessels while centrilobular necrosis and inflammatory infiltrate were not detected. M100 (figure 3d) and M200 (figure 3e) treated groups showed sever fatty changes, moderate congested blood vessels and mild

centrilobular necrosis and inflammatory filtrate. While histological examination of M300 (figure 3f) treated group revealed improvement in morphological changes such as there were minimal congested blood vessels and no other histological changes were observed.

Discussion

Liver is the vital organ of the body and plays major role in detoxification and elimination of various metabolic products and drugs metabolites. Gentamicin causes damaging effects to liver but the underline causes is still unclear, although the elevated serum ALP and SGPT level has been linked with gentamicin administration (1). It has been established that aminoglycosides stimulate the production of free radicals and modify antioxidant enzymes system which results in tissue injury and it has also been reported that gentamicin modifies the activity of hepatic glycogen phosphorylase and leads to less glycogen content of liver (2). The activities of SGPT and ALP are measured as parameters for liver function test. The elevation of serum level of SGPT is indicative of damage to hepatocytes. Oxidative stress is the responsible mechanism for hepatocytes damage and disease condition. Gentamicin suppresses the enzymatic antioxidants as well as non-enzymatic and causes increase generation of ROS which in turn drastically

affect phospholipids membranes but also damage the membrane proteins and nucleic acids. As a result liver damage and hepatotoxicity occurs (20).

Our research findings confirmed that 100mg/kg dose of gentamicin has significantly ($P < 0.001$) elevated the serum SGPT and ALP level which indicates that gentamicin has significantly induced hepatotoxicity and the co administration of MEDM has significantly lowered down the elevated serum SGPT and ALP level at different doses. This reversal of serum SGPT and ALP level is indicative of improvement of antioxidant defense system which is the reason for hepatoprotective effect. Thus the hepatoprotective effect of MEDM is considered to be because of the improvement in antioxidant defense system which is already reported by Alabri *et al.*, 2014, that MEDM possess strong antioxidant activity (11). Therefore the result of our study has shown that MEDM exhibit hepatoprotective effect. The exact mechanism behind the hepatoprotective effect is still not known but it might be considered that MEDM possess this hepatoprotective effect because of the free radical scavenging and antioxidant effect of MEDM as already reported. The present study has opened up new areas for further research for the therapeutic managements of liver disorders. Therefore, further extensive and multi-dimensional research should be continued for further elucidation of the exact hepatoprotective mechanism for MEDM for clinical practices to treat the patients with liver failure. Therefore, it was considered that MEDM exerts hepatoprotective effect because of free radical scavenging and antioxidant effect of MEDM. Alabri has already established the antioxidant effect of MEDM (11).

Aminoglycosides have been widely used therapeutically but nowadays their therapeutic use is limited due to nephrotoxicity and hepatotoxicity (22). Drugs induce hepatotoxicity by different mechanisms such as mitochondrial dysfunction. Drugs modifies the functions of liver mitochondria which stimulates necrosis leading to cystolytic hepatitis, culminating in hepatic failure (23). Aminoglycosides enhances the cellular permeability as well as interfere in signal transduction (24). Bellés *et al.*, 2007, has reported that in different tissues, aminoglycosides modifies the functions of antioxidant enzymes which includes glutathione peroxidase, superoxide dismutases and glutathione reductase, leading to impaired functioning of antioxidant enzyme system (25). Lietz and Brya reported that hepatic glycogen phosphorylase functioning is disrupted by aminoglycosides resulting in reduction of hepatic glycogen content (2). Serum SGPT and ALP has been used as biological markers for liver function tests (26). Bendush and his coworker reported that aminoglycosides elevate the serum SGPT level (27). The histological results (figure 2 and 3) of our study confirmed that gentamicin at a dose of 100mg/kg has significantly induced hepatotoxicity which is also indicated in the concerned biochemical analysis (figure 1).

Different chemical groups such as glycoside, flavonoids and alkaloids have therapeutic values. Flavonoids have been reported to be effective against hepatotoxicity due to its radical scavenging and antioxidant effect (28). Shakya *et al.*, 2014, has reported that kaempferol has antioxidant activity and exhibit hepatoprotective role against oxidative stress (29). Different chemical groups

such as glycosides, flavonoids and withanolides have been detected *D. metel* (30-33). Mai *et al.*, 2017, has reported the presence of kaempferol in *D. metel* which has radical scavenging and antioxidant effect (5).

Histological examination revealed in our study that silymarin has marked hepatoprotective effect on hepatocytes by significantly recovering the fatty changes, centrilobular necrosis, inflammatory infiltrate and congested blood vessels (induced by gentamicin). Different doses of MEDM such as 100mg/kg, 200mg/kg and 300 mg/kg have been injected to check the hepatoprotective effect of MEDM. 100mg/kg and 200 mg/kg doses did not produce hepatoprotective effect whereas 300 mg dose (figure3) revealed markedly improvement in recovering the fatty changes, centrilobular necrosis, inflammatory infiltrate and congested blood vessels.

In summary, MEDM might exhibit the hepatoprotective action because of the flavonoids group. As the hepatoprotective effect of kaempferol has been already reported so it may be assumed that the hepatoprotective effect of MEDM is due to the kaempferol (flavonoid). However, further research and elucidation should be carried out to find out the exact mechanism of hepatoprotection of MEDM.

As both, the biochemical and histological findings proved that MEDM has significantly reversed the elevated levels of SGPT and ALP and also reversed the histological damages, caused by gentamicin. Thus the result of biomarkers and histological findings has provided a scientific background to the hepatoprotective like effect of MEDM. The hepatoprotective effect might be due to the antioxidant and free radical scavenging activity of the MEDM which has already been reported. However, the exact mechanism is not known yet for the hepatoprotective like effect of MEDM. Therefore, further scientific research and elucidation is needed to find out the exact hepatoprotective mechanism of action of MEDM.

Funding

No grants were allocated for this study.

Conflict of interest

The authors of this article have no conflict of interest.

Acknowledgments

We are very thankful to KMU and PCSIR Laboratories for providing experimental facilities.

References

1. Arjinajarn P, Chueakula N, Pongchaidecha A, Jaikumkao K, Chatsudthipong V, Mahatheeranont S, et al. Anthocyanin-rich Riceberry bran extract attenuates gentamicin-induced hepatotoxicity by reducing oxidative stress, inflammation and apoptosis in rats. *Biomedicine & Pharmacotherapy*. 2017;92:412-20.
2. Lietz T, Brya J. The effect of various aminoglycoside antibiotics on glycogen phosphorylase activity in liver and kidney medulla of rabbit. *Acta Biochimica Polonica*. 1990;37(1):187-90.
3. Talele BD, Mahajan RT, Chopda MZ, Nemade NV. Nephroprotective plants: a review. *International Journal of Pharmacy and Pharmaceutical Sciences*. 2012;4(1):8-16.
4. Vaya RK, Sharma A, Singhvi I, Agarwal DK. Nephroprotective Plants: A Review. *Journal of Bioscience and Technology*. 2017;8:801-

- 12.
5. Mai NT, Cuc NT, Quang TH, Van Kiem P. Flavonol and lignan glycosides from *Datura metel* L. *Vietnam Journal of Science and Technology*. 2017;55(3):263-70.
6. Ara T, Khokan EH, Rahman A. Taxonomic Studies on the Family Solanaceae in the Rajshahi University Campus. *Journal of Biodiversity and Environmental Sciences*. 2011;4(1):29-34.
7. De Britto AJ, Gracelin DHS. *Datura metel* Linn.-A plant with potential as antibacterial agent. *International Journal of Applied Biology and Pharmaceutical Technology*. 2011;2(2):429-33.
8. Rajesh, Sharma GL. Studies on antimycotic properties of *Datura metel*. *Journal of Ethnopharmacology*. 2002;80:193-7.
9. Al-Snafi AE. Medical importance of *Datura fastuosa* (syn: *Datura metel*) and *Datura stramonium*-A review. *IOSR Journal of Pharmacy*. 2017;7(2):43-58.
10. Anju D, Ratan L. Phytochemical and pharmacological status of *Datura fastuosa* Linn. *International Journal of Research in Ayurveda and Pharmacy*. 2011;2(1):145-50.
11. Alabri THA, Al Musalami AHS, Hossain MA, Weli AM, Al-Riyami Q. Comparative study of phytochemical screening, antioxidant and antimicrobial capacities of fresh and dry leaves of crude plant extracts of *Datura metel* L. *Journal of King Saud University-Science*. 2014;26(3):237-43.
12. Hossain MA, Al Kalbani MSA, Al Farsi SAJ, Weli AM, Al-Riyami Q. Comparative study of total phenolics, flavonoids contents and evaluation of antioxidant and antimicrobial activities of different polarities fruits crude extracts of *Datura metel* L. *Asian Pacific Journal of Tropical Disease*. 2014;4(5):378-83.
13. Vijayaprakash S, Langeswaran K, Kumar SG, Revathy R, Balasubramanian MP. Nephro-protective significance of kaempferol on mercuric chloride induced toxicity in Wistar albino rats. *Biomedicine & Aging Pathology*. 2013;3(3):119-24.
14. OECD. Guidelines for the testing of chemicals revised draft guideline 423: Acute Oral Toxicity, France: OECD. 2000;2000.
15. Harlalka GV, Patil CR, Patil MR. Protective effect of *Kalanchoe pinnata* pers. (Crassulaceae) on gentamicin-induced nephrotoxicity in rats. *Indian Journal of Pharmacology*. 2007;39(4):201.
16. Lakshmi B, Sudhakar M. Protective effect of *Zingiber officinale* on gentamicin-induced nephrotoxicity in rats. *International Journal of Pharmacology*. 2010;6(1):58-62.
17. Nabavi SF, Nabavi SM, Moghaddam AH, Naqinezhad A, Bigdelou R, Mohammadzadeh S. Protective effects of *Allium paradoxum* against gentamicin-induced nephrotoxicity in mice. *Food & Function*. 2012;3(1):28-9.
18. Cos K, Özge U, Üstündag N, Omunog L, Sanem G OK EN Selma B, and Mütgan C. Gentamicin-Induced Nephrotoxicity in Rats Ameliorated and Healing Effects of Resveratrol. *Biological and Pharmaceutical Bulletin*. 2007;30(1):79-83.
19. Ali BH, Al-Wabel N, Mahmoud O, Mousa HM, Hashad M. Curcumin has a palliative action on gentamicin-induced nephrotoxicity in rats. *Fundamental & Clinical Pharmacology*. 2005;19:473-7.
20. Galaly S, Ahmed O, Mahmoud A. Thymoquinone and curcumin prevent gentamicin-induced liver injury by attenuating oxidative stress, inflammation and apoptosis. *Journal of Physiology and Pharmacology*. 2014;65(6):823-32.
21. Abdel-Raheem IT, Abdel-Ghany AA, CA bGAM, Naughton. Protective Effect of Quercetin against Gentamicin-Induced Nephrotoxicity in Rats. *Biological and Pharmaceutical Bulletin*. 2009;32(1):61-7.
22. Noorani AA, Gupta K, Bhadada K, Kale M. Protective effect of methanolic leaf extract of *Caesalpinia bonduc* (L.) on gentamicin-induced hepatotoxicity and nephrotoxicity in rats. *Iranian Journal of Pharmacology and Therapeutics*. 2011;10(1):21-0.
23. Aboubakr M, Abdelazem AM. Hepatoprotective effect of aqueous extract cardamom against gentamicin-induced hepatic damage in rats. *International Journal of Basic and Applied Sciences*. 2016;5:1-4.
24. Schacht J, Weiner N. Aminoglycoside-induced hearing loss: a molecular hypothesis. *Journal For Oto-Rhino-Laryngology, Head and Neck Surgery*. 1986;48(2):116-23.
25. Bellés M, Linares V, Luisa Albina M, Sirvent J, Sánchez DJ, Domingo JL. Melatonin reduces uranium-induced nephrotoxicity in rats. *Journal of Pineal Research*. 2007;43(1):87-95.
26. Moselhy, S S, Ali, KH H. Hepatoprotective effect of cinnamon extracts against carbon tetrachloride induced oxidative stress and liver injury in rats. *Biological research*. 2009;42(1):93-8.
27. Bendush, L C, Weber, Ruth. Tobramycin sulfate: a summary of worldwide experience from clinical trials. *Journal of Infectious Diseases*. 1976;134(Supplement_1):S219-S34.
28. Kim SM, Kang K, Jho EH, Jung YJ, Nho CW, Um BH, et al. Hepatoprotective effect of flavonoid glycosides from *Lespedeza cuneata* against oxidative stress induced by tert-butyl hydroperoxide. *Phytotherapy Research*. 2011;25(7):1011-7.
29. Shakya G, Manjini S, Hoda M, Rajagopalan R. Hepatoprotective role of kaempferol during alcohol-and Δ PUFA-induced oxidative stress. *Journal of Basic and Clinical Physiology and Pharmacology*. 2014;25(1):73-9.
30. Gupta M, Manickam M, Sinha SC, Sinha-Bagchi A, Ray AB. Withanolides of *Datura metel*. *Phytochemistry*. 1992;31(7):2423-5.
31. Ma L, Xie CM, Li J, Lou FC, Hu LH. Daturametelins H, I, and J: three new withanolide glycosides from *Datura metel* L. *Chemistry & Biodiversity*. 2006;3(2):180-6.
32. Ratan L, Meenu B, Anju D, Arun N. Morpo-anatomical and physicochemical studies of dried seeds of *Datura fastuosa* Linn. *International Research Journal of Pharmacy*. 2011;2(3):208-12.
33. Shingu K, Furusawa Y, Nohara T. New Withanolides, Daturametelins C, D, E, F and G-Ac from *Datura metel* L. (Solanaceous Studies. XIV). *Chemical and Pharmaceutical Bulletin*. 1989;37(8):2132-5.