



Original Article

## The effect of vitamin E incorporated into injectable platelet-rich fibrin on orthodontic tooth movement in rabbits

Mahmoud Kanan Mohsin, Zana Qadir Omer

Department of Pedodontics, Orthodontics and Preventive Dentistry, College of Dentistry, Hawler Medical University, Erbil, Kurdistan Region, Iraq



### Article Info



### Article history:

Received: January 27, 2024

Accepted: March 14, 2024

Published: June 30, 2024

Use your device to scan and read the article online



### Abstract

To evaluate the effects of injectable platelet fibrin (iPRF) and combined vitamin E-iPRF on orthodontic tooth movement (OTM) rates in rabbits, 35 male New Zealand white rabbits were involved in this study using split-mouth design. OTM was carried out on the mandibular first premolar using 100g nickel titanium closing coil. Right side served as study group, isolated iPRF in one group and combined vitamin E-iPRF in other group was injected buccally and lingually (iPRF group, Vit E-iPRF group), and left side acted as positive control group (CG) by injecting normal saline (positive CG). The rate of OTM was measured using intra-oral scanner on days 7, 14 and 21. Histological and Micro CT scan were examined on days 0, 7, 14 and 21. The iPRF and combined Vitamin E-iPRF demonstrated significant greater rate of OTM on days 7 and 14 in comparison to control group, only significant differences between iPRF and combined vitamin E-iPRF were seen on day 14. In all time intervals as compared to the CG, the number of osteoclasts was significantly higher in the isolated iPRF and combined vitamin E-iPRF groups. Significant reduction in bone volume fraction (BV/TV) was demonstrated in iPRF and combined vitamin E-iPRF groups in all time points, however, non-significant differences were found in trabecular thickness (Tb.Th) and trabecular separation (Tb.Sp). Local injection of iPRF and combined vitamin E-iPRF showed temporary increase in the rate of OTM.

**Keywords:** Orthodontic tooth movement, Vitamin E, Injectable platelet-rich fibrin, Micro-computed tomography, Rabbits.

### 1. Introduction

Orthodontic tooth movement (OTM), is the consequence of a two-phase process of resorption of bone on the compression side and deposition of bone on the tension side that remodels the periodontal ligament and alveolar bone. An initial inflammatory response is categorized by enhanced vascular permeability and migration of leukocytes that are carried by orthodontic force. These migrating cells produce inflammatory cytokines, which comprise growth factors, lymphocyte-derived factors and chemotactic factors. Increased bone turnover leads to bone remodeling, as seen in the infiltration of circulating osteoclast precursors and the promotion of osteoclast activation and production. As a result, increased cytokine expression during bone remodeling could accelerate OTM [1].

According to previous studies, the period of comprehensive orthodontic treatment could take long duration of time up to 24-36 months in adults, basically depending on amount of OTM [2, 3]. Many complications arise from long treatment time such as; root resorption, caries, gingivitis, formation of white spot lesions and loss of patient cooperation [4]. Reducing the duration of orthodontic therapy is challenging, for both orthodontists and patients

seeking orthodontic treatment [5].

To accelerate the OTM rate, several invasive and non-invasive methods were recently tried. Invasive methods, like piezocision [6], micro-osteoperforation [7], piezopuncture [8], corticision [9], corticotomy [10] periodontally accelerated osteogenic orthodontics (PAOO) [11] and dentoalveolar distraction [12] that apply the regional acceleratory phenomenon and cause increasing the OTM rate. Despite being referred to be minimally invasive surgical procedures, these invasive approaches can have certain adverse effects, including: post-treatment root resorption, alveolar bone resorption, and decreased alveolar bone density [12]. Therefore, non-invasive techniques such as low-dose laser therapy [13], vibration [14], and medications such as relaxin [15,16], prostaglandin [17] and vitamin D [18] investigated to increase OTM in order to avoid numerous risks associated with invasive methods.

Blood concentrates such as platelet-rich plasma (PRP) [19, 20] and platelet-rich fibrin (PRF) [21-25] are currently utilized as non-invasive techniques that increase the process of OTM. Platelet-rich fibrin (PRF) is a second-generation platelet concentrate, according to certain reports. The PRF is made of a three-dimensional fibrin matrix

\* Corresponding author.

E-mail address: [mahmoud.kanan@hmu.edu.krd](mailto:mahmoud.kanan@hmu.edu.krd) (K. Mohsin).

Doi: <http://dx.doi.org/10.14715/cmb/2024.70.6.23>

that can hold different types of blood cells. The PRF is abundant with autologous leukocytes, platelets, cytokines and growth factors and that guide the different cells in the remodeling process of local tissue by stimulating the formation of extracellular matrix, angiogenesis, cell proliferation, differentiation and chemotaxis [26]. PRF is easy to apply, autogenous, minimally invasive, repeatable, low cost and prevents procedure complications [27, 28]. The liquid injectable form of PRF (iPRF), is generated using nonadditive and contains more growth factors and regenerative cells than other types of PRF due to its low centrifugation speed [29].

Vitamin E is a strong lipid-soluble antioxidant that prevents cell damage by removing reactive oxygen species [30]. In addition, vitamin E has been shown to have anti-inflammatory, anti-platelet aggregation, and immune-boosting properties [31]. Studies on both humans and animals revealed that vitamin E has variable impacts on bone turnover and density [32–35].

The effect of incorporated vitamin E with iPRF on the rate of OTM, histological changes and alveolar bone microstructures using micro-CT at compression side under continuous mechanical force has not been studied.

Thus, the objective of this study was to find out how well applying isolated iPRF and vitamin E-iPRF together affected the rate of OTM in rabbits.

## 2. Materials and Methods

### 2.1. Study design

The current study was carried out in compliance with ARRIVE criteria [36], and the Scientific and Ethical Committee of Hawler Medical University's College of Dentistry, Kurdistan Region of Iraq, provided ethical permission. Thirty-five male New Zealand (*Oryctolagus cuniculus*) rabbits, 16-18 weeks old, 2.8 to 3.8 Kg in body weight with normal development of dentition were utilized in this experimental study. Five rabbits were randomly allocated and used for the baseline group at day 0 without any interventional procedure (Negative control). The remaining thirty rabbits were randomly split into two different groups using simple random allocation method: iPRF group (N = 15) and combined Vitamin E ( $\alpha$ -tocopherol)-iPRF group (N = 15). Three-time intervals were investigated on days 7, 14 and 21. Five rabbits were used for each time interval for both iPRF and combined Vitamin E-iPRF groups. In every rabbit, a randomized split-mouth design was used. The rabbits were randomly divided into two groups: the experimental group, which was given one dosage of injection (iPRF and Vitamin E-iPRF) on the right side of the mandible, and the CG, which was given normal saline solution on the left (positive CG). For the injection and rehabilitation on the buccal and lingual sides, all local administrations were administered just once on day 0 in identical quantities using a similar technique.

The rabbits were maintained in animal house under regular conditions with 12 hours of day and night cycle. To reduce the frequency of appliance breakage, animals were provided with a free supply of a soft diet.

The entire treatment was performed under general anesthesia using intramuscular injections of a combination of xylazine hydrochloride (dosage 5 mg/kg; Rompun; Bayer, Berlin, Germany) and ketamine hydrochloride (dose 25 mg/Kg; Alfasan International B.V., Woerden, Netherlands).

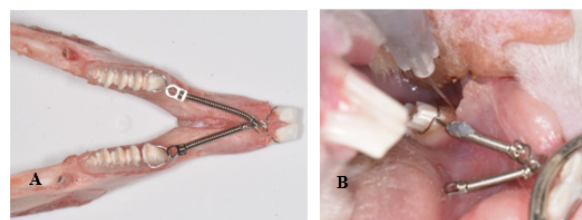
### 2.2. iPRF preparation and application

Each rabbit's central auricular artery was used to aspirate 10 milliliters of autologous blood into a collecting tube. Without adding any anticoagulants, the aspirated samples of blood were promptly placed in centrifuge tubes, and the tubes were then centrifuged. The setting of centrifuge was adjusted to 700 rpm at room temperature for 3 minutes with Choukroun PRF Duo Centrifuge (Process for PRF, Nice, France). From the top of the tubes, one milliliter of iPRF was extracted [37].

### 2.3. Orthodontic procedures

A specially customized operating surgical table was designed to aid in intraoral orthodontic procedures (Fig 1. A). Also, a pair of a specially designed cheek retractor made of cold cure acrylic were used. The orthodontic appliance utilized to encourage OTM resembled the model utilized by Pithon and Ruellas [38]. Stainless steel ligature wire size 0.010 inch was utilized to stretch a 12 mm Nickel-Titanium closed coil spring (ORMCO Co., USA) between the mandibular first premolars and mandibular incisors bilaterally, applying 100 gm of force. The applied force was standardized by measuring the force magnitude with a force gauge (Dentaurum, Ispringen, Germany). In order to inhibit slipping of the appliance, a 0.5 mm notch was created with a diamond round disc (Ortho Technology, Inc.; Tampa, FL, USA) at the level of gingival margin on both distal surfaces of the right and left mandibular incisors. The ligature wires were secured in the notches and a flowable composite (Filtek Bulk 3M ESPE Dental Products, Saint Paul, Minn) was used to fix the wires to the mandibular incisors. The other end of the springs was stretched and wrapped by ligature wire around mandibular first premolar. Furthermore, the right and left incisors were tied together by ligature wire to act as one unit in order to minimize the distal movement of incisors and enhance the anterior anchorage. At each time point, the appliance's retention was examined to make sure it was undamaged.

The Submucosal injection was carried out using a 1 ml insulin syringe with a 31-gauge needle (Insumed 31G Insulin Syringe 31G 3×8 mm; Pic solution, Artsana, Grandate, Italy) close to the mesial side of the lower first premolar [39] (Fig 1. B), injecting 0.5 ml of iPRF (0.25 ml buccally and 0.25 ml lingually) in iPRF group just after the appliance insertion [40]. For Vit E + iPRF group, 0.1 ml of Vitamin E (d- $\alpha$ -tocopherol, Deba Pharma Company, Kortrijk, Belgium) was added to 0.5 ml of iPRF and injected in an equal amount in buccal and lingual side. The injections were given only one time on day 0, and the left side (control side) received the same volume of normal saline.



**Fig. 1.** A. Design of orthodontic tooth movement model. B. Submucosal injection of iPRF.

## 2.4. Measurement of the tooth movement distance

Mandibular dental casts of all animals were constructed from impression materials at each of three time points (7, 14 and 21 days) immediately after sacrifice. Pre-fabricated color-coded custom-made trays were filled with injection silicone vinyl polysiloxane impression material. (3M ESPE Express Vinyl Polysiloxane Impression Material Fast Set; 3M ESPE Dental Products, Saint Paul, Minn). After that the impressions were poured with die stone. (Elite Rock Dental Stone, Zhermack, Badia Polesine, Rovigo, Italy). Consequently, the casts were scanned with three-dimensional (3D) scanner (Trios3; 3Shape, Copenhagen, Denmark) to make 3D digital models and saved in stereolithography (STL) file format. The rate of OTM in digital models was measured by using Ortho Analyzer software, version 1.7.1.0 (3Shape, Copenhagen, Denmark). The distal surface of the first premolar's crown and the mesial surface of the second premolar's crown were measured using the digital caliper feature of the 3Shape Ortho Analyzer program. Following three repetitions of each measurement, the mean was calculated and used to represent the final rate.

## 2.5. Micro-computed tomography (Micro CT) analysis

At each interval, a fatal dose of thiopental sodium was used to scarify the animals (0, 7, 14, and 21 days). Within 24 hours, the mandibles were dissected and then preserved in 10% neutral buffered formalin. The region of interest (ROI) of the alveolar bone was selected on the mesial surface of the cervical third of lower first premolar, which represented as compression side (Fig. 2), using Micro-Computed Tomography scanner (micro-CT, LOTUS in Vivo, Tehran, Iran). The time of frame exposure was set to one second by 1.4 magnifications, while the X-ray tube's current and voltage were adjusted to 70  $\mu$ A and 60 kV, respectively. The entire scanning time was thirty minutes and the thickness of the slices of reconstructed images of the samples was put to 25 micrometers. All the procedure settings were managed by LOTUS -in Vivo-ACQ software. LOTUS in Vivo-REC was used to reconstruct the acquired 3D data using the Feld-Kamp, Davis, Kress (FDK) algorithm. The following microstructural parameters were assessed: bone volume fraction (BV/TV%), Tb.Th. (mm) and trabecular separation Tb.Sp. (mm).

## 2.6. Histological analysis

Following a mandibular micro-CT scan, the soft tissue within the mandibles was shaved and split into two halves. Each sample was preserved for a day in 10% formalin, then it was decalcified with 10% nitric acid, dried in ethanol baths (70–100%), cleaned with xylene, embedded in paraffin wax, and sectioned at 5  $\mu$ m using rotary microtomes (Leica TP 1020, Germany). Three slices of each specimen were randomly chosen and stained with Haematoxylin and

Eosin (H&E) for light microscope assessment. The slides were observed under light microscope (Labomed LX300, USA) installed with Image J software analyzer (ImageJ bundled with Java 1.8.0\_172). The mandibular first premolar tilting movement led to the detection of the cervical thirds of the alveolar bone for histological examination. Under a light microscope, the number of osteoclasts and the region of the active bone-resorptive lacunae were measured at the cervical third of alveolar bones along the mesial side of the lower first premolar root. All assessments were triplicated, the means were taken. For data analysis, five microscopic fields from each slide were selected at random.

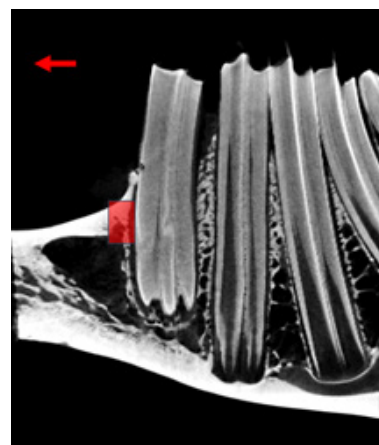
## 2.7. Statistical analysis

Statistical analysis was performed using SPSS version 25 (IBM, Armonk, NY, USA). Data were presented as mean and standard deviation (SD) for each group. To examine and assess the significance of the differences between the groups, One-way Analysis of Variance (ANOVA) was used. P-values of less than 0.05 were regarded as statistically significant, and each difference's significance was then assessed using Tukey's post hoc test.

## 3. Results

### 3.1. Measurement of the rate of OTM

The rabbits responded effectively to the experimental procedures, and the body weight of the animals was unaffected by the orthodontic appliances. None of the animals in the experiment showed any signs of inflammation at the location of the local injection. Mean and standard deviations of OTM are shown in Table 1. The rate of OTM increased from 7 days to 21 days in all groups, but Vit E-iPRF group showed greater OTM than the other two groups at all observation times. significant differences between the groups on days 7 and 14 (P value 0.002 and 0.001 respectively), while there were non-significant differences on day



**Fig. 2.** ROI mesial to mandibular first premolar (red area), red arrow represent direction of tooth movement.

**Table 1.** The level of OTM in individual time intervals.

Time	Positive Control	iPRF	Vit E-iPRF	P-Value
7 days	0.547 $\pm$ 0.028 <sup>b,c</sup>	0.661 $\pm$ 0.029 <sup>a</sup>	0.708 $\pm$ 0.086 <sup>a</sup>	0.002
14 days	0.702 $\pm$ 0.041 <sup>b,c</sup>	0.815 $\pm$ 0.057 <sup>a,c</sup>	0.923 $\pm$ 0.032 <sup>a,b</sup>	0.001
21 days	0.919 $\pm$ 0.080	0.997 $\pm$ 0.041	1.026 $\pm$ 0.072	0.067

One-way ANOVA test followed by Tukey's test was used. <sup>a</sup> Significant difference compared with Positive Control (P < .05). <sup>b</sup> Significant difference compared with iPRF (P < .05). <sup>c</sup> Significant difference compared with Vit E-iPRF (P < .05).

**Table 2.** Microstructural parameters of trabecular bone on the compression side of the mandibular first premolar at different time intervals.

Microstructural parameters	Time Interval	Negative Control	Positive Control	iPRF	Vit E+iPRF	P value
BV/TV %	7 days	70.57±2.86 <sup>a,b,c</sup>	42.14±4.14 <sup>b,c,d</sup>	32.90±3.24 <sup>a,d</sup>	27.62±1.45 <sup>a,d</sup>	0.001
	14 days	70.57±2.86 <sup>a,b,c</sup>	36.03±2.98 <sup>b,c,d</sup>	24.22±3.76 <sup>a,d</sup>	20.17±2.23 <sup>a,d</sup>	0.001
	21 days	70.57±2.86 <sup>a,b,c</sup>	28.88±2.34 <sup>b,c,d</sup>	19.65±2.702 <sup>a,d</sup>	16.50±1.96 <sup>a,d</sup>	0.001
Tb. Th (mm)	7 days	0.32±0.01 <sup>a,b,c</sup>	0.134±0.011 <sup>d</sup>	0.128±0.01 <sup>d</sup>	0.121±0.01 <sup>d</sup>	0.001
	14 days	0.32±0.01 <sup>a,b,c</sup>	0.131±0.01 <sup>d</sup>	0.114±0.01 <sup>d</sup>	0.112±0.007 <sup>d</sup>	0.001
	21 days	0.32±0.01 <sup>a,b,c</sup>	0.116±0.012 <sup>d</sup>	0.105±0.014 <sup>d</sup>	0.104±0.006 <sup>d</sup>	0.001
Tb. Sp (mm)	7 days	0.113±0.01	0.118±0.011	0.125±0.007	0.131±0.0072	0.096
	14 days	0.113±0.01	0.124±0.013	0.135±0.011	0.139±0.0141	0.08
	21 days	0.113±0.01 <sup>b,c</sup>	0.128±0.008	0.140±0.013 <sup>a</sup>	0.149±0.0097 <sup>a</sup>	0.008

One-way ANOVA test followed by Tukey's test was used. <sup>a</sup> Significant difference compared with Positive Control ( $P < .05$ ). <sup>b</sup> Significant difference compared with iPRF ( $P < .05$ ). <sup>c</sup> Significant difference compared with Vit E-iPRF ( $P < .05$ ). <sup>d</sup> Significant difference compared with Negative Control ( $P < .05$ ).

21 (P value 0.067). In the combined Vit E-iPRF group, the level of OTM was greater than in the other groups during the whole time interval; however, only on day 7 and 14, statistically significant differences existed in comparison to positive control group. The amount of OTM in Vit E-iPRF group was significantly more than positive CG on day 7 ( $0.708 \pm 0.086$  mm vs.  $0.547 \pm 0.028$  mm), day 14 ( $0.923 \pm 0.032$  mm vs.  $0.702 \pm 0.041$  mm), however, the amount of OTM is greater on day 21 ( $1.026 \pm 0.072$  mm vs.  $0.919 \pm 0.080$  mm) but no significant differences reported between them.

### 3.2. Micro-CT evaluation of trabecular bone

Table 2 and Fig. 3 provide the mean±SD of the microstructural parameters for the trabecular bone mesial (compression side) to the root of the mandibular first premolars at various observational periods.

#### 3.2.1. Bone volume fraction (BV/TV%)

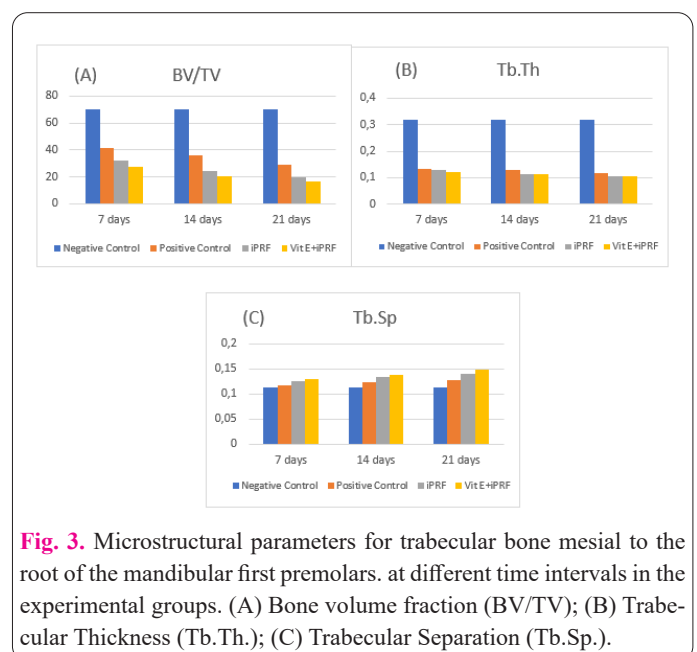
The results showed that the BV/TV ratio rapidly decreased from 0 day (negative CG) to 7 days after injection treatment on compression side in all three experimental groups. Significant differences were revealed among groups on days 7, 14 and 21 ( $P = 0.001$ ). Negative control had maximum BV/TV ratio ( $70.57 \pm 2.86$ ) and Vit E-iPRF on day 21 had maximum ratio ( $16.50 \pm 1.96$ ). There were extremely notable variations between the negative CG and every other group across every time period. Bone fraction in iPRF group was significantly decreased in all-time observations in comparison to negative and positive control, but no significant differences found between iPRF and Vit E-iPRF groups in all three times ( $P > 0.05$ ) (Table 2).

#### 3.2.2. Trabecular thickness (Tb.Th.)

Analysis of Tb. Th. revealed that there were substantial variations between the groups at every stage of the study (7 days, 14 days, 21 days) ( $P = 0.001$ ). Significant differences were found between negative CG and other groups in all time intervals ( $P = 0.001$ ), while no significant differences were calculated between positive CG and iPRF and Vit E+iPRF groups.

#### 3.2.3. Trabecular separation (Tb.Sp.)

Non-significant differences were observed between groups on days 7 and 14, while significant differences



**Fig. 3.** Microstructural parameters for trabecular bone mesial to the root of the mandibular first premolars. at different time intervals in the experimental groups. (A) Bone volume fraction (BV/TV); (B) Trabecular Thickness (Tb.Th.); (C) Trabecular Separation (Tb.Sp.).

were found on day 21 between groups ( $P = 0.008$ ). No significant differences existed between negative CG with positive control, iPRF and Vit E-iPRF groups in all time intervals except between negative control and iPRF group and Vit E-iPRF group on day 21.

### 3.3. Histological analysis

Table 3 displays the mean±SD of the histological changes in the area of active bone resorptive lacunae and the number of osteoclasts along the mesial side of the mandibular first premolar.

#### 3.3.1. Osteoclast No

Histomorphometric analysis showed that there were statistically significant differences among groups in osteoclast number at all time intervals ( $P$  value = 0.001). Between the negative CG and the other groups, a significant difference was determined at all periods. Furthermore, at all times, there were statistically significant differences between the positive CGs and the other groups. However, no significant differences showed between iPRF and Vit E-iPRF groups on days 7, 14 and 21. Maximum amount of osteoclast was found in Vit E-iPRF group on day 21 ( $12.60 \pm 1.14$ ), while minimum amount was calculated in

**Table 3.** The histological parameters.

Histological parameters	Time Interval	Negative Control	Positive Control	iPRF	Vit E+iPRF	P value
Osteoclast No/mm <sup>2</sup>	7 days	1.40 ±0.55 <sup>a,b,c</sup>	4.40 ±1.14 <sup>b,c,d</sup>	6.40±0.55 <sup>a,d</sup>	7.00±1.00 <sup>a,d</sup>	0.001
	14 days	1.40 ±0.55 <sup>a,b,c</sup>	7.60 ±0.55 <sup>b,c,d</sup>	10.00±0.71 <sup>a,d</sup>	11.40±1.14 <sup>a,d</sup>	0.001
	21 days	1.40±0.55 <sup>a,b,c</sup>	8.00 ±1.00 <sup>b,c,d</sup>	11.20±1.30 <sup>a,d</sup>	12.60±1.14 <sup>a,d</sup>	0.001
Active bone resorptive lacunae/mm <sup>2</sup>	7 days	0.018±0.004 <sup>a,b,c</sup>	0.098±0.01 <sup>b,c,d</sup>	0.228±0.04 <sup>a,d</sup>	0.224±0.03 <sup>a,d</sup>	0.001
	14 days	0.018±0.004 <sup>a,b,c</sup>	0.273±0.02 <sup>b,c,d</sup>	0.454±0.03 <sup>a,d</sup>	0.494±0.03 <sup>a,d</sup>	0.001
	21 days	0.018±0.004 <sup>a,b,c</sup>	0.382±0.03 <sup>b,c,d</sup>	0.704±0.04 <sup>a,c,d</sup>	0.840±0.05 <sup>a,b,d</sup>	0.001

One-way ANOVA test followed by Tukey's test was used. <sup>a</sup> Significant difference compared with Positive Control (P < .05). <sup>b</sup> Significant difference compared with iPRF (P < .05). <sup>c</sup> Significant difference compared with Vit E-iPRF (P < .05). <sup>d</sup> Significant difference compared with Negative Control (P < .05).

negative CG (1.40 ±0.55).

### 3.3.2. Active bone resorptive lacunae/mm<sup>2</sup>

The findings showed that, at all time periods, the experimental groups had a significantly higher active area of bone resorptive lacunae than the negative CG. In addition, significant differences were found among study groups on days 7, 14 and 21 (P value=0.001). Also, positive CG showed significant differences with other groups, while no significant differences were observed between iPRF and Vit E-iPRF groups on day 7 and 14, however on day 21 was significant. Maximum value was found in Vit E-iPRF group on day 21 (0.840±0.05) and minimum in negative CG (0.018±0.004).

## 4. Discussion

Patients frequently express annoyance over the extended duration of orthodontic treatments, which often exceed their initial expectations, leading to disappointment and waning motivation. Delays, attributed to factors like biological variability, unexpected complications, emphasize the importance of prevention strategies. These issues not only affect treatment timelines but also cause additional discomfort, underscoring the need for preventative measures. Setting realistic expectations and ensuring open communication between orthodontists and patients are crucial for preventing misunderstandings and effectively managing potential delays.

Orthodontic tooth movement is basically a biological reaction to a mechanical force. Prolonged application of controlled mechanical forces initiates the OTM by creating tension and compression zones in the alveolar bone and periodontal ligament, which remodels the tooth sockets and allows tooth movement [41]. This mechanical load influences osteoblastic and osteoclastic activity as well as modifies bone metabolism. Any factor that controls osteoblastic or osteoclastic activity, including growth factors, hormones, and inflammatory or proinflammatory cytokines, can also affect bone metabolism [42].

Platelet concentrates are derived from autologous blood of the patient or animals and offer a safe substitute for bioactive materials that are sold commercially. There are two types of platelet concentrates that vary in terms of content and methodology [27][43][44][45]. PRP is a type of platelet concentrate that was initially created by combining high platelet concentration with anticoagulants to activate the growth factors that were present [44]. PRF is a platelet concentrate of the second generation, produced at slower centrifugation rates without the addition of any

chemicals or anticoagulants [27][43][46]. Because iPRF requires a lower centrifuge speed, more natural and gradual polymerization will achieve that improve the spreading and integrity of soluble molecules such as cytokines in the fibrin network [27][43]. The effectiveness of iPRF also rises as a consequence of the extended and controlled release of cytokines[43].

Platelet concentrates (PRP, PRF) are known to include a variety of growth factors, including PDGF, PDEGF, EGF, IGF, VEGF, and TGF- $\beta$ . Platelet concentrate alters bone remodeling in favor of bone formation because of the presence of growth factors [42]. The application of PRF in dentistry has increased since 2011 because synthesis of PRF is a simple, reproducible, inexpensive, and trouble-free procedure. It can be produced from as small as 8–10 ml of autologous blood without the requirement for any heterogeneous agent, unlike PRP preparation; which requires addition of anticoagulant. Moreover, PRF has seven-fold higher release of growth factor in comparison to PRP. [47].

Vitamin E, a well-known antioxidant, is among the most extensively utilized supplements across the globe. Numerous studies have demonstrated the potential of vitamin E to influence bone metabolism [30].

To the best of our knowledge, this is the first study demonstrating how administering the combined Vitamin E and iPRF affects tooth movement. To detect whether Vitamin E boosts the effect of iPRF on OTM or has no any boosting effects, the effect of isolated iPRF and combined with vitamin E were assessed independently.

Adding vitamin E to iPRF is considered a biologically boosted iPRF. Sar et al studied the effect of combined PRF and piezo-incision on OTM, so piezo-incision acted as a mechanical boosting method to PRF[48].

The findings of the current investigation demonstrated that the local application of combined Vit E-iPRF accelerated OTM in all time intervals. There was significantly more OTM in Vit E-iPRF group than iPRF and positive CG on day 7 and 14. Non-significant changes were identified across groups in the third week; degradation of the iPRF and Vit E-iPRF after two weeks may have caused the condition [49]. This temporary rate of tooth movement indicates that repeated injections might be required for continuous effects [50]. Regarding iPRF group, the rates of OTM was greater than positive CG in all time points, these results agreed with the finding of earlier study, which demonstrated the positive effects of iPRF in enhancing OTM [51], also in agreement with other clinical studies on patients [52–54]. Furthermore, these findings favo-

rably corresponded with other experimental studies that carried out using PRP on animal models, they found that PRP positively increases the rate of OTM [40][44][55]. The greater concentration of growth factors and cytokines released by activated platelets in platelet concentrates may be the cause of the accelerated tooth movement. Releasing of molecules such as: platelet-derived growth factor, transforming growth factor- $\beta$  and vascular endothelial growth factor (VEGF), which affect the process of bone remodeling to cause cellular responses in the various cell types and create an environment that is favorable for tooth movement [56].

When compared to the negative CG, the use of iPRF alone resulted in an almost 4.5-fold increase in osteoclast cell counts on days 7, 14, and 21, and an 8-fold increase on days 21. These results are consistent with research by Sar et al. that found that osteoclast counts were greater than those of the untreated CG [48].

The differences between groups in all time observations are found to be significant in osteoclast and active resorptive lacunae. The increased osteoclast counts and active bone resorptive lacunae showed an increase in the rate of alveolar bone turnover, indicating accelerated tooth movement.

The study conducted by Fujita et al. demonstrated that a diet high in vitamin E increases osteoclast activity, which leads to bone loss [34]. On the other hand, Kasai et al. discovered that a diet high in vitamin E enhances bone metabolism and increases the osteoblast numbers [35]. The present study showed that gradually increased osteoclast numbers and decreased bone volume fraction BV/TV in Vit E-iPRF group from day 7 to 21, is consistent with that combined Vitamin E-iPRF being related to more bone loss. Seong et al. found that a diet high in vitamin E increases OTM [57]. In contrast to the results of earlier studies, local or systemic administration of vitamin E did not affect the OTM [58]. The highest number of osteoclasts is shown in group Vit E-iPRF on day 21. While Nakornnoi et al. [40] and Chen et al. [59] found that the peak of osteoclast number was in second week, PRP has been used in both studies in rabbit models.

Alveolar bone changes in pressure side of first premolar revealed that BV/TV in the Vit E-iPRF group is significantly less than iPRF and positive CGs on days 7 and 14 and non-significant on day 21, which correlated with more decrease in Tb.Th. It suggested that osteoclast-induced bone resorption on the trabecular bone's surface may have contributed to a larger drop in bone volume fraction. In a similar way, the Vit E-iPRF group demonstrated an increase in the Tb.Sp. as a result of bone resorption on the trabecular surface, which increases the distance between trabeculae. This result is consistent with previous study that showed that L-PRP decreases BV/TV and Tb.Th. in first and second week and increases Tb.Sp. [60].

Correlating the OTM, histological and Micro-CT scanning findings, this study shows that the local injection of iPRF and combined Vitamin E-iPRF could increase osteoclast numbers and area of active bone-resorptive lacunae which enhance the process of bone resorption. This might give a logical justification for the increase in the rate of OTM observed in the groups that received local administration of iPRF and combined vitamin E-iPRF.

There are some limitations of the current study. Ten-

sion side was not studied, to estimate the effects of iPRF and Vit E-iPRF on osteoblast activity. Furthermore, only single dose of injections was administered, further studies were required to examine the effects of multiple injections of iPRF, isolated Vitamin E and combined Vitamin E-iPRF on the rate of OTM.

## 5. Conclusion

The results of the current study showed that local injection of iPRF and combined vitamin E-iPRF significantly accelerated OTM on days 7 and 14, but non-significant differences were found on day 21 in comparison to CG. Furthermore, only in second week, there were significant differences between iPRF and combined vitamin E-iPRF in the rate of OTM. Osteoclast numbers were significantly increased in iPRF and combined Vit E-iPRF groups in all time points compared to CG, but non-significant differences were observed between iPRF and combined Vit E-iPRF groups in all time intervals.

## Conflict of interests

The author has no conflicts with any step of the article preparation.

## Consent for publications

After reading it, the author gave the final text the go-ahead to publish.

## Ethics approval and consent to participate

Ethical approval was obtained from the Scientific and Ethical Committee, College of Dentistry, Hawler Medical University, Kurdistan Region of Iraq.

## Informed consent

The authors declare not used any patients in this research.

## Availability of data and material

On request, data can be obtained from the appropriate author.

## Authors' contributions

Mahmoud Kanan Mohsin and Zana Qadir Omer performed all steps of present study.

## Funding

None

## Highlights

Vitamin E can be added to iPRF to enhance the OTM rate, the rate of OTM of vitamin E incorporated to iPRF is more than isolated iPRF.

## References

- Andrade I, Taddei SRA, Souza PEA (2012) Inflammation and Tooth Movement: The Role of Cytokines, Chemokines, and Growth Factors. *Semin Orthod* 18 (4): 257–269. doi: 10.1053/J.SODO.2012.06.004.
- Fisher MA, Wenger RM, Hans MG (2010) Pretreatment characteristics associated with orthodontic treatment duration. *Am J Orthod Dentofac Orthop Off Publ Am Assoc Orthod its Const Soc Am Board Orthod* 137 (2): 178–186. doi: 10.1016/j.ajodo.2008.09.028.

3. Alfawal AMH, Hajjeer MY, Ajaj MA, Hamadah O, Brad B (2016) Effectiveness of minimally invasive surgical procedures in the acceleration of tooth movement: a systematic review and meta-analysis. *Prog Orthod* 17 (1): 33. doi: 10.1186/s40510-016-0146-9.
4. Beckwith FR, Ackerman RJJ, Cobb CM, Tira DE (1999) An evaluation of factors affecting duration of orthodontic treatment. *Am J Orthod Dentofac Orthop Off Publ Am Assoc Orthod its Const Soc Am Board Orthod* 115 (4): 439–447. doi: 10.1016/s0889-5406(99)70265-9.
5. Aksakalli S, Calik B, Kara B, Ezirganli S (2016) Accelerated tooth movement with piezocision and its periodontal-transversal effects in patients with Class II malocclusion. *Angle Orthod* 86 (1): 59–65. doi: 10.2319/012215-49.1.
6. Dibart S, Sebaoun JD, Surmenian J (2009) Piezocision: a minimally invasive, periodontally accelerated orthodontic tooth movement procedure. *Compend Contin Educ Dent* 30 (6): 342-344,346,348-350.
7. Alikhani M, Raptis M, Zoldan B, Sangsuwon C, Lee YB, Alyami B, et al (2013) Effect of micro-osteoperforations on the rate of tooth movement. *Am J Orthod Dentofac Orthop Off Publ Am Assoc Orthod its Const Soc Am Board Orthod* 144 (5): 639–648. doi: 10.1016/j.ajodo.2013.06.017.
8. Kim Y-S, Kim S-J, Yoon H-J, Lee PJ, Moon W, Park Y-G (2013) Effect of piezopuncture on tooth movement and bone remodeling in dogs. *Am J Orthod Dentofac Orthop Off Publ Am Assoc Orthod its Const Soc Am Board Orthod* 144 (1): 23–31. doi: 10.1016/j.ajodo.2013.01.022.
9. Kim S-J, Park Y-G, Kang S-G (2009) Effects of Corticision on paradental remodeling in orthodontic tooth movement. *Angle Orthod* 79 (2): 284–291. doi: 10.2319/020308-60.1.
10. Pathomkulmai T, Chanmanee P, Samruajbenjakun B (2022) Effect of Extending Corticotomy Depth to Trabecular Bone on Accelerating Orthodontic Tooth Movement in Rats. *Dent. J.* 10
11. Wilcko WM, Wilcko T, Bouquot JE, Ferguson DJ (2001) Rapid orthodontics with alveolar reshaping: two case reports of decrowding. *Int J Periodontics Restorative Dent* 21 (1): 9–19.
12. Sukurica Y, Karaman A, Gürel HG, Dolanmaz D (2007) Rapid canine distalization through segmental alveolar distraction osteogenesis. *Angle Orthod* 77 (2): 226–236. doi: 10.2319/0003-3219(2007)077[0226:RCDTSA]2.0.CO;2.
13. Yoshida T, Yamaguchi M, Utsunomiya T, Kato M, Arai Y, Kaneda T, et al (2009) Low-energy laser irradiation accelerates the velocity of tooth movement via stimulation of the alveolar bone remodeling. *Orthod Craniofac Res* 12 (4): 289–298. doi: 10.1111/j.1601-6343.2009.01464.x.
14. Yadav S, Dobie T, Assefnia A, Gupta H, Kalajzic Z, Nanda R (2015) Effect of low-frequency mechanical vibration on orthodontic tooth movement. *Am J Orthod Dentofac Orthop Off Publ Am Assoc Orthod its Const Soc Am Board Orthod* 148 (3): 440–449. doi: 10.1016/j.ajodo.2015.03.031.
15. McGorray SP, Dolce C, Kramer S, Stewart D, Wheeler TT (2012) A randomized, placebo-controlled clinical trial on the effects of recombinant human relaxin on tooth movement and short-term stability. *Am J Orthod Dentofac Orthop Off Publ Am Assoc Orthod its Const Soc Am Board Orthod* 141 (2): 196–203. doi: 10.1016/j.ajodo.2011.07.024.
16. Madan MS, Liu ZJ, Gu GM, King GJ (2007) Effects of human relaxin on orthodontic tooth movement and periodontal ligaments in rats. *Am J Orthod Dentofac Orthop Off Publ Am Assoc Orthod its Const Soc Am Board Orthod* 131 (1): 8.e1-10. doi: 10.1016/j.ajodo.2006.06.014.
17. Yamasaki K, Shibata Y, Imai S, Tani Y, Shibasaki Y, Fukuhara T (1984) Clinical application of prostaglandin E1 (PGE1) upon orthodontic tooth movement. *Am J Orthod* 85 (6): 508–518. doi: 10.1016/0002-9416(84)90091-5.
18. Collins MK, Sinclair PM (1988) The local use of vitamin D to increase the rate of orthodontic tooth movement. *Am J Orthod Dentofac Orthop Off Publ Am Assoc Orthod its Const Soc Am Board Orthod* 94 (4): 278–284. doi: 10.1016/0889-5406(88)90052-2.
19. Desai A, Nambiar S, Unnikrishnan B, Rai S, Nayak S, Natarajan S (2023) Effect of a Submucosal Injection of Platelet-Rich Plasma on the Rate of Orthodontic Tooth Movement - A Split-Mouth, Single-Blind Randomized Controlled Trial. *Contemp Clin Dent* 14 (1): 39–44. doi: 10.4103/ccd.ccd\_419\_21.
20. Angel SL, Samrit VD, Kharbanda OP, Duggal R, Kumar V, Chauhan SS, et al (2022) Effects of submucosally administered platelet-rich plasma on the rate of tooth movement. *Angle Orthod* 92 (1): 73–79. doi: 10.2319/011221-40.1.
21. Tehranchi A, Behnia H, Pourdanesh F, Behnia P, Pinto N, Younessian F (2018) The effect of autologous leukocyte platelet rich fibrin on the rate of orthodontic tooth movement: A prospective randomized clinical trial. *Eur J Dent* 12 (3): 350–357. doi: 10.4103/ejd.ejd\_424\_17.
22. Yao K, Wu Y, Cai J, Wang Y, Shen Y, Jing D, et al (2022) The effect of platelet-rich concentrates on orthodontic tooth movement: A review of randomized controlled trials. 8 (9): e10604. doi: 10.1016/j.heliyon.2022.e10604.
23. Karakasli K, Erdur EA (2021) The effect of platelet-rich fibrin (PRF) on maxillary incisor retraction rate. *Angle Orthod* 91 (2): 213–219. doi: 10.2319/050820-412.1.
24. Shaker Al-Awady, M., & Mohammed Ali, B. (2024). Effect of vitamin D supplementation on glycemic control in type 1 diabetes mellitus. *Cell Mol Biomed Rep* doi: 10.55705/cnbr.2024.436594.1218.
25. Barhate UH, Duggal I, Mangaraj M, Sharan J, Duggal R, Jena AK (2022) Effects of autologous leukocyte-platelet rich fibrin (L-PRF) on the rate of maxillary canine retraction and various biomarkers in gingival crevicular fluid (GCF): A split mouth randomized controlled trial. *Int Orthod* 20 (4): 100681. doi: 10.1016/j.ortho.2022.100681.
26. Prakash S, Thakur A (2011) Platelet concentrates: past, present and future. *J Maxillofac Oral Surg* 10 (1): 45–49. doi: 10.1007/s12663-011-0182-4.
27. Dohan DM, Choukroun J, Diss A, Dohan SL, Dohan AJJ, Mouhyi J, et al (2006) Platelet-rich fibrin (PRF): a second-generation platelet concentrate. Part I: technological concepts and evolution. *Oral Surg Oral Med Oral Pathol Oral Radiol Endod* 101 (3): e37-44. doi: 10.1016/j.tripleo.2005.07.008.
28. Gassling VLW, Açil Y, Springer IN, Hubert N, Wiltfang J (2009) Platelet-rich plasma and platelet-rich fibrin in human cell culture. *Oral Surg Oral Med Oral Pathol Oral Radiol Endod* 108 (1): 48–55. doi: 10.1016/j.tripleo.2009.02.007.
29. Choukroun J, Ghanaati S (2018) Reduction of relative centrifugation force within injectable platelet-rich-fibrin (PRF) concentrates advances patients' own inflammatory cells, platelets and growth factors: the first introduction to the low speed centrifugation concept. *Eur J trauma Emerg Surg Off Publ Eur Trauma Soc* 44 (1): 87–95. doi: 10.1007/s00068-017-0767-9.
30. Song LS, Zhang ZX, Wang Y, Liu Y, Zhang R, Lu LJ (2017) Effects of nano-emulsion preparations of tocopherols and tocotrienols on oxidative stress and osteoblast differentiation. *Arch Biol Sci* 69 (1): 149–156. doi: 10.2298/ABS160208090S.
31. Singh U, Devaraj S, Jialal I (2005) Vitamin E, oxidative stress, and inflammation. *Annu Rev Nutr* 25 151–174. doi: 10.1146/annurev.nutr.24.012003.132446.
32. Shi W, Liu J, Cao Y, Zhu Y, Guan K, Chen Y (2016) Association of dietary and serum vitamin E with bone mineral density in

- middle-aged and elderly Chinese adults: a cross-sectional study. *Br J Nutr* 115 (1): 113–120. doi: 10.1017/S0007114515004134.
33. Zhang J, Hu X, Zhang J (2017) Associations between serum vitamin E concentration and bone mineral density in the US elderly population. *Osteoporos Int a J Establ as result Coop between Eur Found Osteoporos Natl Osteoporos Found USA* 28 (4): 1245–1253. doi: 10.1007/s00198-016-3855-5.
  34. Fujita K, Iwasaki M, Ochi H, Fukuda T, Ma C, Miyamoto T, et al (2012) Vitamin E decreases bone mass by stimulating osteoclast fusion. *Nat Med* 18 (4): 589–594. doi: 10.1038/nm.2659.
  35. Kasai S, Ito A, Shindo K, Toyoshi T, Bando M (2015) High-Dose  $\alpha$ -Tocopherol Supplementation Does Not Induce Bone Loss in Normal Rats. *PLoS One* 10 (7): e0132059. doi: 10.1371/journal.pone.0132059.
  36. Kilkenny C, Browne WJ, Cuthill IC, Emerson M, Altman DG (2010) Improving bioscience research reporting: The ARRIVE guidelines for reporting animal research. *J Pharmacol Pharmacother* 1 (2): 94–99. doi: 10.4103/0976-500X.72351.
  37. Miron RJ, Fujioka-Kobayashi M, Hernandez M, Kandalam U, Zhang Y, Ghanaati S, et al (2017) Injectable platelet rich fibrin (i-PRF): opportunities in regenerative dentistry? *Clin Oral Investig* 21 (8): 2619–2627. doi: 10.1007/s00784-017-2063-9.
  38. Pithon MM, Carlos A, Ruellas DO (2011) Histological evaluation of the phenobarbital ( Gardenal<sup>TM</sup> ) influence on orthodontic movement : a study in rabbits. *16 (4): 47–54.*
  39. AlSwafeeri H, ElKenany W, Mowafy M, Karam S (2019) Effect of local administration of simvastatin on orthodontic tooth movement in rabbits. *Am J Orthod Dentofac Orthop Off Publ Am Assoc Orthod its Const Soc Am Board Orthod* 156 (1): 75–86. doi: 10.1016/j.ajodo.2018.07.027.
  40. Nakornnoi T, Leethanakul C, Samruajbenjakun B (2019) The influence of leukocyte-platelet-rich plasma on accelerated orthodontic tooth movement in rabbits. *Korean J Orthod* 49 (6): 372–380. doi: 10.4041/kjod.2019.49.6.372.
  41. Krishnan V, Davidovitch Z (2006) Cellular, molecular, and tissue-level reactions to orthodontic force. *Am J Orthod Dentofac Orthop Off Publ Am Assoc Orthod its Const Soc Am Board Orthod* 129 (4): 469.e1–32. doi: 10.1016/j.ajodo.2005.10.007.
  42. Whitman DH, Berry RL, Green DM (1997) Platelet gel: an autologous alternative to fibrin glue with applications in oral and maxillofacial surgery. *J oral Maxillofac Surg Off J Am Assoc Oral Maxillofac Surg* 55 (11): 1294–1299. doi: 10.1016/s0278-2391(97)90187-7.
  43. Wang X, Zhang Y, Choukroun J, Ghanaati S, Miron RJ (2018) Effects of an injectable platelet-rich fibrin on osteoblast behavior and bone tissue formation in comparison to platelet-rich plasma. *Platelets* 29 (1): 48–55. doi: 10.1080/09537104.2017.1293807.
  44. Güleç A, Bakkalbaşı BÇ, Cumbul A, Uslu Ü, Alev B, Yarat A (2017) Effects of local platelet-rich plasma injection on the rate of orthodontic tooth movement in a rat model: A histomorphometric study. *Am J Orthod Dentofac Orthop Off Publ Am Assoc Orthod its Const Soc Am Board Orthod* 151 (1): 92–104. doi: 10.1016/j.ajodo.2016.05.016.
  45. Rashid A, ElSharaby FA, Nassef EM, Mehanni S, Mostafa YA (2017) Effect of platelet-rich plasma on orthodontic tooth movement in dogs. *Orthod Craniofac Res* 20 (2): 102–110. doi: 10.1111/ocr.12146.
  46. Öncü E, Bayram B, Kantarci A, Gülsever S, Alaaddinoğlu E-E (2016) Positive effect of platelet rich fibrin on osseointegration. *Med Oral Patol Oral Cir Bucal* 21 (5): e601-7. doi: 10.4317/medoral.21026.
  47. Dohan Ehrenfest DM, Del Corso M, Diss A, Mouhyi J, Charrier J-B (2010) Three-dimensional architecture and cell composition of a Choukroun's platelet-rich fibrin clot and membrane. *J Periodontol* 81 (4): 546–555. doi: 10.1902/jop.2009.090531.
  48. Sar C, Akdeniz SS, Arman Ozcirpici A, Helvacioğlu F, Bacanlı D (2019) Histological evaluation of combined platelet-rich fibrin membrane and piezo-incision application in orthodontic tooth movement. *Int J Oral Maxillofac Surg* 48 (10): 1380–1385. doi: 10.1016/j.ijom.2019.04.001.
  49. Kubesch A, Barbeck M, Al-Maawi S, Orłowska A, Booms PF, Sader RA, et al (2019) A low-speed centrifugation concept leads to cell accumulation and vascularization of solid platelet-rich fibrin: an experimental study in vivo. *Platelets* 30 (3): 329–340. doi: 10.1080/09537104.2018.1445835.
  50. Zeitounlouian TS, Zeno KG, Brad BA, Haddad RA (2021) Effect of injectable platelet-rich fibrin (i-PRF) in accelerating orthodontic tooth movement : A randomized split-mouth-controlled trial. *J Orofac Orthop = Fortschritte der Kieferorthopadie Organ/official J Dtsch Gesellschaft fur Kieferorthopadie* 82 (4): 268–277. doi: 10.1007/s00056-020-00275-x.
  51. Alaa S, Fouda AM, Grawish ME, Abdelnaby YL (2023) The effect of submucosal injection of platelet-rich fibrin vs. platelet-rich plasma on orthodontic tooth movement in rabbits; 28 days follow-up. *Int Orthod* 21 (1): 100715. doi: 10.1016/J.OR-THO.2022.100715.
  52. Erdur EA, Karakaslı K, Oncu E, Ozturk B, Hakkı S (2021) Effect of injectable platelet-rich fibrin (i-PRF) on the rate of tooth movement. *Angle Orthod* 91 (3): 285–292. doi: 10.2319/060320-508.1.
  53. Krishna V B, Duggal I, Sharan J, Mangaraj M, Duggal R, Jena AK (2023) Effect of leukocyte-platelet-rich fibrin (L-PRF) on the rate of orthodontic tooth movement and expression of various biomarkers in gingival crevicular fluid. *Clin Oral Investig* 27 (5): 2311–2319. doi: 10.1007/s00784-023-05026-x.
  54. Ammar AM, Al-Sabbagh R, Hajjeer MY (2024) Evaluation of the effectiveness of the platelet-rich plasma compared to the injectable platelet-rich fibrin on the rate of maxillary canine retraction: a three-arm randomized controlled trial. *Eur J Orthod.* doi: 10.1093/ejo/cjad056
  55. El-Timamy A, El Sharaby F, Eid F, El Dakroury A, Mostafa Y, Shaker O (2020) Effect of platelet-rich plasma on the rate of orthodontic tooth movement. *Angle Orthod* 90 (3): 354–361. doi: 10.2319/072119-483.1.
  56. Andrade Jr I, Taddei SRA, Souza PEA (2012) Inflammation and Tooth Movement : The Role of Cytokines , Chemokines , and Growth Factors. *Semin Orthod* 18 (4): 257–269. doi: 10.1053/j.sodo.2012.06.004.
  57. Seong C, Chen P-J, Kalajzic Z, Mehta S, Sharma A, Nanda R, et al (2022) Vitamin E enriched diet increases the rate of orthodontic tooth movement. *Am J Orthod Dentofac Orthop Off Publ Am Assoc Orthod its Const Soc Am Board Orthod* 161 (5): 687-697. e3. doi: 10.1016/j.ajodo.2020.10.033.
  58. Bolat E, Esenlik E, Öncü M, Özgöçmen M, Avunduk MC, Yüksel Ö (2020) Evaluation of the effects of vitamins C and E on experimental orthodontic tooth movement. *J Dent Res Dent Clin Dent Prospects* 14 (2): 131–137. doi: 10.34172/jodddd.2020.0027.
  59. Chen Y-W, Wang H-C, Gao L-H, Liu C, Jiang Y-X, Qu H, et al (2016) Osteoclastogenesis in Local Alveolar Bone in Early Decortication-Facilitated Orthodontic Tooth Movement. *PLoS One* 11 (4): e0153937. doi: 10.1371/journal.pone.0153937.
  60. Nakornnoi T, Leethanakul C, Samruajbenjakun B (2019) Effects of Leukocyte-Platelet-Rich Plasma on the Alveolar Bone Changes During Orthodontic Tooth Movement in Rabbits : A Micro-CT Study. *J Indian Orthod Soc* 0–7. doi: 10.1177/0301574219872608.