

Antidiabetic and pancreas-protective potential of *Parthenium Hysterophorous* (Carrot grass) in Alloxan induced diabetic rabbits

Munazza Makhdoom¹, Ayesha Maqbool¹, Hafsa Muhammad², Sheeba Makhdoom¹, Hamna Ashraf³,
Mirza Jawad ul Hasnain¹, Waseem Ahmed Khan⁴, Muhammad Irfan^{5*}

¹ Department of Molecular Biology, Virtual University of Pakistan, Pakistan

² Department of Molecular Biology and Genetics, Institute of Basic Medical Sciences, Khyber Medical University, Peshawar, Pakistan

³ Department of Obstetrics and Gynaecology, Benazir Bhutto Hospital, Rawalpindi, Pakistan

⁴ Department of Zoology, IMCB(PG), H-8, Islamabad, Pakistan

⁵ Department of Zoology, Wildlife and Fisheries, Pir Mehr Ali Shah, Arid Agriculture University, Rawalpindi, Pakistan

ARTICLE INFO

Original paper

Article history:

Received: May 08, 2022

Accepted: July 15, 2022

Published: July 31, 2022

Keywords:

Parthenium hysterophorous, alloxan, hyperglycemia, Diabetes mellitus

ABSTRACT

Parthenium hysterophorus has been used to cure cancer, fever, malaria, diarrhea, dysentery, and neurologic disorders. This study evaluates the anti-diabetic effects of methanolic extract of *P. hysterophorus* (MEPH) in alloxan-induced diabetic rabbits. Twenty-five rabbits were divided into 5 groups (N=5). Group-I served as a negative control. Groups II to V were injected with freshly prepared alloxan solution 150 mg/kg intraperitoneally to induce diabetes. Group II till V received following treatments orally: Group II: Alloxan 150 mg/kg alone; group III: Alloxan + MEPH (50 mg/kg); group IV: Alloxan + MEPH (100 mg/kg); group V: Alloxan + Glucophage (62.5 mg/kg), respectively for 10 days. The body weight of all animals was recorded on the 1st, 4th, 7th and 10th days. Short-term (1st, 3rd, 5th and 7th hour) and long-term (4th, 7th and 10th day) hypoglycemic effects were also recorded. All animals were sacrificed on the 10th day to isolate the pancreas for histopathological examination. The results showed that MPEH reduced the blood glucose levels in all the groups of alloxan-induced diabetic rabbits. The histopathological studies depicted that 100 mg/kg of MEPH most effectively repaired alloxan-induced pancreatic damage. The study showed that the MPEH is useful for developing effective phytomedicine to treat diabetes mellitus.

Doi: <http://dx.doi.org/10.14715/cmb/2022.68.7.7>

Copyright: © 2022 by the C.M.B. Association. All rights reserved. 

Introduction

The pancreas regulates glucose levels in the blood by secreting two antagonistic hormones, *i.e.*, insulin and glucagon. Alpha cells of islets of Langerhans produce glucagon to raise blood glucose whereas, β cells secrete insulin that reduces the levels of glucose in the blood (1). Insulin regulates the storage of glucose and fats in different body tissues such as the liver, brain muscles and even fat tissue. It also promotes the synthesis of protein by enhancing amino acid transport and stimulating ribosomal activity (2). The insulin insufficiency due to pancreatic damage or receptors malfunctioning may result in diabetes mellitus type I or II, respectively, characterized by hyperglycemia.

The insulin-dependent or type I diabetes has the primary cause of pancreatic β cells damage by autoimmunity, free radicals and/or genetic mutations (3). However, insulin-independent or type II diabetes involves ageing, an unhealthy lifestyle, inheritance and side effects of medication. Diabetes if left untreated leads to a series of metabolic disorders such as loss of appetite, weight loss, frequent thirst, retinopathy, nephropathy, cardiovascular disorders, strokes, neuropathy and even death (4).

The current methods of medicinal control and management of diabetes are effective but have side effects. Further, these anti-diabetic medicines may regulate glucose levels but do not heal the pancreatic damage significantly. Insulin administration is painful, expansive and required on daily basis for a lifetime. Therefore, natural products and medicinal plants have been screened for potential anti-diabetic and pancreas protective chemicals (5).

P. hysterophorus is an annual plant about 30 to 150 cm long belonging to the Asteraceae family. It is commonly called carrot grass and congress grass. It is locally found in the Gulf of Mexico, Southern North America, and Parts of Africa and the West Indies (6). However, it accidentally got transferred to the Indian Subcontinent in 1955 with the imported food grains. The plant is currently a major weed in Pakistan, Vietnam, Taiwan, India and some countries in the east and South Africa (7). It has spread a lot during the last two decades and now is widely found in fields, along the roadsides, rivers, orchards, crops, degraded pastures and on the wasteland (8).

Phytochemical and medicinal analysis of the whole plant has shown its antimicrobial, anti-anemic, antipyretic, anticancer, antioxidant, lipo-protective, antioxidant,

* Corresponding author. Email: muhammadirfan11@gmail.com

hypoglycemic, hepatoprotective and anti-cancer potential (9-11). It is also known to cure fever, malaria, diarrhea, dysentery, and neurologic disorders (12). Therefore, the present study investigated the anti-diabetic and pancreas protective activity of methanolic extract of *P. hysterophorus* in alloxan-induced diabetic male rabbits.

Materials and Methods

Plant collection

Plants were collected in March from the various parks and roadsides in Islamabad. Plants were authenticated by a plant taxonomist at Department of Botany, Pir Mehr Ali Shah, Arid Agriculture University, Rawalpindi. At least 1 kilogram of the plant was collected for the experiment.

Processing of plant materials

The whole plant of *P. hysterophorus* after the collection was cleaned off. Then the entire plant was dried under the shade and cut into small pieces as possible. Then these plant pieces were ground using an electrical grinder (WF-1804) into powdered form. Next, this powdered form of the plant was kept in a glass jar away from the sunlight (13). Methanol at the ratio of 1:3 was added to the jar containing powdered plant material. Stirring was done at regular intervals to ensure proper mixing and dipping of plant material in methanol.

Preparation of methanolic extract of *P. hysterophorus*

One kilogram of this powder was soaked into three litres of methanol. It was kept in methanol for about one week. Next filtration was carried out with the help of Whatman filter paper. After filtration extract was concentrated on a rotary evaporator. The rotary evaporator was set at 100 rounds /min and methanol evaporated at 60-degree centigrade. Then the glass vials were kept in a desiccator for about 6 to 8 hours to remove moisture from them. Thus, Semi-solid extract was kept in Glass vials in the refrigerator at 4°C for future use (13).

Selection and arrangement of experimental animal

Twenty-five (25) male rabbits having equal weight (800-1000 g) were purchased from market. Each group (n=5) was tagged with a unique number and kept in a separate ventilated cage (floor area: 50X35cm, height: 45cm) at the Endocrinology Laboratory, Department of Zoology, Pir Mehr Ali Shah, Arid Agriculture University, Rawalpindi. Rabbits were kept between 15 °C to 20 °C temperature, 65% humidity, 12 hours of light and dark cycle, and food and clean water *ad libitum*. The experimental animals were kept for a week for acclimatization before starting the experimentation.

Preparation of alloxan solution

Alloxan monohydrate powder was added to normal saline and stirred to dissolve properly. Sunlight exposure was avoided. A dose of 150 mg/kg weight of the rabbit was administered to the experimental animal to induce diabetes (13).

Safety assessment

Methanolic extracts of *P. hysterophorus* (MEPH) were tested to ensure the safety protocol to be followed during the experiment. In that respect, various doses of MEPH

were tested. Rabbits were divided into 5 groups randomly (N=5) and were given the methanolic extract of *P. hysterophorus* per orally at 50 mg/kg, 100 mg/kg and 150 mg/kg of body weight. Proper food and water were provided. Animals were kept under observation for the next 24 hours. Animals of the group treated with 150 mg/kg of MEPH showed anxiety in their behaviour along with anorexia. Hence, two therapeutic doses, i.e., 50 mg/kg and 100 mg/kg were selected for investigating the anti-diabetic potential of *P. hysterophorus* in rabbits.

Experimentation

Rabbits were divided into 5 groups (N=5). Group, one served as a negative control.

Group II to IV was injected with freshly prepared alloxan solution 150 mg/kg intra-peritoneal by the following procedure:

Experimental rabbits starved for 18 hours.

1. Alloxan was injected, and rabbits were fed after 1 hour.

2. After 12 hours of normal feeding, animals fasted for the next 12 hours.

3. Glucose levels were checked to ensure hyperglycemia (diabetes)

Once hyperglycemia was induced then the groups received the following treatments:

Group I: As a vehicle distilled water was given to this group. These animals were used as a control group.

Groups II to V were given alloxan intraperitoneally to induce diabetes.

Group II: was used as diabetic control. Alloxan was administered to induce diabetes, but no treatment was provided to observe the changes in the untreated group.

Group III: Was treated with methanol extract of *P. hysterophorus* at the dose of 50 mg/kg of body weight (low dose) for ten days orally through a feeding cannula.

Group IV: Was treated with methanolic extract of *P. hysterophorus* at the dose of 100 mg/kg of body weight (high dose) for 10 days orally through a feeding cannula (14).

Group V: Was treated with Glucophage (metformin as standard drug) 62.5 mg/kg of the bodyweight for 10 days after one dose of alloxan on day one (14).

Measurement of body weight

A rodent weighing machine was used to measure the weight of each rabbit from all the groups. Data on the body weight was collected on the first, fourth seventh and tenth day of experimentation.

Collection of blood

The blood sampling was carried out from the disinfected surface ear. Blood samples from the Saphenous vein of each rabbit were collected from all groups to measure the blood glucose level on day one (1st, 3rd, 5th and 7th hours), 4th, 7th and 10th day with a digital glucometer. The body weight of all the animals was also measured and recorded.

Dissection of animals

Animals of all the groups were anaesthetized with chloroform and dissected. The pancreas was traced and isolated and placed in a petri dish. The pancreas was washed with distilled water to remove the blood and other debris. Moreover, the isolated pancreas was preserved in

10% formalin (15). Pancreatic tissues were used for histopathology. The Samples were photographed for detailed histopathological studies with a light microscope (NIKON Eclipse 80i).

Histopathological examination

Pancreases were isolated from the dissected rabbit and were transferred to 10% formalin to preserve it. The preserved pancreas was utilized for histopathology. It was treated with a 0.85% saline solution to remove any blood or debris attached. Then fixation of the tissue to preserve cells and tissue and prevent it from autolysis was done by keeping it in Bovine's fluid for 16 to 24 hours. The paraffin wax method was used for the microtome. The tissue was immersed in gradual series of alcohol. Sectioning was done by fixing the wax block in the rotary microtome (LEICA RM2125RT) and sections were cut in the form of ribbons (7-10 μ m thick). A water bath at 42-46°C was used to eradicate any wrinkles in the sections. Moreover, an adhesive solution of Mayer's albumin was smeared on a glass slide.

De-waxing was done by using downgrades of alcohol such as 100%, 90%, 70%, and tap water. The staining of the section was done next. Hematoxylin and eosin stains stained the nucleus and cytoplasm of the tissue respectively. Clove oil made it transparent later, excess oil and alcohol were removed by using xylene. Finally, the section was mounted using Canada balsam or D.P.X (diphenyl xylene). The Samples were photographed for detailed histopathological studies with a light microscope (NIKON eclipse 80i) (16).

Statistical analysis

All the results obtained from the data of bodyweight and long and short-term blood sugar levels were expressed as mean \pm standard error (S.E) and compared by ANOVA followed by Tukey's test. The significant difference was

considered at $P < 0.05$ between the groups.

Results and Discussion

Body weight

Table 1 shows the mean body weight of control group differed non-significantly ($p > 0.05$) from all treatment groups. Similarly, non-significant ($p > 0.05$) difference in mean body weight was found between all treatment groups.

Blood glucose level

Comparison of the blood glucose level of treatments at 0, 1st, 3rd, 5th and 7th hours showed that the control group was significantly ($p < 0.05$) lower than all the other groups (Table 2).

All the treated groups had statistically similar ($p > 0.05$) glucose levels up to 3 hours of treatment. However, at the 5th and 7th hour of treatment, Alloxan treated group had significantly ($p > 0.05$) higher glucose levels than all other groups. The Alloxan+MEPH (50mg/kg) group significantly ($p < 0.05$) reduced glucose levels at the 5th and 7th hours than the control and Alloxan treated group. However, the Alloxan+MEPH (100 mg/kg) group was the most effective to reduce glucose levels compared to Alloxan+Glucophage (62.5 mg/kg) at the 5th and 7th hours of treatment (Table 2).

Blood glucose level over 10 days period

Alloxan+Glucophage at day 4 had lowest ($p < 0.05$) blood glucose level. However, later, day 7 and day 10 the Alloxan+MEPH (100 mg/kg) decreased blood glucose comparative to the positive control, i.e., Alloxan+Glucophage treatment (Table 3).

Histopathological investigations

The pancreas isolated from group-I served as a normal control the group exhibited a normal cellular population

Table 1. Effect of treatments of methanolic extract of *P. hysterophorus* on body weight (g) of rabbits.

Treatment/Days	Day 1 Mean \pm S.E	Day 4 Mean \pm S.E	Day 7 Mean \pm S.E	Day 10 Mean \pm S.E
Control	970.00 \pm 32.98	973.20 \pm 32.58	977.60 \pm 31.42	983.80 \pm 29.70
Alloxan treated	952.60 \pm 46.25	936.80 \pm 44.99	929.00 \pm 47.50	941.40 \pm 37.25
Alloxan+MEPH (50 mg/kg)	935.00 \pm 43.06	939.20 \pm 43.35	942.00 \pm 43.01	945.00 \pm 43.54
Alloxan+ MEPH (100 mg/kg)	947.40 \pm 44.85	953.60 \pm 43.46	959.00 \pm 43.89	964.80 \pm 43.78
Alloxan + Glucophage (62.5 mg/kg)	954.40 \pm 40.45	951.20 \pm 40.64	946.60 \pm 42.10	945.00 \pm 38.69

Two-way analysis of variance (ANOVA); All values are non-significantly different at $p > 0.05$; MEPH: methanolic extract of *P. hysterophorus*

Table2. Effect of treatment of methanolic extract of *P. hysterophorus* on blood glucose level (mg/dl)

Treatment/Days	0 hour Mean \pm SE	1 st hour Mean \pm SE	3 rd hour Mean \pm S.E	5 th hour Mean \pm S.E	7 th hour Mean \pm S.E
Control	86.0 \pm 6.52 ^a	96.6 \pm 4.83 ^a	100.4 \pm 3.85 ^a	108.2 \pm 3.08 ^a	108.2 \pm 2.49 ^a
Alloxan treated	201.6 \pm 11.67 ^b	205.8 \pm 11.05 ^b	210.2 \pm 11.17 ^c	214.6 \pm 11.67 ^d	218.6 \pm 10.74 ^d
Alloxan+ MEPH (50 mg/kg)	189.4 \pm 12.28 ^b	186.2 \pm 10.84 ^b	181.2 \pm 6.46 ^c	172.6 \pm 7.64 ^c	170.0 \pm 6.75 ^c
Alloxan+ MEPH (100 mg/kg)	198.6 \pm 5.22 ^b	178.8 \pm 4.66 ^b	164.00 \pm 5.00 ^b	147.60 \pm 7.57 ^b	135.60 \pm 5.86 ^b
Alloxan + Glucophage (62.5 mg/kg)	189.50 \pm 12.56 ^b	169.20 \pm 10.55 ^b	159.40 \pm 13.80 ^b	145.20 \pm 17.68 ^b	131.17 \pm 20.31 ^b

Analysis of Variance followed by Turkey's test; Values with different alphabets are significantly different at $p < 0.05$ within a column; MEPH: methanolic extract of *P. hysterophorus*

Table 3. Effect of Day-wise treatments of methanolic extract of *P. hysterophorus* on blood glucose level mg/dl

Treatment/Days	Day 4 Mean±S.E	Day 7 Mean±S.E	Day 10 Mean±S.E
Alloxan+ MEPH (50 mg/kg)	99.20±7.98 ^b	99.40±3.05 ^b	95.00±3.81 ^b
Alloxan+ MEPH (100 mg/kg)	94.00±5.83 ^b	87.40±6.84 ^a	82.60±4.39 ^a
Alloxan + Glucophage (62.5 mg/kg)	82.20±2.59 ^a	78.40±2.41 ^a	78.40±4.72 ^a

Analysis of Variance followed by Turkey's test; Values with different alphabets are significantly different at $p < 0.05$ within a column; MEPH: methanolic extract of *P. hysterophorus*.

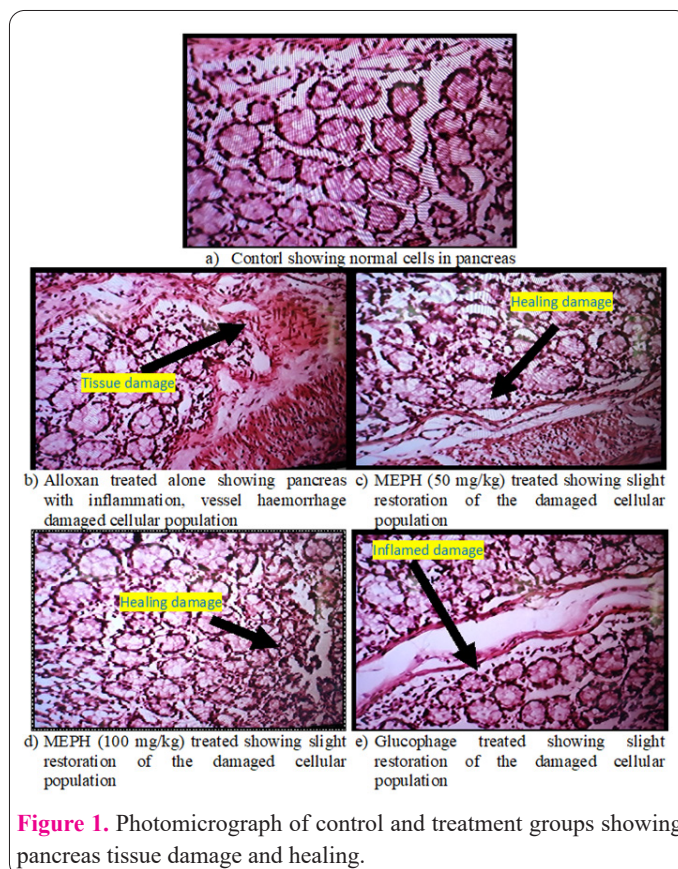
in histological sections (Figure 1. a). Hence, this group showed normal functioning of pancreatic tissue. Alloxan treated group alone showed deteriorated cellular morphology with necrosis, blood vessels dilated and ruptured showing haemorrhaged tissue (Figure 1. b).

Pancreatic tissue isolated from group III which was treated with a low dose of MEPH (50 mg/kg) after inducing diabetes with alloxan showed distorted morphology. Slight restoration of the tissue can be observed. However, no significant repair of the tissue was seen as low-dose treatment did not show any significant tissue repair (Figure 1. c). Pancreatic tissue from group IV which was treated with a high dose of MEPH (100 mg/kg) showed significant regeneration of the cellular population which resembles the cellular population of the control group (Figure 1. d). Pancreatic tissue isolated from group V which was treated with standard drug at the dose of 62.5 mg/kg did not exhibit any significant improvement in the degenerated tissue. Hence allelopathic drug reduces the blood sugar level to normal but is unable to repair the damaged tissue (Figure 1. e).

Diabetes mellitus is a prevalent chronic metabolic disorder. It is characterized by low or absence of insulin production which leads to hyperglycemia. Diabetes mellitus is affecting most of the world's population at a great speed. Synthetic medicines possess several limitations so anti-diabetic agents from herbal drugs need to be used to cure hyperglycemia. The present study aimed to investigate the anti-diabetic potential of *P. hysterophorus* in alloxan-induced diabetic rabbits. The data of the present study clearly showed that the oral administration of methanolic extract of the plant at both doses (50 and 100 mg/kg body weight) produced a significant hypoglycemic effect in the alloxan-induced diabetic rabbits.

P. hysterophorus possess flavonoids, glycosides, alkaloids, tannins, and phenolics which makes the plant to cause hypoglycemia. (17-20). A drug named Alloxan monohydrate specifically damages pancreatic beta cells and induces diabetes in the experimental model. Methanolic extract of *P. hysterophorus* when administered regularly as treatment was found to have a significant effect in reducing blood glucose levels.

In the present study alloxan-induced diabetes was developed by the administration of the dose of 150 mg/kg weight of the rabbit given intraperitoneally (13). Alloxan-induced diabetic animals were treated with low and high doses of the plant extract, while one group of diabetic rabbits was treated with the standard drug Glucophage (62.5 mg/kg) for 10 days. Oral administration of MEPH at the low dose, i.e., 50 mg/kg of body weight and high dose, i.e., 100 mg/kg exhibited a significant reduction in blood glucose level in both treatment groups as compared to the untreated diabetic group. However, the standard drug



(Glucophage) treated group also exhibited a significant decrease in hyperglycemia.

The MEPH dose of 50 mg/kg of body weight decreased the blood glucose level but couldn't bring glucose levels to their normal range during 10 days of study. However, the MEPH dose of 100 mg/kg of body weight decreased blood glucose level to a significant level for 10 days. Glucophage treated group also showed reduced blood glucose levels for 10 days. Results reveal that treatments with the MEPH did not exhibit any significant weight gain in the rabbits. However, the increased weight may be due to the intake of food and growth during the ten days of the experimental period.

Statistical analysis reveals that blood glucose levels of rabbits, having alloxan-induced diabetes were significantly reduced when administered with two different MEPH doses (50 mg/kg & 100 mg/kg) of *P. hysterophorus*. However, a high dose showed more hypoglycemic effects. Moreover, MEPH acted as a healing factor as well as compared to the standard drug, i.e., Glucophage.

The histological characteristics of the pancreatic tissue of all the experimental groups are shown. The tissue section of the control group tissue showed the normal cellular population with acini. Alloxan treated alone showed

inflammation in the tissue along with necrosis and vessel haemorrhage. Tissue degeneration was also observed. Apoptosis occurring in the cellular population was investigated. Histology of the treated groups with MEPH showed slight regeneration of the damaged tissue. The cellular population of the 50 mg/kg MEPH treated group exhibited slight repair of destroyed tissue compared to the alloxan treated group. The 100 mg/kg MEPH treated group showed more restoration of damaged tissue as compared to a low dose (50 mg/kg). Glucophage (standard drug) used to treat diabetes reduced the blood sugar level but did not repair the damaged tissue.

The decrease in blood glucose may be due to increase in the secretion of insulin from pancreas, decrease in conversion of dietary carbohydrates into glucose, gluconeogenesis, glycogenolysis, and healing of pancreatic tissue (21). The alloxan destroy tissues by oxidative stress and healing of tissue is the most probable mechanism of MEPH. However, the phenols and flavonoids present in MEPH also have potential to inhibit α -glucosidase resulting in decrease glucose synthesis from dietary carbohydrates and its absorption into the blood (22). However, this mechanism should have decreased body weight of MEPH treated groups overtime as compared to the control group contrary to our results of body weight. The phenolic compounds such as chlorogenic acid found in MEPH has hypoglycemic potential by inhibiting glucose-6-phosphate translocase that otherwise transports glucose-6-phosphate into the lumen of the endoplasmic reticulum to hydrolyze it into glucose. Similarly, ellagic acid and alkaloids also inhibit the glucose-1-phosphate, a key enzyme of glycogenolysis (23).

The apoptosis and inflammation could be attributed to the antioxidants and anti-inflammatory chemicals present in the plant. *P. hysterophorus* exhibited high concentrations of polyphenol and flavonoids responsible for tissue healing (24). Hence, this study suggests that MEPH has potential to cure both type-I and type-II diabetes and MEPH at the dose of 100 mg/kg not only reduces the blood sugar to a normal level, but it also repairs the damaged pancreatic tissue as well.

In the present study, only methanolic extract was used. There is a need to investigate the potential of plant extracts prepared in aqueous and other organic solvent mediums. Similarly, in the present study whole plant extract was used. However, the extracts of specific plant parts may also be screened. *In vitro* screening of antioxidation, anti-inflammation and carbohydrate metabolism related enzyme inhibition should also be carried out to reveal the most probable mechanism of hypoglycemia and tissue repairing by MEPH.

Methanolic extract of *P. hysterophorus* at a dose of 50 mg/kg and 100 mg/kg contain anti-diabetic activity. Oral administration of methanolic extract of *P. hysterophorus* at the dose of 50 mg/kg and 100 mg/kg did not bring any significant weight gain. Oral administration of methanolic extract of *P. hysterophorus* at the high dose of 100 mg/kg is more effective as compared to the low dose of 50 mg/kg. Methanolic extract of *P. hysterophorus* at the dose of 100 mg/kg restored pancreatic damaged tissue hence MEPH possesses tissue healing capability as well.

Interest conflict

No conflict of interest to declare.

Consent for publications

The author read and proved the final manuscript for publication.

Availability of data and material

All data generated during this study are included in this published article

Authors' Contribution

All authors had an equal role in study design, work, statistical analysis and manuscript writing.

Funding

Nil

Ethics approval and consent to participate

The study protocol was approved by the Ethics Committee of the Virtual University of Pakistan, Ref. No. ECS.2020/18.

References

- Moede T, Leibiger IB, Berggren PO. Alpha cell regulation of beta cell function. *Diabetologia*. 2020;63(10):2064-2075. doi: 10.1007/s00125-020-05196-3.
- Akhtar MS., Khan S, Bashir S, Salman M. Effect of *Lodoicea sechellarum* Labill (Sea Coconut) fruit on blood glucose and lipid profile in type 2 diabetic and normal human volunteers. *Diabetol Croat* 2009; 38(4), 87-93.
- DiMeglio LA, Evans-Molina C, Oram RA. Type 1 diabetes. *Lancet*. 2018; 391(10138): 2449-2462. doi:10.1016/S0140-6736(18)31320-5.
- Ding Z, Lu Y, Lu Z. et al. Hypoglycaemic effect of comatin, an anti-diabetic substance separated from *Coprinus comatus* broth, on alloxan-induced-diabetic rats. *Food Chem* 2010; 121, 39–43.
- Przeor M. Some Common Medicinal Plants with Antidiabetic Activity, Known and Available in Europe (A Mini-Review). *Pharmaceuticals (Basel)*. 2022;15(1):65. doi: 10.3390/ph15010065.
- Manpreet K, Neeraj KA, Vikas K, Romika D. Effects and Management of *Parthenium hysterophorus*: A Weed of Global Significance. *Int Sch Res Notices*, 2014; <https://doi.org/10.1155/2014/368647>
- Dhileepan K, Wilmot Senaratne KAD. How widespread is *P. hysterophorus* and its biological control agent *Zygomorpha bicolorata* in South Asia? *Weed Res* 2009; 49(6), 557-562.
- Evans HC. *P. hysterophorus* review of its weed status and the possibilities for biological control. *Biocontrol News Info* 1997; 18, 89N-98N.
- Pandey J., Maurya R., Raykhera R., Srivastava M.N., Yadav P.P., Tamrakar A.K. *Murraya koenigii* (L.) Spreng. ameliorates insulin resistance in dexamethasone-treated mice by enhancing peripheral insulin sensitivity. *J Sci Food Agric* 2014; 94:2282-2288.
- Patel DK, Kumar R, Prasad SK, Hemalatha S. *Pedaliium murex* Linn (Pedaliaceae) fruits: a comparative antioxidant activity of its different fractions. *Asian Pac J Trop Biomed* 2011;1(5):395-400. doi: 10.1016/S2221-1691(11)60087-7.
- Saleem M, Naureen H, Khan A. et al. Protective effect of *Parthenium hysterophorus* against carbon tetrachloride- and paracetamol-induced hepatotoxicity in rabbits. *Trop J Pharm Res* 2018; 17(3), 467-473.
- Venkataiah B, Ramesh C, Ravindranath N, Das B. Charminarone, a seco-pseudoguaianolide from *Parthenium hysterophorus*. *Phytochem* 2003;63(4), 383-386
- Wadood A, Wadood N, Shah SA. Effects of *Acacia arabica* and *Caralluma edulis* on blood glucose levels of normal and alloxan diabetic rabbits. *J Pak Med Assoc* 1989; 39(8): 208-212.

14. Sharma SB, Nasir A, Prabhu KM, Murthy PS, Dev G. Hypoglycaemic and hypolipidemic effect of ethanolic extract of seeds of *Eugenia jambolana* in alloxan-induced diabetic rabbits. *J Ethnopharmacol* 2003; 85(2-3): 201-6. doi: 10.1016/s0378-8741(02)00366-5.
15. Sakhaee K, Adams-Huet B, Moe OW, Pak CY. Pathophysiologic basis for normouricosuric uric acid nephrolithiasis. *Kidney Int* 2002; 62(3):971-9. doi: 10.1046/j.1523-1755.2002.00508.x.
16. Spitalnik PF, Witkin JW. 2016. Histology laboratory manual. College of Physicians and Surgeons, 2016.
17. Cherian S, Kumar RV, Augusti KT, Kidwai JR. Anti-diabetic effect of a glycoside of pelargonidin isolated from the bark of *Ficus bengalensis* Linn. *Indian J Biochem Biophys* 1992; 29(4):380-2.
18. Hakim ZS, Pande JP, Marval L. Potential anti-diabetic agents from plant sources; Pharmacological Aspects. *Indian J Nat Prod* 1995; 11(1), 3.
19. Manickam M, Ramanathan M, Jahromi MA, Chansouria JP, Ray AB. Antihyperglycemic activity of phenolics from *Pterocarpus marsupium*. *J Nat Prod*. 1997; 60(6):609-10. doi: 10.1021/np9607013.
20. Akowuah GA, Sadikun A, Mariam A. Flavonoid identification and hypoglycaemic studies of the butanol fraction from *Gynurapro-cumbens*. *Pharm. Biol.* 2002; 40(6), 405-410.
21. Ghorbani A. Mechanisms of antidiabetic effects of flavonoid rutin. *Biomed. Pharmacother.* 2017;96:305-312. doi: 10.1016/j.biopha.2017.10.001.
22. Patel VS, Chitra V, Prasanna PL, Krishnaraju V. Hypoglycemic effect of aqueous extract of *Parthenium hysterophorus* L. in normal and alloxan induced diabetic rats. *Indian J. Pharmacol.* 2008;40(4):183-5. doi: 10.4103/0253-7613.43167.
23. Iqbal J, Khan AA, Aziz T, Ali W, Ahmad S, Rahman SU, Iqbal Z, Dabool AS, Alruways MW, Almalki AA, Alamri AS, Alhomrani M. Phytochemical Investigation, Antioxidant Properties and In Vivo Evaluation of the Toxic Effects of *Parthenium hysterophorus*. *Molecules*. 2022;27(13):4189. doi: 10.3390/molecules27134189.
24. Zhang W, Chen L, Xiong Y, Panayi AC, Abududilibaier A, Hu Y, Yu C, Zhou W, Sun Y, Liu M, Xue H, Hu L, Yan C, Xie X, Lin Z, Cao F, Mi B, Liu G. Antioxidant Therapy and Antioxidant-Related Bionanomaterials in Diabetic Wound Healing. *Front. Bioeng. Biotechnol.* 2021;9:707479. doi: 10.3389/fbioe.2021.707479.