

Nephrocurative effect of *Parthenium hysterophorus* (Carrot Grass) in Paracetamol induced nephrotoxicity in rabbits

Sheeba Makhdoom¹, Ayesha Maqbool¹, Hafsa Muhammad², Munazza Makhdoom¹, Hamna Ashraf³, Waseem Ahmed Khan⁴, Muhammad Irfan^{5*}

¹ Department of Molecular Biology, Virtual University of Pakistan, Pakistan

² Department of Molecular Biology and Genetics, Institute of Basic Medical Sciences, Khyber Medical University, Peshawar, Pakistan

³ Department of Obstetrics and Gynaecology, Benazir Bhutto Hospital, Rawalpindi, Pakistan

⁴ Department of Zoology, IMCB(PG), H-8, Islamabad, Pakistan

⁵ Department of Zoology, Wildlife and Fisheries, Pir Mehr Ali Shah, Arid Agriculture University, Rawalpindi, Pakistan

ARTICLE INFO

Original paper

Article history:

Received: April 130, 2022

Accepted: June 16, 2022

Published: July 31, 2022

Keywords:

Parthenium hysterophorus, nephrotoxicity, nephroprotection, paracetamol.

ABSTRACT

Parthenium hysterophorus is conventionally used to treat urinary tract infections, joint pain, and hyperglycaemia. This study evaluates the reno-curative effects of methanolic extract of *P. hysterophorus* (MEPH) in paracetamol-induced nephrotoxic rabbits. Thirty male rabbits were divided into V groups: Group I served as the negative control. Group-II to V were treated with 2 g/kg of paracetamol to induce nephrotoxicity. Group II served as paracetamol (PCM) intoxicated control. Group III till V were fed orally with the following treatments: III paracetamol (PCM) 40 mg/kg MEPH; IV PCM+80 mg/kg MEPH; V PCM+Cystone (5 ml/kg), respectively, for 14 days. The body weight of all animals was recorded on days 1, 7 and 14. All the animals were dissected on the 14th day and blood, urine and kidneys were collected. The results showed that *P. hysterophorus* had no effect on body weight but lowered urea and creatinine levels and brought urine parameters back to the normal range in experimental groups of PCM-induced nephrotoxic rabbits. The 80 mg/kg dose of MEPH reduced urea and creatinine levels and normalized urine parameters more effectively compared to low doses of MEPH and the standard drug, i.e., Cystone. Kidney histopathological studies exhibited that 80 mg/kg of MEPH repaired paracetamol-induced renal damage, whereas Cystone only provided reno protection as no repair in damaged tissue was investigated in histopathology of Cystone treated animals. The results suggested that *P. hysterophorus* exhibited significant reno-curative activity on paracetamol-induced nephrotoxic rabbits.

Doi: <http://dx.doi.org/10.14715/cmb/2022.68.7.6>

Copyright: © 2022 by the C.M.B. Association. All rights reserved.

Introduction

The kidneys are the passageway for the excretion of several drugs along with their metabolites. Due to this fact, kidneys impinge to various concentrations of several toxic materials. As a result, the kidney experiences direct damage, which most of the time adversely affects renal tubular cells and papillary tissue, known as nephrotoxicity. Nephrotoxins include heavy metals, antineoplastic agents, antimicrobial, aminoglycosides and drugs (1,2). Nephrotoxicity leads to kidney failure, in which the kidney fails to remove creatinine, blood urea and electrolytes, and they accumulate in the blood.

Paracetamol is related to group para-aminophenol, a class of non-steroidal anti-inflammatory drugs utilized for curing pain and fever with a prescribed dose of 1-3 g, thrice a day (2). The prescribed dose of the drug is safe, but an overdose can damage the liver and kidneys. Its presence in multiple drugs and over-the-counter availability increases the chances of paracetamol overdose. Therefore, kidney dysfunction due to paracetamol overdosing is documented

in humans as well as in animal models (3,4). The liver and kidney tissue apoptosis and necrosis are reported with paracetamol intake of more than 150 mg/kg of the body weight (5).

Abnormal kidney functioning is known to arise in 1 to 2% of individuals with paracetamol toxicity (6). The Paracetamol When given orally, 60-63% of the paracetamol metabolizes through glucuronidation while 30-34% through sulphation principally within the liver. However, the water-soluble metabolites are excreted through the kidneys. A highly unstable and reactive intermediate substance N-Acetyl-p-benzoquinone (NAPQI) is produced via a microsomal P-450 enzyme complex within the liver when approximately 55% of the paracetamol gets oxidized. Moreover, NAPQI is metabolized in less toxic components through glutathione (GSH) within the cell when a prescribed dose of paracetamol is consumed (7). However, NAPQI is chiefly considered an accountable metabolite of paracetamol toxicity (8). In the case of paracetamol overdose, GSH reserves get exhausted, which causes an accumulation of NAPQI causing necrosis (9).

* Corresponding author. Email: muhammadirfan11@gmail.com

GSH reserves are responsible for antioxidant activity in cells being scavengers of free radicals. The free radicals formed in an organism when exposed to drug toxicity are principally important moderators of paracetamol-induced nephrotoxicity (10, 11). Oxidative damage is documented to be principally involved in paracetamol-induced renal tissue by enhancing lipid peroxidation due to no or less available GSH (12-14).

Worldwide records exhibit that approximately 80% of the 3-4 billion global population relies upon conventional medicines extracted from various plants. Medicinal plants are extensively utilized for the cure and treatment of a variety of diseases in developing countries (15) due to their less cost, easy access, few side effects as compared to allelopathic drugs and effectiveness. They are thus used in substitution for conventional drugs (16).

Parthenium hysterophorus L. is commonly called congress weed, carrot weed, Gajar ghaas (17), feverfew (18) and bitter weed. It belongs to the family Compositae, which is an annual herb capable of generating numerous small white capitula each releasing 5 seeds when mature. It is an inhabitant of America; however, it extended to Australia, India, and Pakistan and spread as a destructive weed in cultivated areas and is known to contain a variety of chemicals, e.g., proteins, carbohydrates, glycosides, alkaloids, saponins, tannins, volatile oils, terpenoids, steroids, amino acids, glycoproteins, organic acids, phenolic compounds, amino acids, metallic compounds, terpenoids and many others (19-22).

P. hysterophorus is documented to be used against skin allergies, ulcers, fever, neuralgia, anemia, eczema, skin rashes, herpes, joint pain, urinary tract infections, dysentery, malaria, heart troubles, muscular rheumatism, as vermifuge and female reproductive diseases (23,24). Studies conducted on the whole plant showed its effectiveness as an antipyretic antimicrobial, anti-anemic, antioxidant, lipo-protective, hypoglycemic and hepatoprotective (25, 26). Although studies have investigated certain plants to have the potential to cure the nephropathies caused by toxic substances (27), there is no such study about *P. hysterophorus*. The present study investigated the effect of methanolic extract of *P. hysterophorus*, for its nephrocurative activity, against kidney damage induced by Paracetamol in male rabbits.

Materials and Methods

Collection of plant material

The whole plant of *P. hysterophorus* (approximately 1 kg) was collected in March from various parks and roadsides of Islamabad. Plants were authenticated by a taxonomist at the Department of Botany, Pir Mehr Ali Shah, Arid Agriculture University Rawalpindi.

Processing of plant material

The branches of the whole plant were cut, pressed and air-dried at room temperature under shade for 20 days. The dried plant branches were further cut into small pieces and were ground in an electric grinder (WF-1804). The powdered plant was stored in closed and dry plastic bags avoiding contact with sunlight (28).

Preparation of plant extract

Methanolic extracts of *P. hysterophorus* (MEPH) were

prepared by soaking plant-powdered into methanol (w/v ratio of 1:3) for seven days and were stirred regularly to ensure the contact of all particles of plant powder with solvent. The extract was filtered by using Whatman's filter paper. After filtration, the extract was concentrated on the rotary evaporator. The glass vials were placed in a desiccator for 6-8 hours to remove moisture from the sample. The semi-solid sticky plant extract was placed in Glass vials in a refrigerator at 4°C for future experimentation (28).

Preparation of Paracetamol solution

Paracetamol (PCM) tablets (500 mg, GlaxoSmithKline Company, UK) (n=30) were ground thoroughly in a pestle and mortar. Ground powder of PCM was mixed with 60 ml of distilled water to attain a solution of concentration (250 mg/ml). The solution was then mechanically shaken adequately and was placed in a closed container. For each animal dose of 2 g/kg (8 ml/kg) was given orally to the rabbits to induce nephrotoxicity.

Experimental animals

In this experiment, 30 male rabbits weighing 80-1000 g and aged between 3 and 6 months were purchased from a local market. All Rabbits were caged in a metallic cage for one week at standard room temperature (25-30°C) to acclimatize to the laboratory environment. During this time, they were fed cabbage, grasses, and water ad libitum. The rabbits were randomly assigned to control and different treatment groups. Each group comprised 6 animals (i.e. N=6).

Feeding schedule

A feeding schedule of normal routine feed, PCM, and MEPH in male rabbits during a study period of 0 to 14 days was designed by keeping group I as the control group (vehicle-treated), while groups II, III, IV, and V have induced nephrotoxicity with PCM 2 g/kg in 5ml distilled water.

Safety assessment

MEPH was tested for its safety protocol at various doses. Rabbits were segregated into 3 groups randomly (N=6). They were administered orally MEPH at 40 mg/kg, 80 mg/kg and 120 mg/kg of bodyweight provided with adequate food and water and were kept under observation for 1 day, i.e., 24 hours. Animals of the group treated with 120 mg/kg of MEPH exhibited anorexia and inactivity. Therefore, two lower therapeutic doses, i.e., 40 mg/kg and 80 mg/kg were selected for investigating reno-curative activity in rabbits.

Experimental design

Rabbits were divided into five groups (N=6) to study the effect of methanolic extract of *P. hysterophorus* against PCM-induced nephrotoxicity in rabbits.

Group I: Was given distilled water as a vehicle via feeding cannula for 14 days. This served as a vehicle-treated control group.

Groups II to IV were given one dose of PCM 2 g/kg of body weight on day one orally to induce renal intoxication.

Group II: Received one dose of PCM on day one. This group was examined for the prevalence of renal injury and served as the PCM intoxicated control group.

Group III: Treated with MEPH (40 mg/kg of body

weight) for 14 days orally through feeding cannula after 24 hours of PCM intoxication. This group was examined for the renocurative activity of *P. hysterophorus* at a low dose.

Group IV: Treated with MEPH (80 mg/kg of body weight) for 14 days orally through feeding cannula after 24 hours of PCM Intoxication. This Group was examined for the nephroncurative activity of *P. hysterophorus* at a higher dose.

Group V: Treated with Cystone (positive control) 5 ml/kg of body weight for 14 days followed by one dose of PCM on day one. This group served as a reference drug-treated group (29).

Dissection of animals

All animals were anaesthetized with mild chloroform and dissected urinary bladder was traced and urine was collected via the urinary bladder puncture with a 3-cc syringe. After collection, samples were transferred to urine bottles. Moreover, blood was collected from it via cardiac puncture (30) using a 3cc syringe. The collected blood was immediately transferred to yellow-topped bottles. One animal from each group was dissected and their blood was collected on day 2 to confirm renal intoxication. Rests of the animals were dissected on day 14 to investigate the changes in blood urea, creatinine and urine parameters in control (vehicle-treated), PCM intoxicated control and MEPH treated rabbits. The third and last step of dissection was the isolation of kidneys from the abdominal cavity. Kidneys were traced and isolated from dissected rabbits transferred to a Petri dish and washed in distilled water many times to eliminate blood and other contaminations. Isolated kidneys were then transferred to 10% formalin (a preservative). Kidney tissues preserved were used for histopathology (31).

Parameters analysed

Bodyweight analysis

The weight (in grams) of all groups of rabbits, i.e., control, PCM intoxicated and treated with different doses of MEPH was recorded on the 1st, 7th and 14th day of treatments and percentage changes in their body weight were calculated.

Urine analysis

The Urine samples of all groups of rabbits were investigated for biochemical parameters, i.e., urine pH, albumin, Leukocytes, Erythrocytes, urine colour, and turbidity using an auto-analyser (Cobas u 411).

Blood urea

The concentration of blood urea of all groups of rabbits, i.e., control, PCM intoxicated and treated with different doses of MEPH at day 14 was determined from blood samples by using an auto-analyser (Cobas c 311) (32).

Blood creatinine

The concentration of serum creatinine of all groups of rabbits, i.e., control, PCM intoxicated and treated with different doses of MEPH on day 14 was determined from blood samples by using an autoanalyser (Cobas c 311) (32).

Histopathological examination

Kidneys were dissected out from the rabbits, transferred to 10% formalin (a preservative) and were placed serially in various grades of alcohol. Samples were embedded in paraffin wax and were subjected to sectioning in a rotary microtome (LEICA RM 2125RT). Sections of thickness 7-10 um were cut in the form of a ribbon. Dewaxing was carried out by placing the sections in descending series of alcohol. Sections were finally stained with haematoxylin and eosin and were subjected to dehydration by placing them in ascending series of alcohol. Samples were placed in clove oil to attain transparency finally the sections were mounted on the glass slide with the Canada balsam. Samples were photographed for detailed histopathological studies with the light microscope (NIKON Eclipse 80i) (33).

Statistical analysis

Data obtained after the experiment was expressed as mean±S.E. Statistical significance of data was investigated by using statistical tools, i.e., Analysis of Variance (ANOVA) and comparison was done with the help of Tukey's test. Significance differences were established at $p < 0.05$.

Results and Discussion

Bodyweight

Table 1 shows that there was a non-significant ($p > 0.05$) increase in mean body weights of control and all treated groups for 14 days.

Blood urea, creatinine and pH levels

Table 2 shows that mean blood urea and creatinine levels were highest ($p < 0.05$) in the PCM intoxicated group. The MEPH at 80 mg/kg dose was the most effective ($p < 0.05$) in lowering urea and creatinine levels in the blood of rabbits intoxicated with PCM. The PCM-treated

Table 1. Effect of treatments of methanolic extract of *Parthenium hysterophorus* on body weight (g) of rabbits.

Treatment/Days	Day 1 Mean±S.E.	Day 7 Mean±S.E.	Day 14 Mean±S.E.
Control	971.20±19.11	973.60±19.50	977.80±19.42
PCM intoxicated	979.20 ±14.46	968.20±13.54	959.40±12.14
PCM+MEPH (40 mg/kg)	963.40±41.07	970.60±41.49	981.80±41.72
PCM+MEPH (80 mg/kg)	962.20±39.03	967.20±39.72	990.40±39.60
PCM+ Cystone (5 ml/kg)	956.0±46.79	961.00±46.12	965.40±46.55

Analysis of Variance; All the values are non-significantly different ($p > 0.05$).

Table 2. Effect of treatments of methanolic extract of *Parthenium hysterophorus* on blood urea, creatinine and urine pH.

Treatment/Days	Urea	Creatinine	pH
	Mean±S.E (mg/dl)	Mean±S.E (mg/dl)	Mean±S.E (mol/L)
Control	21.00±1.58 ^a	0.62±0.05 ^a	8.20±0.37 ^{bc}
PCM intoxicated	60.00±3.51 ^c	3.46±0.21 ^c	5.00±0.32 ^a
PCM+MEPH (40 mg/kg)	36.60±1.66 ^b	2.76±0.09 ^c	7.00±0.45 ^b
PCM+ MEPH (80 mg/kg)	19.40±2.06 ^a	1.28±0.31 ^{ab}	8.60±0.24 ^c
PCM+ Cystone (5 ml/kg)	26.40±1.75 ^a	1.58±0.26 ^b	8.20±0.31 ^{bc}

Analysis of Variance followed by Tukey's test; Values within the same column with different alphabets are significantly different at $p < 0.05$

Table 3: Effect of treatments of methanolic extract of *Parthenium hysterophorus* on various parameters of urine.

Treatment/Days	Leukocytes present Freq. (%)	Erythrocytes present Freq. (%)	Proteins present Freq. (%)	Colour (Other than pale yellow) Freq. (%)	Clarity (Turbid) Freq. (%)
Control	0%	0%	0%	0%	0%
PCM intoxicated	40%	80%	80%	100%	100%
PCM+MEPH (40 mg/kg)	40%	0%	40%	20%	60%
PCM+MEPH (80 mg/kg)	0%	0%	0%	0%	0%
PCM+ Cystone (5 ml/kg)	20%	20%	20%	0%	0%
Chi-value	5.00	15.00	11.11	20.61	19.49
p-value	0.29	0.05	0.03	0.00	0.00

Chi-square test; Significant difference $p < 0.05$

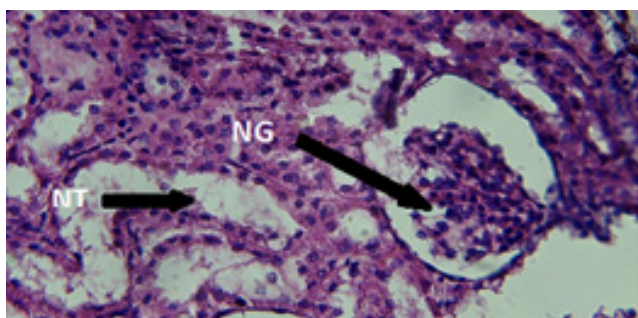


Figure 1. The kidney tissue of the control group of rabbits showed normal glomeruli (NG) and tubules.

rabbits had the lowest pH that was normalized by MEPH at 80mg/kg dose and Cystone.

Urine parameters

The percentages of leukocyte, erythrocyte, protein, colour changes and turbidity were highest in the PCM intoxicated group. However, only PCM+MEPH (80 mg/kg) group had attained values comparative to the control (Table 3).

Histopathological investigations

Photomicrographs (Figure 1) of kidneys isolated from the normal control group I exhibited normal glomeruli and tubules in histological sections, which resulted in the normal functioning of kidneys of the vehicle-treated control group.

Photomicrographs of kidneys isolated from the PCM intoxicated group (II) exhibited devastating changes in renal morphology. In some sections, kidney tissue exhibited destroyed glomerulus along with Atrophic, edematous dilated and destroyed tubules. Numerous haemorrhages were seen in the tubules (Figures 2 and 3).

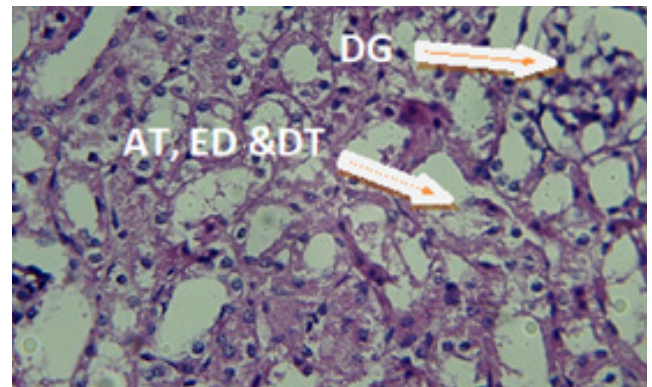


Figure 2. Paracetamol intoxicated group showing destroyed glomerulus (DG) along with atrophic (AT), edematous (ED) and destroyed tubules (DT).

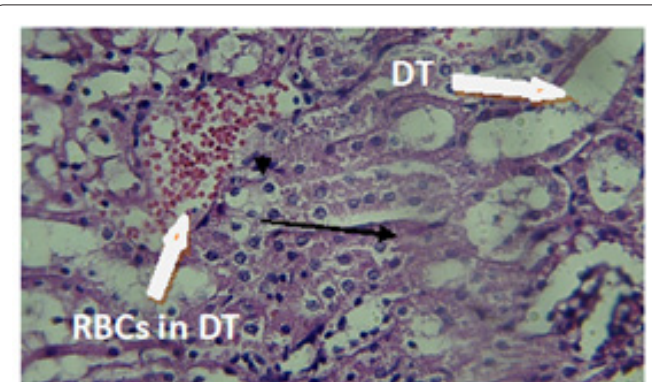


Figure 3. Paracetamol intoxicated group showing dilated tubules (DT) and red blood cells (RBCs) in DT as a sign of haemorrhage.

Photomicrographs of kidneys isolated from group III (PCM+40 mg/kg MEPH) exhibited distorted morphology as low dose treatment did not show any significant tissue

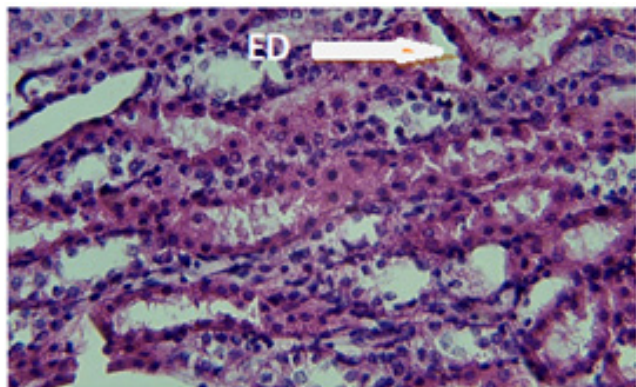


Figure 4. Low dose treated group showing tubules with oedema (ED).

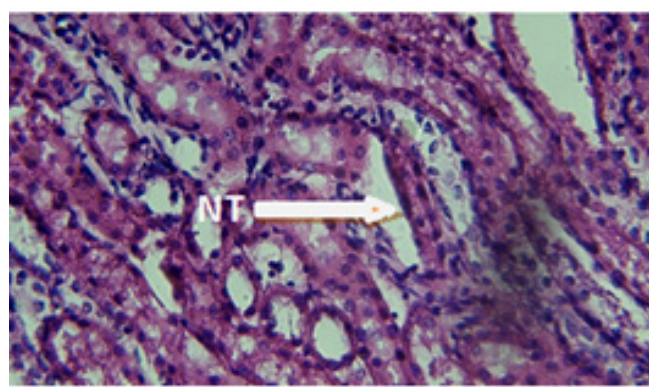


Figure 5. High dose treated group showed normal tubules.

repair. The slight repair was investigated. Still, oedema in tubules and haemorrhages were seen in various sections of this group (Figure 4).

Photomicrographs of kidneys isolated from group III (PCM+80 mg/kg MEPH) exhibited morphology very close to the control group with normal glomeruli and tubule, suggesting that a high dose is curative (Figure 6).

However, photomicrographs of kidneys isolated from group IV (PCM+5 ml/kg Cystone) slight disorganization of glomeruli and dilatation of tubules and Hemorrhages, showing that Cystone does not repairs the tissue it just helps to bring renal markers back to normal (Figure 7 & 8).

Nephrotoxicity is a toxic outcome of various substances, such as noxious chemicals and drugs, on the kidney (34). The current study aimed to investigate the reno-curative properties of *P. hysterophorus* in paracetamol-induced nephrotoxic rabbits. The acute toxicity of *P. hysterophorus* was not observed with 40 mg/kg & 80 mg/kg in Rabbits. However, enhanced dose, i.e., 120 mg/kg caused symptoms such as animal inactivity and anorexia. Paracetamol is commonly used as a curative in pain and fever with a prescribed dose. Its prescribed dose is safe; however, overdose can cause damage to the liver and kidneys and even kidney failure. Paracetamol toxicity leads to tubular atrophy of nephrons. The building up of Paracetamol within kidneys may initiate a metabolic chain of biochemical reactions, which can lead to acute nephropathy (35). Moreover, Paracetamol generates reactive oxygen species, which increases the process of lipid peroxidation resulting in renal injury (36). Nephrotoxicity was induced in male rabbits using paracetamol to avail structural and functional models for the investigation of nephron-curative agents. The paracetamol-induced nephrotoxic rabbits had a two to three-fold increase in urea and creatinine levels, i.e., (60 mg/dl) and (3.46 mg/dl), respectively, compared to the normal control rabbits due to decreased glomerular filtration rate. The observation that methanolic extracts of the whole plant of *P. hysterophorus* at different doses lowered urea and creatinine levels indicates that MEPH has reno-curative constituents.

In this study, paracetamol, the intoxicated group exhibited enormous histological changes in kidney tissue such as destroyed, dilated, atrophic tubules consisting of haemorrhage. Glomeruli were disorganized and sclerosed. In some sections, dilation of tubules and apoptotic figures and red blood cells in tubules were investigated. Treatment with MEPH lessened such devastating changes in kidney histology induced by Paracetamol. The histology of the

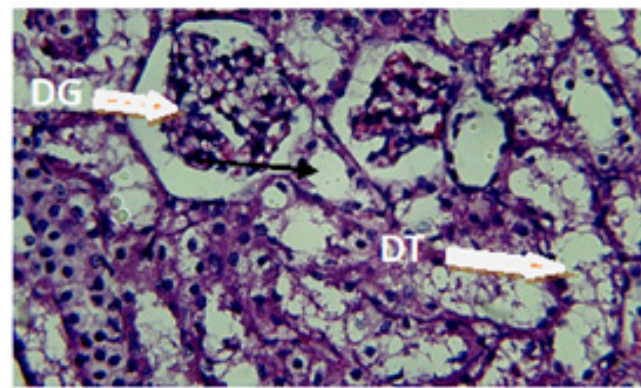


Figure 6. Cystone treated group showing slight disorganization of glomeruli (DG) and dilatation of tubules (DT).

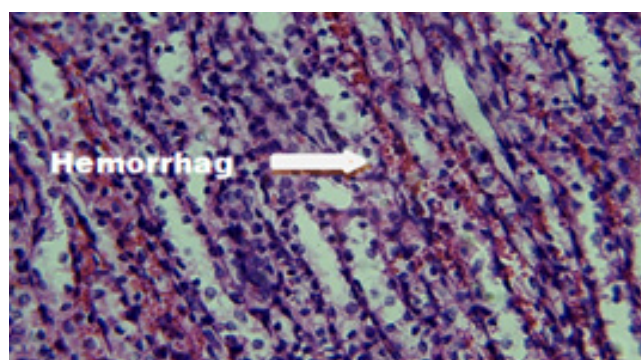


Figure 7. Cystone treated group showing renal haemorrhages.

40 mg/kg MEPH treated group showed nominal repair of damaged tissue compared to the intoxicated control group. The 80 mg/kg MEPH treated group exhibited almost normal glomerulus and tubules compared to the control group. Cystone treated group exhibited disorganization of glomeruli and dilation of tubules (as it is a reno-protective drug).

According to previous studies, the whole plant of *P. hysterophorus* exhibited antimicrobial, anti-anemic, antipyretic, anticancer, antioxidant, lipo-protective, antioxidant, hypoglycemic, hepatoprotective and anti-cancer potential (25, 26). *P. hysterophorus* also cured fever, malaria, diarrhea, dysentery, and neurologic disorders. *P. hysterophorus* was reported to have flavonoids, glycosides, alkaloids, tannins, and phenols that may be responsible for antioxidant and tissue protecting activity.

From histopathological studies, we conclude that methanolic extract of *P. hysterophorus* at the dose of 40 mg/kg has a partial curative effect whereas at the dose of 80

mg/kg has a complete curative effect on paracetamol-induced nephrotoxicity in rabbits.

Interest conflict

No conflict of interest to declare.

Consent for publications

The author read and proved the final manuscript for publication.

Availability of data and material

All data generated during this study are included in this published article

Authors' Contribution

All authors had an equal role in study design, work, statistical analysis and manuscript writing.

Funding

Nil

Ethics approval and consent to participate

The study protocol was approved by the Ethics Committee of the Virtual University of Pakistan, Ref. No. ECS.2020/17.

References

- Singh N, Mani TT. Review on nephroprotective activity of some medicinal plants. *Pharmacol Online* 2011; 3:1273-1289.
- Galley HF. Can acute renal failure be prevented? *J R Coll Surg Edinb* 2000; 45(1): 1204-1270.
- Cockcroft DW, Gault MH. Prediction of Creatinine Clearance from Serum Creatinine. *Nephron* 1976; 16: 31-41.
- Kleinman JG, Breitenfeldt RV, Roth DA. Acute renal failure associated with acetaminophen ingestion: report of a case and review of the literature. *Clin Nephrol* 1980; 14(4): 201-205.
- Zed PJ, Krenzelok EP. Treatment of acetaminophen overdose. *Am J Health Syst Pharm* 1999; 56: 1081-1089.
- Prescott LF. Paracetamol overdosage. *Drugs* 1983; 25(3): 290-314.
- Dahlin DC, Miwa GT, Lu AY, Nelson SD. N-acetyl-p-benzoquinone imine: a cytochrome P-450-mediated oxidation product of acetaminophen. *Proc Natl Acad Sci* 1984; 81(5): 1327-1331.
- Waring WS. Novel acetylcysteine regimens for treatment of paracetamol overdose. *Ther Adv Drug Saf* 2012; 3(6): 305-315.
- Bessemers JG, Vermeulen NP. Paracetamol (acetaminophen)-induced toxicity: molecular and biochemical mechanisms, analogues and protective approaches. *Crit Rev Toxicol*, 2001; 31(1): 55-138.
- Ghosh J, Das J, Manna P, Sil PC. Acetaminophen induced renal injury via oxidative stress and TNF- α production: therapeutic potential of arjunolic acid. *Toxicol* 2010; 268(1-2): 8-18.
- Kheradpezhoh E, Panjehshahin MR, Miri R, et al. Curcumin protects rats against acetaminophen-induced hepatorenal damages and shows synergistic activity with N-acetyl cysteine. *Eur J Pharmacol* 2010; 628(1-3): 274-281.
- Blantz RC. Acetaminophen: acute and chronic effects on renal function. *Am J Kidney Dis* 1996; 28(1): S3-S6.
- Trumper L, Girardi G, Elías MM. Acetaminophen nephrotoxicity in male Wistar rats. *Arch Toxicol* 1992; 66(2): 107-111.
- Li C, Liu J, Saavedra JE, Keefer LK, Waalkes MP. The nitric oxide donor, V-PYRRO/NO, protects against acetaminophen-induced nephrotoxicity in mice. *Toxicol* 2003; 189(3): 173-180.
- Islam R, Alam AH, Rahman BM, et al. Toxicological studies of two compounds isolated from *Loranthus globosus* Roxb. *Pak J Biol Sci* 2007; 10(12): 2073-2077.
- SujiArivazhagan JJ, Vimalastalin R. Nephroprotective activity of *Aristolochia indica* leaf extract against gentamicin induced renal dysfunction. *Inter J Res Biochem Biophys* 2014; 4: 13-18.
- Oudhia P, Tripathi RS, Choubey NK, Banwari L. *Parthenium hysterophorus*: a curse for the bio-diversity of Chhattisgarh plains of MP. *Crop Research (Hisar)* 2000; 19(2): 221-224.
- Bridgemohan P, Singh K, Lewis R. Biology and Management of Invasive Terrestrial Weed Species of Trinidad. Biology and management of invasive terrestrial weed species of Trinidad. The University of Trinidad and Tobago Carapichaima Trinidad and Tobago 2015.
- Das B, Das R. Chemical investigation in *Parthenium hysterophorus* L.-an allelopathic plant. *Allelopathy J* 1995; 2: 99-104.
- Kumar S, Mishra A, Pandey AK. Antioxidant mediated protective effect of *Parthenium hysterophorus* against oxidative damage using in vitro models. *BMC Complement Altern Med* 2013; 13(1): 120.
- Muhammad B, Khan R, Arshad Y, Khan RA. Phytochemical and cytotoxic analysis of *Parthenium hysterophorus* selected from District Bannu, Pakistan. *Afr J Biotechnol* 2012; 11(55): 11857-11860.
- Sinha SN, Paul D. Antioxidant potentials of *Parthenium hysterophorus* L leaf extracts. *Sci Res J India* 2014; 3(2): 80-86.
- Gurib-Fakim A, Sewraj MD, Gueho J, Dulloo E. Medicinal plants of Rodrigues. *Int J Pharmacogn*, 1996; 34(1): 2-14.
- Maishi AI, Ali PS, Chaghtai SA, Khan G. A proving of *Parthenium hysterophorus*, L. *Br Homeopath J* 1998; 87(1): 17-21.
- Patel VS, Chitra V, Prasanna PL, Krishnaraju V. Hypoglycemic effect of aqueous extract of *Parthenium hysterophorus* L. in normal and alloxan induced diabetic rats. *Indian J Pharmacol* 2008; 40(4): 183.
- Saleem M, Naureen H, Khan A, et al. Protective effect of *Parthenium hysterophorus* against carbon tetrachloride-and paracetamol- induced hepatotoxicity in rabbits. *Trop J Pharm Res* 2018; 17(3): 467-473.
- Mallhi TH, Abbas K, Ali M, Qadir MI, Saleem M, Khan YH. Hepatoprotective activity of methanolic extract of *Malvaparvi* flora against paracetamol-induced hepatotoxicity in mice. *Bangladesh J Pharmacol* 2014; 9(3): 42-34.
- Wadood A, Wadood N, Shah SA. Effects of *Acacia arabica* and *Caralluma edulis* on blood glucose levels of normal and alloxan diabetic rabbits. *J Pak Med Assoc* 1989; 39(8): 208-212.
- Priyadarsini G, Kumar A, Anbu J, Ashwini A, Ayyasamy S. Nephroprotective activity of decoction of *Indigoferatinctoria* (avurikudineer) against cisplatin-induced nephropathy in rats. *Inter J Life Sci Pharm Res* 2012; 2(4): 56-62.
- Shelke TT, Kothai R, Adkar P, et al. Nephroprotective activity of ethanolic extract of dried fruits of *Petalium murex* Linn. *J Cell Tissue Res* 2009; 9(1): 1687.
- Sakhaee, K., Adams-Huet, B., Moe, O. W., & Pak, C. Y. (2002). Pathophysiologic basis for normouricosuric uric acid nephrolithiasis. *Kidney international*, 62(3), 971-979.
- Salih NA. Effect of nettle (*Urtica dioica*) extract on gentamicin induced nephrotoxicity in male rabbits. *Asian Pac J Trop Biomed* 2015; 5(9): 756-760.
- Spitalnik PF, Witkin JW. 2016. Histology laboratory manual. College of Physicians and Surgeons, 2016.
- Pydi R, Rajalakshmi I, Indumathy S, Kavimani S. Nephroprotective medicinal plants-A review. *Int J Univ Pharm Life Sci* 2011; 1: 266-281.
- Yousef MI, Omar SA, El-Guendi MI, Abdelmegid LA. Potential protective effects of quercetin and curcumin on paracetamol-induced histological changes, oxidative stress, impaired liver and

kidney functions and haematotoxicity in rat. *Food Chem Toxicol* 2010; 48 (11): 3246-3261

of advanced oxidation protein products in regulation of dendritic cell function. *Free Radic Biol Med* 2002; 32(5): 377-385.

36. Alderman C J, Shah S, Foreman JC, Chain BM., Katz DR. The role